

Unique Location of the Chest Wall Hydatid Cyst: A Case Report

Sameer A. Mohialdeen *FRCS, FICS, FACS, FCCP*

Dept. of Surgery, College of Medicine, Al-Nahrain University, Baghdad, Iraq

Abstract

The chest wall hydatidosis is a rare location of primary hydatid cyst. This is a 29-old female, multipara presented with a right anterior chest wall painless swelling below the clavicle deep to the pectoralis major muscle). Investigations confirm that this is a chest wall cystic lesion most likely hydatid cyst and it is the only one, no other organ involved. Patient prepared for surgery, the cyst completely removed successfully under general anesthesia and the histological examination confirm a hydatid cyst of the chest wall).

Keywords Chest wall cyst, hydatid cyst.

Citation Mohialdeen SA. Unique location of the chest wall hydatid cyst: A case report. *Iraqi JMS*. 2024; 22(2): 422-426. doi: 10.22578/IJMS.22.2.27

List of abbreviations: None

Introduction

Human Echinococcus, a common cause of cystic lesions in human beings. It is a parasitic infestation caused by the larval forms of small tapeworm of genus Echinococcus, from the family of Taeniidae parasites. Human hydatidosis is a (zoonotic disease) that transmitted to the human from animals. Two main forms are *Echinococcus granulosus*, and to less extent *Echinococcus alveolaris* ⁽¹⁾.

Hydatid disease is endemic in many parts of the world in Middle East, Eastern and Southern Europe, North Africa, and South America ⁽²⁾.

Hydatid disease most commonly affected liver and lung or both is about (85%) ⁽³⁾. Liver (60%) and lung (20-30%), Chest wall (0.9%) ⁽⁴⁾. Chest wall is a rare as primary site of infection of hydatid cyst ^(5,6).

Early detection and appropriate management of hydatid cysts in unusual locations are crucial to prevent complications. Treatment often involves surgical removal of the cysts, sometimes accompanied by antiparasitic medication to reduce the risk of recurrence.

For healthcare professionals, this case underscores the need to consider hydatid disease in the differential diagnosis when encountering cystic lesions in uncommon anatomical sites, especially in patients from endemic regions or with relevant exposure histories.

Case presentation

A 29-year-old female, multipara lives in urban area, no pets indoor, she complained from a swelling at the right upper anterior chest wall below the clavicle noticed 2 months ago.

Clinical examination revealed a lump, spongy, smooth deep under the chest wall muscle (pectoralis major).

Chest X-rays (Figure 1) showed clear no pathological finding. Chest ultrasound (Figure 2) revealed a cystic mass (4.42x2.98 cm). Normal abdominal ultrasound, non-notable any similar pathology elsewhere.

Booked for elective surgery in cardiothoracic department, under general anesthesia exploration done; a cystic mass (hydatid cyst)

primary simple cyst between the muscle fibers of right pectoralis major (Figure 3), cystectomy done after injection scoilicidal agent (20% hypertonic saline).

The patient recovered uneventfully (Figure 4). The wound was clean.

In endemic areas we should consider any cystic mass in any part of the body may be hydatid cyst because the hydatid cyst can occur in any place of the body except the hair and the nail.

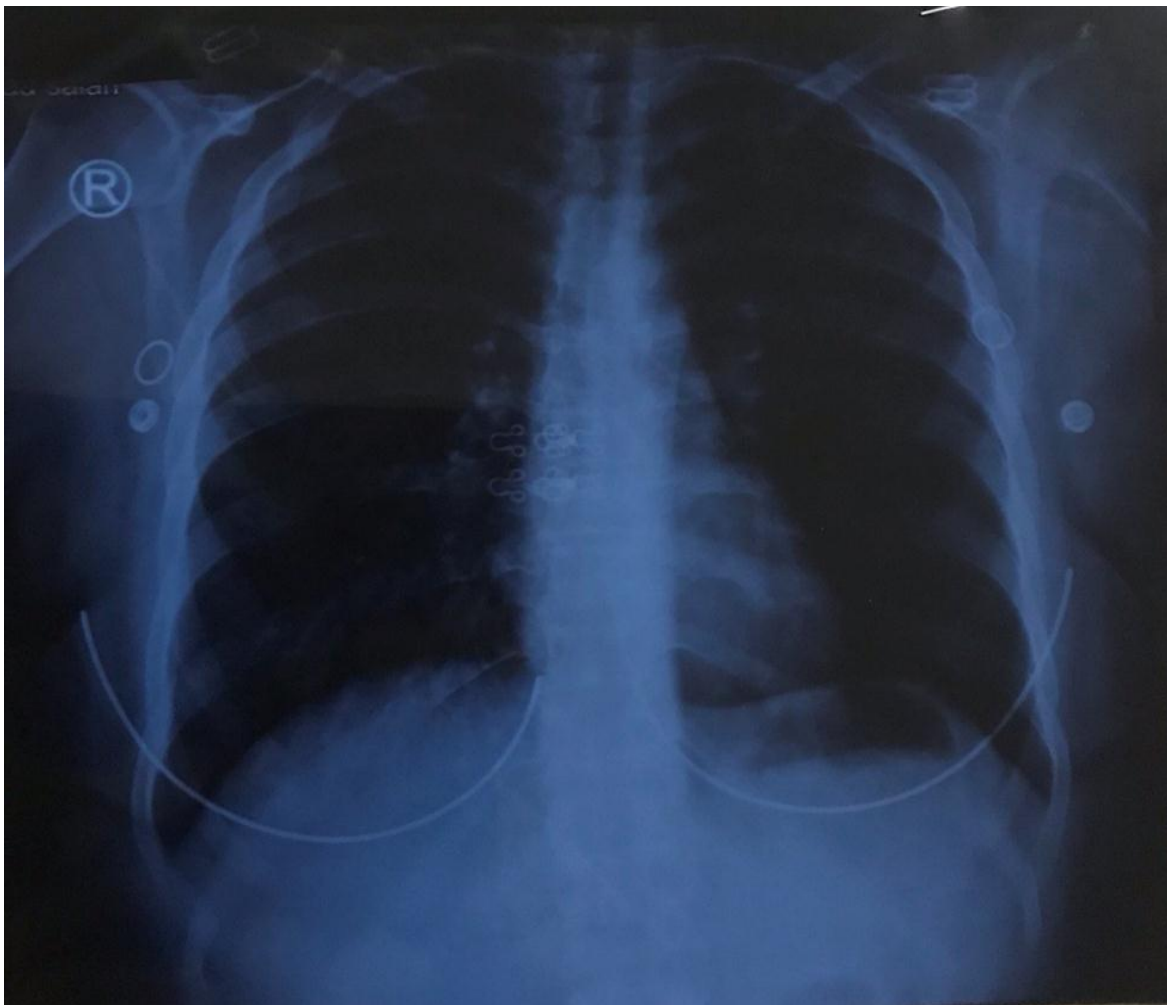


Figure 1. Clear chest X-ray

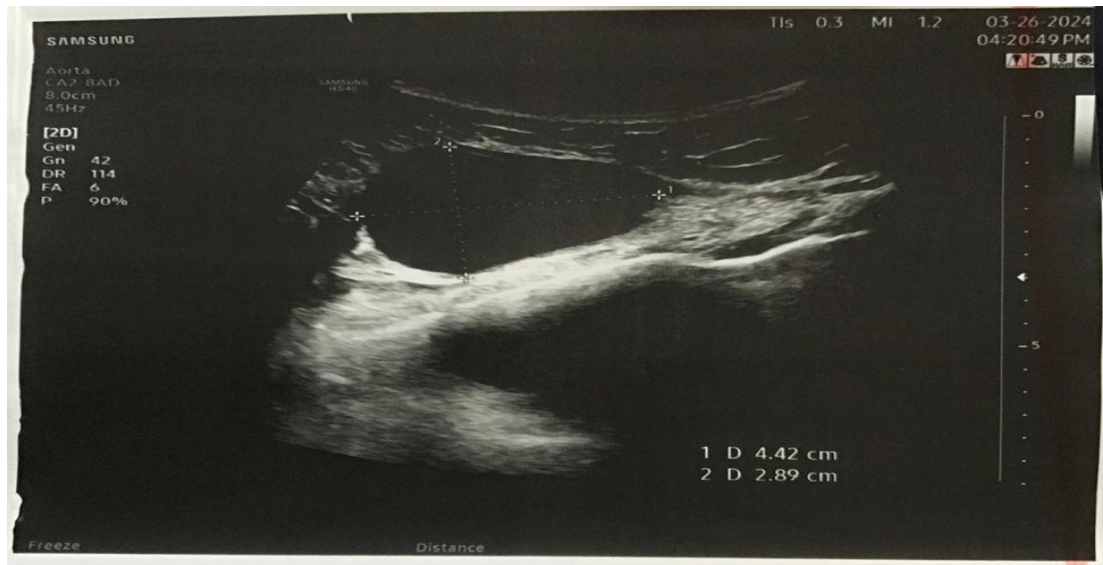

Figure 2. Ultrasound of the chest wall well defined unilocular cyst within muscle below right clavicle

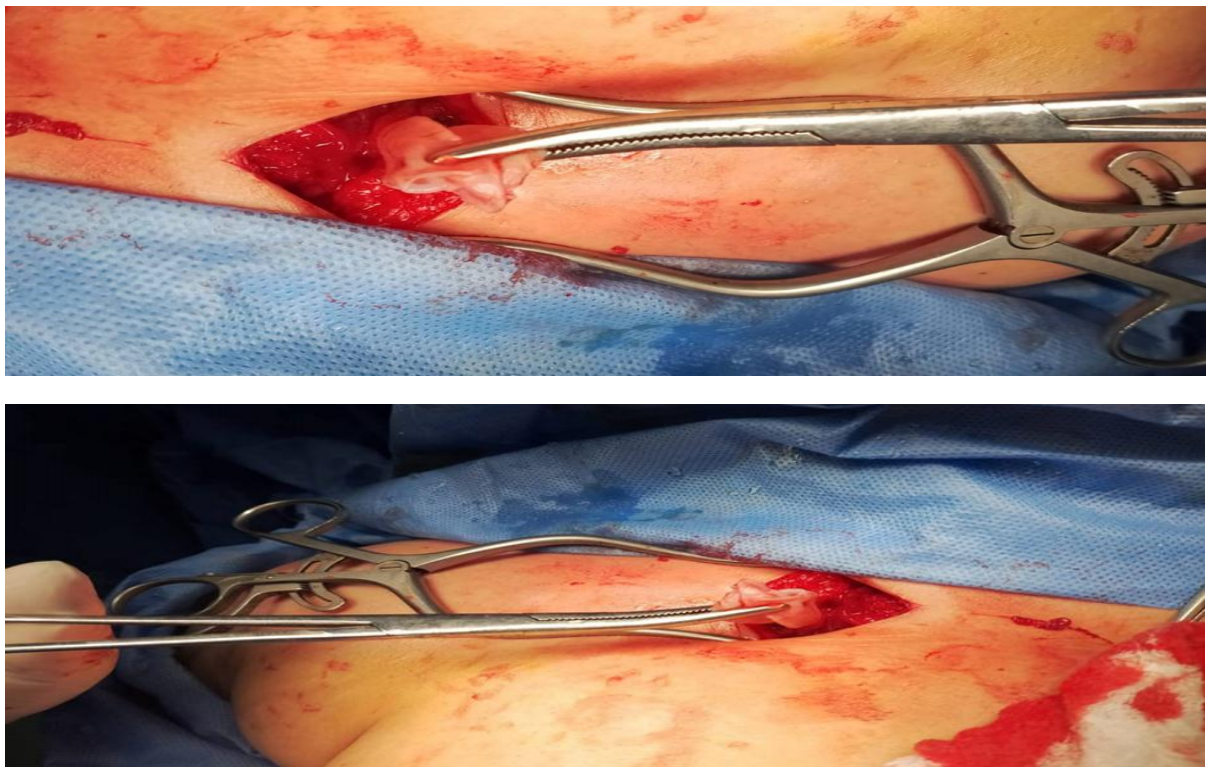


Figure 3. Surgical cystectomy (Hydatid Cyst) of the chest wall

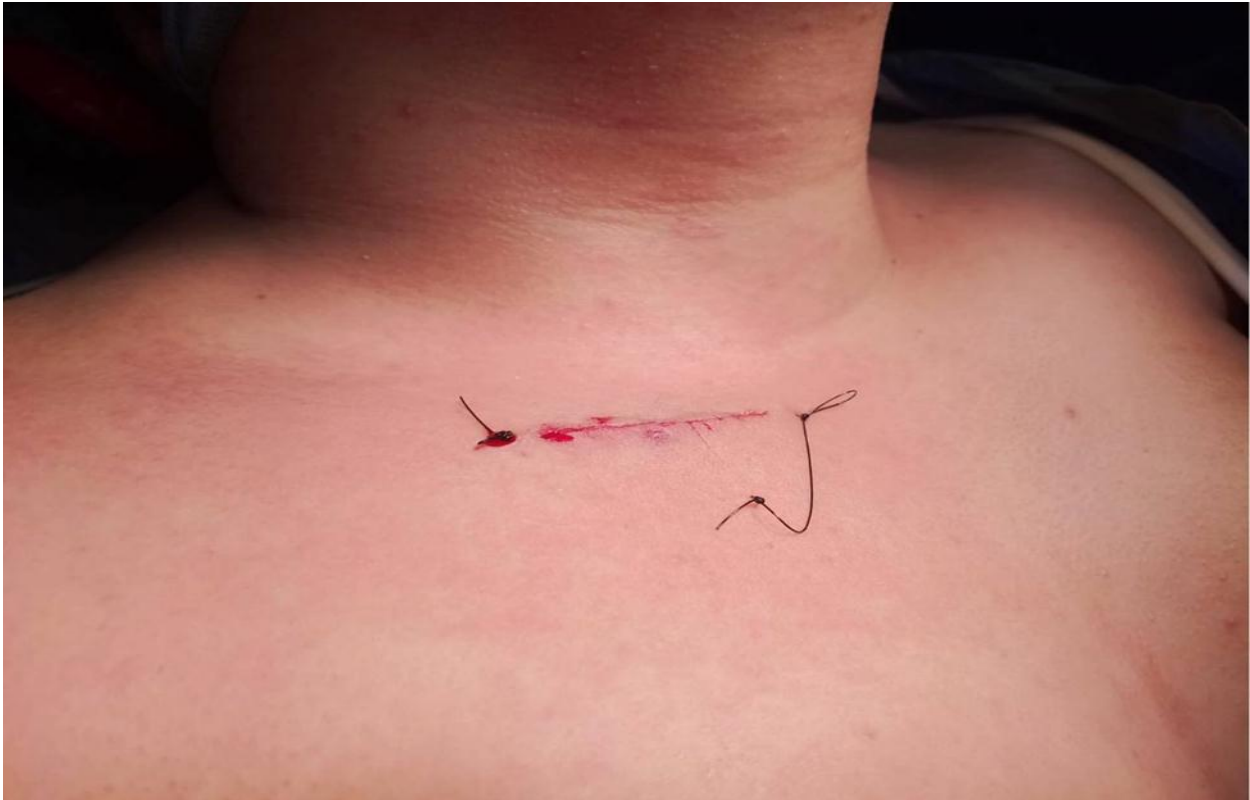

Figure 4. Surgical incision in upper right chest wall

Discussion

Chest wall hydatid cyst as primary site for hydatid cyst is rare, few cases were reported even in endemic area ⁽⁷⁾.

Hydatid cyst must be considered in the differential diagnosis of the chest wall masses when dealing with chest wall tumors even without apparent risk factors. Appropriate treatment of the primary chest wall hydatid cyst is a surgical excision.

Hematological spread of the small size embryo through duodenal wall into either portal vein or peri duodenal and epigastric lymphatic system these lymphatic channels connected with thoraco-mediastinal lymphatic and thoracic duct ⁽⁸⁾.

The mass is in the fibers of the pectoralis major spongy, not associated with lymphadenopathy, all going with benign pathology, similar to the lipoma. In 50% of reported cases the patient had never been operated for hydatid cyst elsewhere ⁽⁹⁾. In the reported case, the patient was followed for nine months without being seen any similar pathology elsewhere. The hydatid

cysts are seen in many different structures like in the axillary region and in the muscles of the thigh ^(10,11).

In conclusion, a cystic mass located in the chest wall may considered a hydatid cyst even that localization in the chest wall is a rare, especially in our country is endemic area for hydatidosis disease.

Acknowledgement

The author thanks the staff of the cardio thoracic department in Al Ima men medical city and the staff of the operative theater.

References

1. Petersen C, Mills J. Parasitic infections. In: Murray JF, Nadel JA (eds). Textbook of respiratory medicine. Philadelphia: WB Saunders Company; 1994. p. 1201-43.
2. Doğan R, Yüksel M, Cetin G, et al. Surgical treatment of hydatid cysts of the lung: report on 1055 patients. Thorax. 1989; 44(3): 192-9. doi: 10.1136/thx.44.3.192.
3. Tomos P, Kakaris S, Lachanas E, et al. Secondary echinococcosis of the rib and soft tissues. Respiration. 2005; 72(5): 542. doi: 10.1159/000087681.

Mohialdeen, *Unique Location of the Chest Wall Hydatid Cyst: A Case Report*

4. D'Alessandro A, Ramirez LE, Chapadeiro E, et al. Second recorded case of human infection by *Echinococcus oligarthrus*. *Am J Trop Med Hyg.* 1995; 52(1): 29-33. doi: 10.4269/ajtmh.1995.52.29.
5. Ozdemir N, Akal M, Kutlay H, et al. Chest wall echinococcosis. *Chest.* 1994; 105(4): 1277-9. doi: 10.1378/chest.105.4.1277.
6. Oğuzkaya F, Akçali Y, Kahraman C, et al. Unusually located hydatid cysts: intrathoracic but extrapulmonary. *Ann Thorac Surg.* 1997; 64(2): 334-7. doi: 10.1016/S0003-4975(97)00521-3.
7. Salih AM, Ahmed DM, Kakamad FH, et al. Primary chest wall Hydatid cyst: Review of literature with report of a new case. *Int J Surg Case Rep.* 2017; 41: 404-6. doi: 10.1016/j.ijscr.2017.10.051.
8. Sarsam A. Surgery of pulmonary hydatid cysts. Review of 155 cases. *J Thorac Cardiovasc Surg.* 1971; 62(4): 663-8. PMID: 5093823.
9. Findikcioglu A, Kilic D, Canpolat T, et al. Primary hydatid disease of the chest wall. *Ann Thorac Cardiovasc Surg.* 2007; 13(3): 203-5.
10. Getie A, Atinafu B, Alemu M, et al. Intermuscular hydatid cyst in the thigh musculature: A case report. *J Med Case Rep.* 2024; 18(1): 627. doi: 10.1186/s13256-024-04861-0.
11. Christina J, Chatterjee S, Bera P, et al. Primary axillary hydatid cyst: A case report. *J Med Case Rep.* 2024; 18(1): 484. doi: 10.1186/s13256-024-04830-7.

E-mail: samir_fracs@nahrainuniv.edu.iq

Samir_fracs@yahoo.com

Received Sep. 9th 2024

Accepted Dec. 29th 2024