

Outcome of Orbital Complications of Acute Rhinosinusitis in Children

Jafer M.K. Al-Hassani *FICMS*

¹Dept of Surgery, College of Medicine, Al-Nahrain University, Baghdad, Iraq

Abstract

- Background** Acute bacterial rhinosinusitis occurs commonly as a sequel to a viral upper respiratory tract infection. Spread of infection outside the sinuses to the surrounding brain and orbit results in complicated sinusitis. Complications are more common in children than adults due to anatomical and immunological factors.
- Objective** To identify the correlation of orbital manifestations with computed tomography (CT) scan findings in diagnosing and classifying the disease, the efficacy of various treatment modalities and the outcome of these complications in children.
- Methods** A prospective study of 16 patients who presented with orbital swelling and features of acute rhinosinusitis was conducted in the Otorhinolaryngology Department at Al-Imamein Al-Kadhimein Medical City from April 2014 to October 2015. A full history, ear, nose and throat (ENT) examination including naso-endoscopic examination (if possible), ophthalmological assessment and CT scan of nose and paranasal sinuses were done. Patients were classified to have either pre-or postseptal infection depending on CT findings. All patients were admitted to the ENT ward, received intravenous broad-spectrum antibiotics and supportive measures and kept under close observation with monitoring of ophthalmological manifestations and vital signs. Some patients responded to medical treatment and others required surgical intervention. All patients after recovery were discharged home on oral antibiotics for 2 weeks and followed up monthly for a total duration of 3 months.
- Results** The majority of patients were males (62.5%). Mean ages of patients was 8.9 ± 2.9 years with a range (4 to 15) year. Preseptal cellulitis was more common (62.5% vs. 37.5%). Impaired visual acuity, impaired extraocular movement and proptosis were significantly associated with postseptal infections as the P values were 0.01, 0.003 and 0.003 respectively. Preseptal cellulitis responded well to medical treatment. Postseptal abscesses required surgical drainage using an external, endoscopic or combined approach. 94% of patients had complete recovery without any sequel.
- Conclusion** Orbital manifestations are strongly correlated with CT findings. Medical treatment is very effective for preseptal infection. The choice of surgical approach for managing postseptal infection will depend upon, the site and extension of the abscess and the state of the nasal cavity. Early and accurate management can reduce morbidity and mortality.
- Keywords** Orbital complications of sinusitis, pediatric rhinosinusitis, ethmoiditis
- Citation** Al-Hassani JMK. outcome of orbital complications of acute rhinosinusitis in children. *Iraqi JMS*. 2021; 19(1): 90-98. doi: 10.22578/IJMS.19.1.12

List of abbreviations: None

Introduction

Acute bacterial rhinosinusitis occurs commonly as a sequel of a viral upper respiratory tract infection. The spread of infection outside the sinuses results in

complicated sinusitis ⁽¹⁾. Complications of paranasal sinus disease are more common in children than adults. The spread of infection from the nose and paranasal cavities to the surrounding brain and orbit is facilitated in children by dehiscence in the common bony walls at the suture lines, the thinness of the cranial bones and the relative immunosuppression of the child under the age of five ⁽²⁾. The proximity of the orbit to the paranasal sinuses especially the ethmoid sinuses and paper-thin medial wall of the orbit, namely lamina papyracea, make it the most commonly involved structure in the complications of sinusitis. The orbital septum, a reflection of the orbital periosteum, is an important structure because it is the only soft tissue barrier between the sinuses and the orbital contents. Orbital infections are divided into two groups based on this element of orbital anatomy; preseptal and postseptal infections ⁽¹⁾. Chandler et al. classified the orbital complications of sinusitis into five groups: preseptal cellulitis, orbital cellulitis, subperiosteal abscess, orbital abscess and cavernous sinus thrombosis. The first complication, preseptal cellulitis is a preseptal infection and the latter four are postseptal ⁽³⁾. The difficulty for the clinician lies in distinguishing preseptal cellulitis from subperiosteal or orbital abscess at the initial presentation, with marked orbital edema and pain limiting the ophthalmic examination especially in children ⁽²⁾. Furthermore, progression of infection could happen during the course of treatment with development of new complications making the clinical assessment more difficult ⁽⁴⁾. Accordingly, imaging is often necessary to appropriately classify orbital complications. Computed tomography (CT) is considered the gold standard for sinus imaging. It has been shown to demonstrate good accuracy in diagnosing pediatric rhinosinusitis ^(5,6). In preseptal cellulitis, CT reveals a diffuse increase in density and thickening of the lid and conjunctiva. Postseptal inflammation is

characterized by a soft tissue density or low-attenuation area adjacent to the lamina papyracea ^(5,7). Abscesses appear as hypodense areas with rim enhancement and mass effect ⁽⁸⁾.

The aim of this study is to identify the correlation of orbital manifestations with CT scan findings in diagnosing and classifying the disease, the efficacy of various treatment modalities and the outcome of these complications in children.

Methods

Ethical considerations

Verbal consent was taken from each patient parent after explaining (by the researcher) the purpose of the study.

Study population

Sixteen selected patients with orbital swelling and features of acute rhinosinusitis were included in this study with the following criteria.

Inclusion criteria

1. Patient within pediatric age group.
2. Orbital swelling, eyelid edema and eyelid erythema.
3. Features of acute rhinosinusitis:
 - Facial congestion.
 - Nasal obstruction.
 - Nasal discharge/purulence/discolored.
 - Purulence on nasal examination.
 - Duration of symptoms of less than 4 weeks.
4. CT scan findings suggesting rhinosinusitis (presence of sinus opacification or air-fluid levels), with features of orbital involvement.

Exclusion criteria

1. Patient with documented ophthalmological problems (as a result of infection of the eyelids and orbital adnexa, trauma including insect bites or a foreign body, dacryocystitis, history of surgery, odontogenic infection, and orbital tumors).
2. Immunocompromised patients.

Study design

A prospective study was conducted in Otolaryngology Department at Al-Imamein Al-Kadhimein Medical City over a period of 18 months (Apr. 2014 - Oct. 2015). Direct questioning of patients and/or his/her parents about the biographic data, chief complaint and duration, associated symptoms, other medical or surgical history, drug history and any relevant socio-economic history was done. General clinical examination, full ear, nose and throat (ENT) and head and neck examinations were done. Apart from nasal examination, nasoendoscope (where possible) was done for majority of patients using 2.7 mm and 4.0 mm rod Hopkins rigid nasoendoscopes or flexible fiberoptic nasopharyngoscope according to the patient age and nasal cavity status. A formal assessment of the full range of eye movements, degree of proptosis, pupillary light reflex, visual acuity (using a Snellen chart), color vision (using Ishihara plates) and inspection of the optic disc (where possible) were carried out by an ophthalmologist at time of presentation. Radiological examination included CT scan (axial and coronal views) of nose and paranasal sinuses were done for all patients (as a part of our study to confirm the diagnosis, to classify the disease and then to correlate the clinical presentation with CT findings). All patients were admitted to the ENT ward for medical treatment and close observation including twice daily monitoring of the full range of eye movements, visual acuity and proptosis in conjunction with regular temperature monitoring and pulse measurement. All patients received intravenous (IV) broad spectrum antibiotics (third generation cephalosporin 50 mg/kg/day and metronidazole 30 mg/kg/day), topical nasal decongestants, analgesia and nasal irrigation. Some patients were subjected to surgical intervention in the form of endoscopic sinus surgery, external ethmoidectomy, or combined approach to drain the pus and release pressure on the orbit. All patients were kept on IV treatment until complete improvement, discharged home on oral

antibiotics for a total duration of 14 days, and followed up monthly for up to 3 months.

Statistical analysis

By using the statistical package for social sciences (SPSS) program version 20, data were entered and analyzed with appropriate statistical tests. Descriptive statistics were presented as frequencies, proportions, mean and standard deviation (SD). Paired t test was used to compare pre and post-operative mean VAS scores and Fisher's exact test was used to compare frequencies (proportions). Level of significance (P value) ≤ 0.05 considered as significant. Finally, all findings and results are presented in tables and/or figures with explanatory paragraphs accordingly.

Results

Ten patients were males and 6 were females (Fig. 1).

Patients ages ranged from 4-15 years, 8 (50%) of them were between 8-11 years and the mean age \pm SD was (8.9 \pm 2.9) years (Fig. 2).

Depending on CT scan findings, 10 patients were presented with preseptal and 6 with postseptal infection (Fig. 3).

Preseptal infection occurred more commonly in males and postseptal infection occurred in equal numbers in both genders (table 1).

Both types of complications occurred more commonly in patients over the age of 7 years (table 2).

Common orbital manifestations (Orbital swelling, eyelid edema and eyelid erythema) were observed in all patients, while specific features (impaired visual acuity, ophthalmoplagia and proptosis) were observed specifically as follows: for those with preseptal infection, 2 had visual acuity of 6/18, 1 had impaired extraocular movement, and no one had proptosis, while those with postseptal infection, 5 of them had visual acuity of 6/18 or worse, 5 had impaired extraocular movement, and 4 had proptosis and as shown in (table 3), these manifestations were significantly associated with postseptal infection as the P values were < 0.05 .

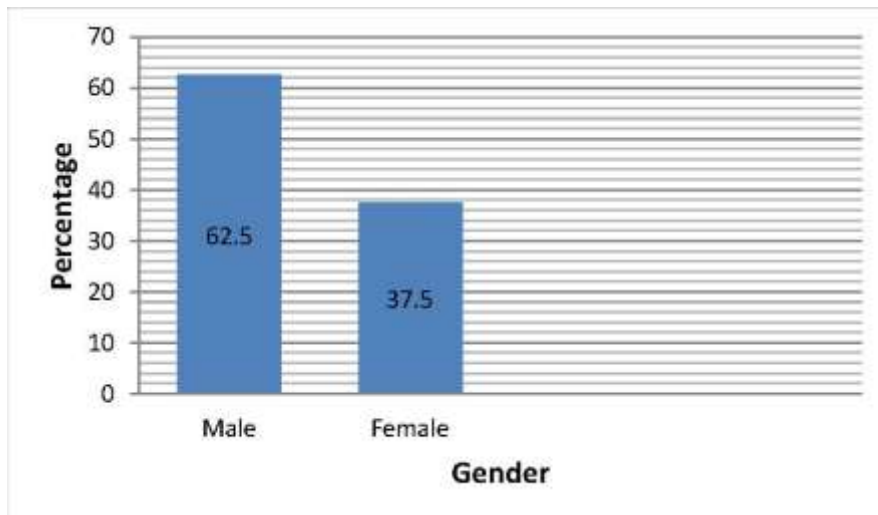


Figure 1. Gender distribution

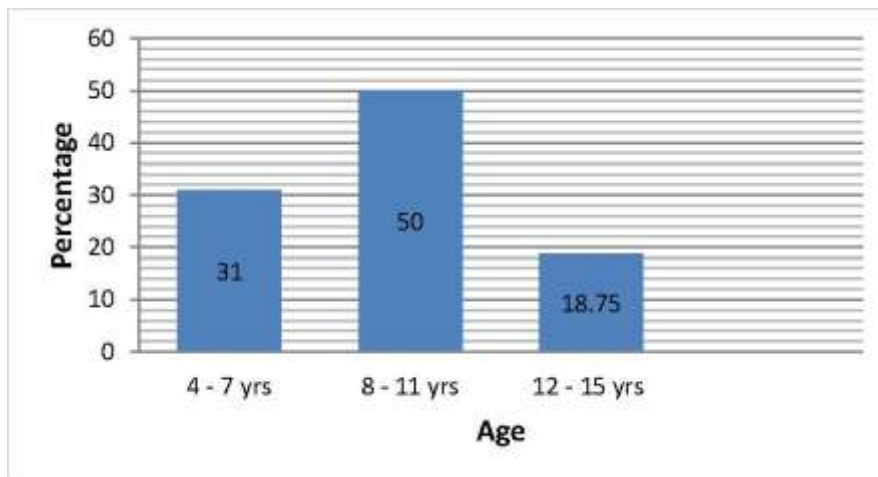


Figure 2. Age distribution

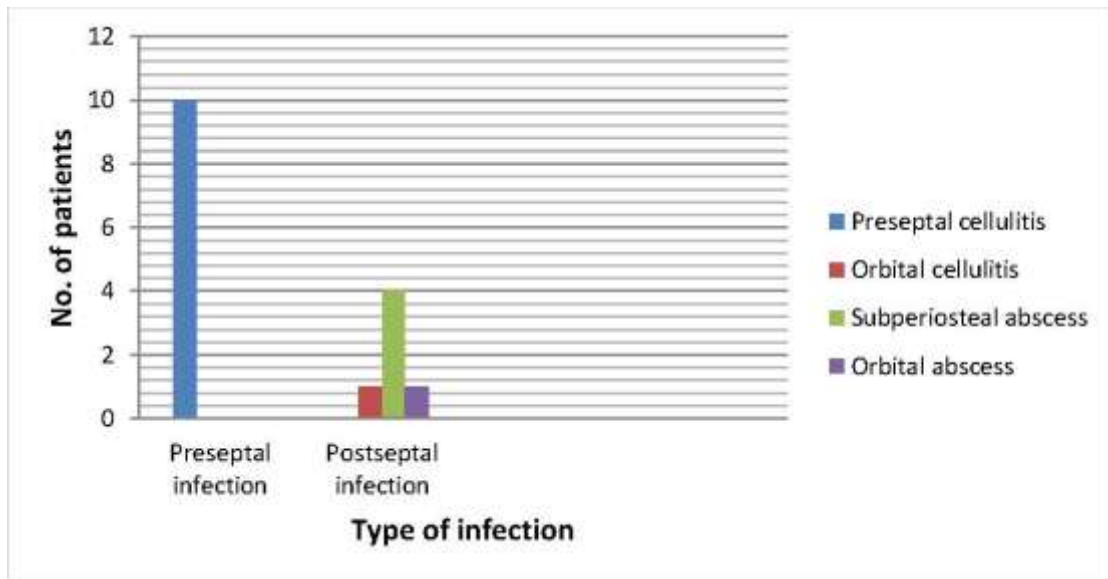


Figure 3. Types of orbital complications according to CT findings

Table 1. Gender of the patients and its relation to the type of orbital complication

Gender	No	%	Preseptal infection	Postseptal infection	P value
Males	10	62.5	7	3	0.4
Females	6	37.5	3	3	
Total	16	100	10	6	

Table 2. Age of the patients and its relation to the type of orbital complication

Age (yr) (mean±SD)	No	%	Preseptal infection	Postseptal infection	P value
≤7 (5.8±1.3)	5	31	4	1	0.3
>7 (10.2±2.2)	11	69	6	5	
Total	16	100	10	6	

Table 3. Orbital manifestations and their relation to the type of orbital complication

Orbital Features	Preseptal infection			Postseptal infection			P value
	No. of affected patients	No. of total patients	%	No. of affected patients	No. of total patients	%	
VA* 6/18 or Worse	2	10	20	5	6	83.3	0.01
Impaired EOM**	1	10	10	5	6	83.3	0.003
Proptosis	0	10	0	4	6	66.7	0.003

* Visual acuity, ** Extraocular movement

Eleven patients were subjected initially to medical treatment alone (those diagnosed with preseptal cellulitis and orbital cellulitis without abscess), 9 (82%) of them responded well to medical treatment, and the other 2 (18%) showed progression of signs and symptoms within 24 hours of close observation. Seven patients (those who had abscess formation and

those with outcome of orbital complications of acute RS in children 8 unimproved cellulitis and disease progression) required surgical intervention (Table 4). Six patients from the surgical group showed clinical improvement on surgical management and 1 patient (who had orbital abscess) developed blindness.

Table 4. Different surgical approaches required for management of orbital complications

Surgical Approach	Diagnosis				Total
	Preseptal cellulitis	Orbital Cellulitis	Subperiosteal abscess	Orbital abscess	
Endoscopic	1	1	1	---	3
External	---	---	1	---	1
Combined	---	---	2	1	3

Discussion

Orbital complications have been observed more commonly among males (62.5%). Although male involvement was predominant, gender was not considered as a risk factor for development of specific type of orbital complications as it was statistically not significant.

Nageswaran et al. ⁽⁹⁾, Huang et al. ⁽¹⁰⁾ and Sultész et al. ⁽¹¹⁾ also showed male predominance (73%, 65.63% and 54.8% respectively) without statistical significance. In a study done by Goytia et al. ⁽¹²⁾, the male gender has been identified as a risk factor in post-septal infections.

The mean age of presentation was 8.9 years. Both pre- and postseptal infections occurred more frequently in patients above the age of 7 years (69%), however, there was no statistical significance to consider the age as a risk factor predisposing to a certain type of orbital complications. In a study done by Smith et al. ⁽¹³⁾, the mean age was 6.5 years and age over 9 was considered as a risk factor for developing post-septal infection ($p < 0.01$). Huang et al. ⁽¹⁰⁾ found in their study that the mean age was 6.95 years and the age of 6 years or less as a risk factor for post-septal infection ($p = 0.023$). Botting et al. ⁽¹⁴⁾ obtained a statistically

significant difference between pre- and post-septal groups with regards to age (3.9 vs. 7.5 years, $p < 0.001$). From the previous discussion we could note that no specific pediatric age could be obtained as a risk factor for developing either pre- or post-septal orbital infections.

CT scan is considered the gold standard for sinus imaging because it can better depict the anatomy of the globe, retro-orbital tissues, sinuses, and cranium, and provides information for surgical planning. Huang et al. ⁽¹⁰⁾ have used CT scan in all patients in their study to prove the presence of concomitant sinusitis. Ho et al. ⁽¹⁵⁾ in a retrospective study of 80 patients with orbital cellulitis used CT scan to classify their patients. Clary et al. ⁽¹⁶⁾ in a retrospective review of 19 patients (with orbital complications who underwent surgical exploration within 24 hours of their CT scan) found that 15 of the 19 CT scan interpretations indicating the outcome of orbital complications of acute RS in children 9 abscesses that were verified intraoperatively, 2 patients had negative surgical exploration despite CT interpretations predicting abscesses, an abscess was also surgically documented in 1 of 2 patients whose preoperative scans indicated cellulitis alone. They concluded that the

correlation between radiologic and operative findings, although not absolute, does substantiate the use of CT scanning as a therapeutic guide in children presenting with orbital disease secondary to paranasal sinusitis. Despite these findings, the use of CT scan as a routine investigation in the management of pediatric complicated rhinosinusitis is not well documented, as it is not always necessary to expose them to a high dose of radiation especially those presented with mild orbital manifestation of pre-septal cellulitis, in addition, CT scan is not always available in all medical facilities and the nearest one may be far away from the local facility. Howe and Jones⁽¹⁷⁾ developed criteria for indication of CT of the sinuses and the orbit in the following situations: central neurological signs; inability to perform adequate ophthalmological examination; no improvement in orbital signs or general clinical condition after 24 hours of appropriate intravenous antibiotics and deterioration of orbital signs (proptosis, ophthalmoplegia, altered color vision, or visual acuity).

The most common type of orbital complications of rhinosinusitis was preseptal cellulitis (62.5%). Ozkurt et al.⁽¹⁸⁾, Sobol et al.⁽¹⁹⁾ and Ailal. et al.⁽²⁰⁾ also found that pre-septal cellulitis was the commonest orbital complication and the percentages were 62.3%, 72% and 73% respectively. The fact beyond this result is that orbital septum lacks lymphatic channels and thus, forms a barrier limiting infections from passing directly through the eyelids into the orbit⁽¹⁾. Specific orbital manifestations including impaired visual acuity, impaired extraocular movement and proptosis were significantly associated with postseptal infections. Ho et al.⁽¹⁵⁾ found that patients with postseptal involvement had a significantly higher rate of proptosis and limited extraocular motility. Sobol et al.⁽¹⁹⁾ concluded that postseptal complications of sinusitis can be diagnosed by the presence of ophthalmoplegia and proptosis. Botting et al.⁽¹⁴⁾ found that ophthalmological examination identified diplopia ($P < 0.001$), ophthalmoplegia ($P < 0.001$), and proptosis ($P < 0.001$) as significant features of a postseptal infection. These

features developed mostly due to abscess collection at the medial aspect of the orbit between orbital periosteum and lamina papyracea (subperiosteal abscess) that displaces the orbital contents and globe downward and laterally with impaired ocular mobility, or collection of abscess within the orbital tissues (orbital abscess) displacing orbital contents forward with resultant severe exophthalmos, complete ophthalmoplegia and visual impairment due to pressure effect on optic nerve with a risk for progression to irreversible blindness⁽⁵⁾. The great majority (90 percent) of pre-septal cellulitis were successfully and effectively managed by medical treatment alone. Sobol et al.⁽¹⁹⁾ and Moubayed et al.⁽²¹⁾ also found that preseptal disease was resolved with antibiotics. In our study, 1 patient with preseptal cellulitis and another 1 with orbital cellulitis showed progression of signs and symptoms within 24 hours and required surgical intervention. Ho et al.⁽¹⁵⁾ found that 2 out of 34 patients with outcome of orbital complications of acute RS in children, 10 preseptal cellulitis and 3 out of 6 patients with orbital cellulitis required surgical intervention for management of their orbital infection.

All patients in our study, who presented with abscess collection and those with cellulitis who failed to respond to medical treatment, required surgical intervention. In general, surgical intervention has been recommended in cases when there is CT evidence of abscess formation, 20/60 or worse visual acuity is observed on initial evaluation, progression of orbital signs and symptoms occurs despite medical treatment, or lack of improvement is seen within 48 hours despite aggressive medical treatment⁽¹⁾. There are 3 surgical approaches that were used for treating these complications: external ethmoidectomy, endoscopic sinus surgery and combined surgical approach. The location of the abscess will dictate if an endoscopic approach is feasible. Orbital cellulitis is mainly secondary to ethmoid rhinosinusitis, the position of any abscess is likely to be medial to the globe. Some surgeons suggest that endoscopic ethmoidectomy together with removal of the

lamina papyracea and perinasal drainage of the orbital abscess is sufficient treatment. Endoscopic drainage avoids external scars and results in rapid resolution of periorbital inflammation⁽²²⁾. Migirov et al.⁽²³⁾ found that there were no postoperative sequelae in children treated endoscopically, in contrast to facial scarring, delayed healing, stitch abscess, unresolved diplopia, or recurrent periorbital cellulitis with or without abscess following external drainage. They recommended exclusive use of an endoscopic approach for treating medial orbital subperiosteal abscess and saving external ethmoidectomy for drainage of superior orbital abscesses. However, the anatomical limits of the pediatric nose and the vascular mucosa make it technically difficult and unless the surgeon is extremely familiar with endoscopic nasal surgery, it is probably easier and wiser to use an external approach⁽²⁴⁾. Using both external and endoscopic techniques in the management of subperiosteal and orbital abscess has been shown to achieve the best results regarding the adequacy of abscess drainage and surgical access and minimizing the possibility of iatrogenic complications.

Rubin et al.⁽²⁵⁾ found that the percentage of surgical failures requiring additional drainage was 25% in endoscopic approach and 14% in external approach but this difference was not significant, there were no failures in the combined approach group. They concluded that combined approach seems to be a viable surgical option combining the advantages of both endoscopic and external approaches. Dewan et al.⁽²⁶⁾ concluded that combined approach was associated with improved treatment outcome, demonstrated by absence of abscess re-accumulation compared with the other 2 approaches.

With early and adequate management, the prognosis of orbital complications of rhinosinusitis is usually good. Same findings were obtained by Sultész et al.⁽¹¹⁾, Ho et al.⁽¹⁵⁾ and Moubayed et al.⁽²¹⁾.

In conclusions, orbital manifestations are strongly correlated with CT findings in distinguishing between pre- and postseptal

infections. However, there are certain situations in which CT scan is mandatory. Medical treatment is very effective for pre-septal infection. The choice of surgical approach for managing postseptal infection will depend upon the expertise of the surgeon, the site and extension of the abscess and the state of the nasal cavity. Early and accurate management can reduce morbidity and mortality.

Acknowledgement

Author acknowledge Otolaryngology, Ophthalmology and Radiology Departments at Al-Imamein Al-Kadhimein Medical City for their help and support in accomplishing this.

Conflict of interest

Author declare no conflict of interest.

Funding

Self-funded.

References

1. Giannoni CM. Complications of Rhinosinusitis. In: Johnson JT, Rosen CA (eds). Bailey's Head and neck surgery otolaryngology. 5th ed. Lippincott Williams & Wilkins; 2013. p. 573-9.
2. Scadding G & Caulfield H. Pediatric Rhinosinusitis. In: Gleeson MJ, (ed). Scott-Brawn's Otorhinolaryngology head and neck surgery. 7th ed. Hodder Arnold; 2008. p. 1085.
3. Chandler JR, Langenbrunner DJ, Stevens ER. The pathogenesis of orbital complications in acute sinusitis. *Laryngoscope*. 1970; 80(9): 1414-28. doi: 10.1288/00005537-197009000-00007.
4. Oxford LE, McClay J. Medical and surgical management of subperiosteal orbital abscess secondary to acute sinusitis in children. *Int J Pediatr Otorhinolaryngol*. 2006; 70(11): 1853-61. doi: 10.1016/j.ijporl.2006.05.012.
5. Mafee MF, Tran BH, Chapa AR. Imaging of rhinosinusitis and its complications: plain film, CT, and MRI. *Clin Rev Allergy Immunol*. 2006; 30(3): 165-86. doi: 10.1385/CRIAI:30:3:165.
6. Bhattacharyya N, Jones DT, Hill M, et al. The diagnostic accuracy of computed tomography in pediatric chronic rhinosinusitis. *Arch Otolaryngol Head Neck Surg*. 2004; 130(9): 1029-32. doi: 10.1001/archotol.130.9.1029.
7. Vázquez E, Creixell S, Carreño JC, et al. Complicated acute pediatric bacterial sinusitis: Imaging updated approach. *Curr Probl Diagn Radiol*. 2004; 33(3): 127-45. doi: 10.1067/j.cpradiol.2004.01.003.

8. Blumfield E, Misra M. Pott's puffy tumor, intracranial, and orbital complications as the initial presentation of sinusitis in healthy adolescents, a case series. *Emerg Radiol.* 2011; 18(3): 203-10. doi: 10.1007/s10140-010-0934-3.
9. Nageswaran S, Woods CR, Benjamin DK Jr, et al. Orbital cellulitis in children. *Pediatr Infect Dis J.* 2006; 25(8): 695-9. doi: 10.1097/01.inf.0000227820.36036.f1.
10. Huang SF, Lee TJ, Lee YS, et al. Acute rhinosinusitis-related orbital infection in pediatric patients: a retrospective analysis. *Ann Otol Rhinol Laryngol.* 2011; 120(3): 185-90. doi: 10.1177/000348941112000307.
11. Sultész M, Csákányi Z, Majoros T, et al. Acute bacterial rhinosinusitis and its complications in our pediatric otolaryngological department between 1997 and 2006. *Int J Pediatr Otorhinolaryngol.* 2009; 73(11): 1507-12. doi: 10.1016/j.ijporl.2009.04.027.
12. Goytia VK, Giannoni CM, Edwards MS. Intraorbital and intracranial extension of sinusitis: comparative morbidity. *J Pediatr.* 2011; 158(3): 486-91. doi: 10.1016/j.jpeds.2010.09.011.
13. Smith JM, Bratton EM, DeWitt P, et al. Predicting the need for surgical intervention in pediatric orbital cellulitis. *Am J Ophthalmol.* 2014; 158(2): 387-94.e1. doi: 10.1016/j.ajo.2014.04.022.
14. Botting AM, McIntosh D, Mahadevan M. Paediatric pre- and post-septal peri-orbital infections are different diseases. A retrospective review of 262 cases. *Int J Pediatr Otorhinolaryngol.* 2008 Mar; 72(3): 377-83. doi: 10.1016/j.ijporl.2007.11.013.
15. Ho CF, Huang YC, Wang CJ, et al. Clinical analysis of computed tomography-staged orbital cellulitis in children. *J Microbiol Immunol Infect.* 2007; 40(6): 518-24.
16. Clary RA, Cunningham MJ, Eavey RD. Orbital complications of acute sinusitis: comparison of computed tomography scan and surgical findings. *Ann Otol Rhinol Laryngol.* 1992; 101(7): 598-600. doi: 10.1177/000348949210100710.
17. Howe L, Jones NS. Guidelines for the management of periorbital cellulitis/abscess. *Clin Otolaryngol Allied Sci.* 2004; 29(6): 725-8. doi: 10.1111/j.1365-2273.2004.00889.x.
18. Ozkurt FE, Ozkurt ZG, Gul A, et al. Management of orbital complications of sinusitis. *Arq Bras Oftalmol.* 2014; 77(5): 293-6. doi: 10.5935/0004-2749.20140074.
19. Sobol SE, Marchand J, Tewfik TL, et al. Orbital complications of sinusitis in children. *J Otolaryngol.* 2002; 31(3): 131-6. doi: 10.2310/7070.2002.10979.
20. Ailal F, Bousfiha A, Jouhadi Z, et al. Cellulites orbitaires chez l'enfant à propos d'une étude rétrospective de 33 cas [Orbital cellulitis in children: a retrospective study of 33]. *Med Trop (Mars).* 2004; 64(4): 359-62.
21. Moubayed SP, Vu TT, Quach C, et al. Periorbital cellulitis in the pediatric population: clinical features and management of 117 cases. *J Otolaryngol Head Neck Surg.* 2011; 40(3): 266-70.
22. Ikeda K, Oshima T, Suzuki H, et al. Surgical treatment of subperiosteal abscess of the orbit: Sendai's ten-year experience. *Auris Nasus Larynx.* 2003; 30(3): 259-62. doi: 10.1016/s0385-8146(03)00060-9.
23. Migirov L, Yakirevitch A, Bedrin L, et al. Endoscopic sinus surgery for medial orbital subperiosteal abscess in children. *J Otolaryngol Head Neck Surg.* 2009; 38(4): 504-8.
24. Younis RT, Lazar RH, Bustillo A, et al. Orbital infection as a complication of sinusitis: are diagnostic and treatment trends changing? *Ear Nose Throat J.* 2002; 81(11): 771-5.
25. Rubin F, Pierrot S, Lebreton M, et al. Drainage of subperiosteal orbital abscesses complicating pediatric ethmoiditis: comparison between external and transnasal approaches. *Int J Pediatr Otorhinolaryngol.* 2013; 77(5): 796-802. doi: 10.1016/j.ijporl.2013.02.014.
26. Dewan MA, Meyer DR, Wladis EJ. Orbital cellulitis with subperiosteal abscess: demographics and management outcomes. *Ophthalmic Plast Reconstr Surg.* 2011; 27(5): 330-2. doi: 10.1097/IOP.0b013e31821b6d79.

**E-mail: j_m_k65@yahoo.com,
j_m_k65@nahrainuniv.edu.iq**

Received Jan. 15th 2021

Accepted Apr. 19th 2020