

## Gomco Clamp Circumcision in Neonates and Infants: A Preliminary Experience in Iraq

Ali E. Joda *FIBMS*

Dept. of Surgery, College of Medicine, Al-Mustansiriyah University, Dept. of Pediatric Surgery, Central Child Teaching Hospital, Baghdad, Iraq

### Abstract

- Background** Circumcision and its complications are one of the most common cases that pediatric surgeons facing in their practice. There are many techniques that have been described to perform it either by the free hand operative methods or with the use of special devices.
- Objective** To evaluate the results of using Gomco clamp for circumcision as a preliminary experience in Iraq.
- Methods** A total of 120 babies were subjected to circumcision by this device during the period from April 2014 - November 2015; their age ranges from 7 days - 11 months and they were divided into 3 groups: neonates, infants 1-3 months, infants 4-11 month. By using three different sizes of the clamp, the procedure was performed under local anesthesia in the majority of cases in a form of subcutaneous ring block with aid of sedatives while general anesthesia was given to those cases of coincidental circumcision with other operations. The outcomes of the procedure were assessed after one-month period of follow up.
- Results** 12.5% of cases were neonates; the average duration of the procedure was 20 minutes. A total complication rate of 9.16% was recorded (11 cases out of 120. The lowest rate of complication (6.6%) was seen in neonates, while the group of infants older than 4 months had the highest complication rate (10%). The most frequent complication recorded was bleeding (36.3% of all complication rate) followed by excess skin, infection, meatitis, epidermal inclusion cyst, no other complications were recorded.
- Conclusion** Circumcision by Gomco clamp is a safe and simple method with good functional and cosmetic results if performed during neonatal period and early infancy. Choosing the suitable size of the clamp, adequate training and good postoperative care will minimize most of the complications.
- Keywords** Circumcision, Gomco clamp, neonate, infant, complications.
- Citation** Ali E. Joda. Gomco clamp circumcision in neonates and infants: a preliminary experience in Iraq. *Iraqi JMS*. 2017; Vol. 15(2): 188-197. doi: 10.22578/IJMS.15.2.12

**List of abbreviations:** None

### Introduction

The word "circumcision" in Etymology means "cut around", from circum = around; + caedō = cut (in Latin). The surgical removal of the prepuce, is the commonest and oldest procedure performed in males, it was dating back to 4000 BC where the ancient mummies were found to be

circumcised as it has been mentioned in Egyptian papyri and wall carvings<sup>(1)</sup>. Perhaps it was initially performed in the ancient societies of the Middle East as a public health measure to prevent recurrent balanitis resulting from collection of sand under the foreskin<sup>(2)</sup>. About one out of three males are circumcised universally<sup>(3)</sup>, it is practiced among Indian Muslims, in United States, Canada, various

countries of South East Asia and large parts of Africa <sup>(4,5)</sup> but the region of the Middle East constitutes the largest circumcised population due to their cultural and religious beliefs. Circumcision is a fundamental part of the traditions of many religions, particularly Judaism and Islam, in Judaism, male circumcision is considered a commandment from God whereas it is considered to be a Sunnah in Islam <sup>(6)</sup>.

### Indications

The most common reasons for performing circumcision are religious, ritualistic, and cultural reasons and it was not “medicalized.” until the 19<sup>th</sup> century when it was justified by the relative medical indications <sup>(7)</sup> like urinary tract infections, prevention of HIV or other sexually transmitted infections, penile cancer, possible trauma to foreskin, and paraphimosis. While pathological phimosis and recurrent balanoposthitis are considered to be an absolute indication. The only true contraindications for circumcision includes the presence of hypospadias or epispadias, as the prepuce may be needed for the creation of the neourethra.

### Complications

Although circumcision can be regarded a relatively safe operation, it is not completely without complications and these are usually of low rate <sup>(3,8)</sup> when they done in hospitals or by the medical staff, while all of the community circumcisions that done by traditional circumciser have no recorded data of complication rates. In general, the rate of complication is dependent on age at circumcision, the technique or device used and the experience of the surgeon. Most of these complications are simple and easily treated <sup>(9)</sup> like mild bleeding, infection, pain, hematoma, simple glanular injury, urethral meatitis, meatal stenosis, urine retention, and other less common complications. Serious complications are often related to general anesthesia used, sepsis following severe infection, urethra-

cutaneous fistula, ischemic necrosis of the glans and amputation <sup>(10)</sup> and even an extremely rare occurrence of circumcision-related deaths have been reported in some patients <sup>(11,12)</sup>.

### Technique of Gomco clamp circumcision

The device was invented by Hiram S. Yellen and Aaron Goldstein in 1934-1935 <sup>(1,13)</sup>. Gomco represents the Goldstein Medical Company, the original manufacturer of the clamp. It consists of 4-pieces (arm, plate, nut and stud) (figure 1). It has the advantages of glans protection, hemostasis and a platform for resecting the prepuce with no need of suturing <sup>(14)</sup>. In the United States, Gomco clamp has become a popular instrument used for performing non-ritual circumcision and preferred by both doctors and families <sup>(15)</sup> as it evident by its safety record in preventing injury and low risk of bleeding.

The objective of this study is to evaluate the results of Gomco clamp circumcision as a preliminary experience in our country, its advantages and disadvantages in neonates and infants.


### Methods

This prospective study was done at the Department of Pediatric Surgery in the Central Child Teaching Hospital over the period from April 2014 – November 2015 during which, a total 120 babies were enrolled in the study, their ages ranging from 7 days – 11 months. The indications were parental decision, chronic urinary tract infection, recurrent balanoposthitis, phimosis, paraphimosis and coincidence with other surgery when circumcision advised by the doctor or requested by the family. For ethical consideration, the parents or guardians were asked for informed written consent to participate in the study. All of the babies underwent circumcision using Gomco clamp-by the same pediatric surgeon, a blood sample for a complete blood count, prothrombin time and partial thromboplastin time were routinely

## Joda, Gomco Clamp Circumcision in Neonates and Infants .....

done before the procedure. The exclusion criteria were:

- Re-circumcision.
- Age more than 1 year.
- Bleeding tendency.
- Congenital penile anomalies (hypospadias, epispadias, chordee, webbed penis, megalourethra).
- Microphallus.
- Infant obesity or baby with excessive suprapubic fat pad.
- Parent refusal.



**Figure 1. Parts of Gomco clamp**

Three different sizes of Gomco clamp were used; one for neonatal age (Extra Small 1.1 cm) and the two others for older ages (1.3 cm and 1.45 cm), the procedure was performed in the operative theatre, under local anesthesia and sedatives while general anesthesia was used in cases of coincidental circumcision with other surgeries. The children were given oral chloral hydrate syrup 25 – 50 mg/kg 30 minutes before the procedure for sedation and paracetamol 125-250 mg suppositories for analgesia. After sterilization of the area with povidone iodine solution, local anesthesia was used in a form of subcutaneous ring block (SCRB) using 1% lidocaine without adrenalin through 25 G or 28 G syringe (insulin syringe), usually 1-1.5 ml of lidocaine was infiltrated around the penis 1 cm proximal to its base in band or ring form just in the subcutaneous tissue superficial to Buck's fascia.

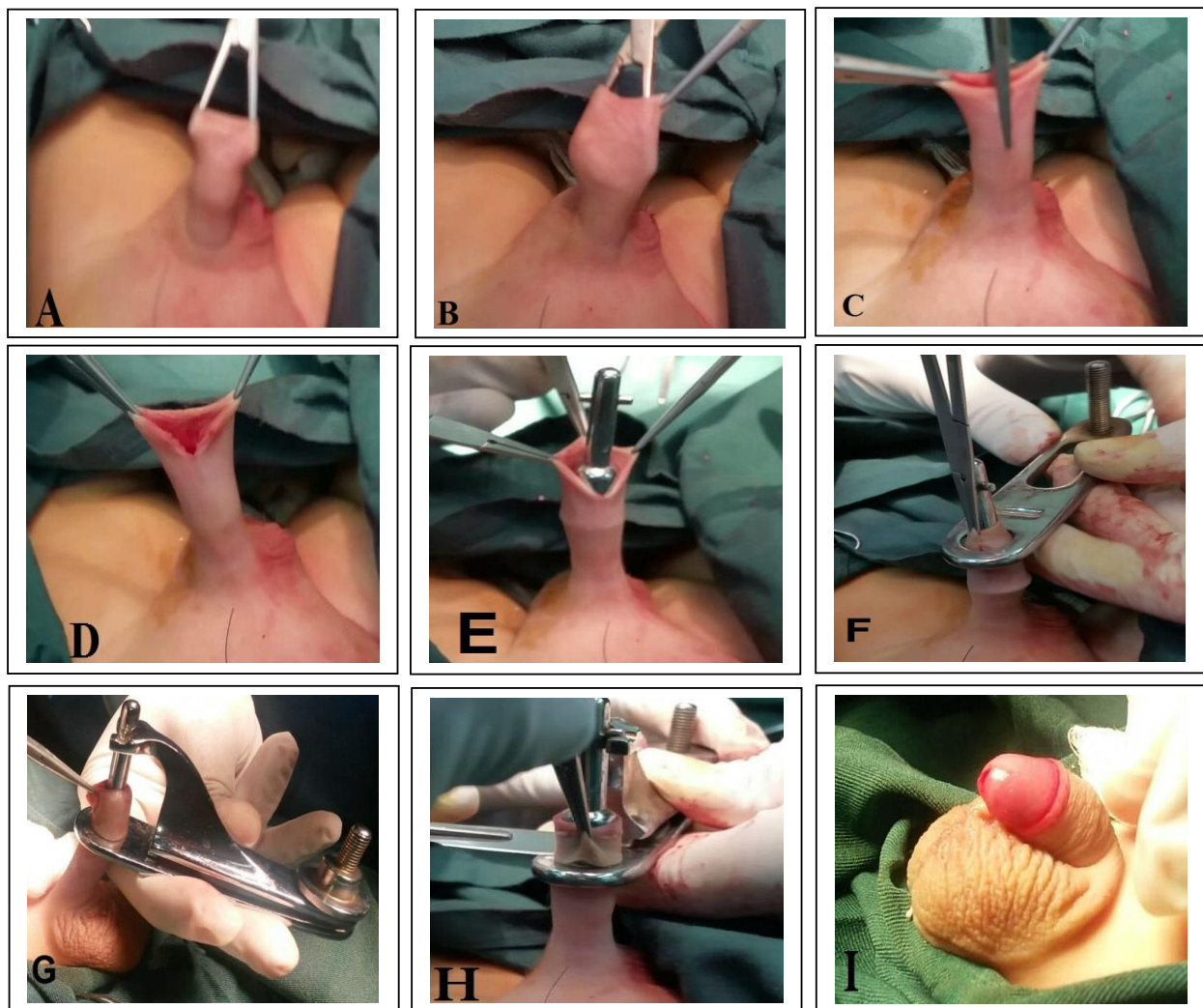
### **The Gomco Technique** <sup>(10,15,20)</sup>

The preputial opening is stretched with artery forceps (figure 2-A), the foreskin is grasped with two hemostats at 3 and 9 o'clock and separated completely from the glans by inserting a curved mosquito forceps between glans and foreskin at 12 o'clock down to the level of the corona and swept around the glans on both the right and left sides, avoiding the ventral frenulum (figure 2-B), the foreskin is then retracted proximally to check the glans for any hidden adhesions, then a hemostat is utilized to create a crush line on the dorsal aspect of the prepuce till the coronal sulcus in order to reduce bleeding (figure 2-C), the crushed skin is then cut with blunt scissors (figure 2-D) to make space for suitable size bell to be applied over the glans and under the foreskin (figure 2-E). After determining the amount of the shaft skin to be left below the corona, the edges of the dorsal slit are grasped

and the foreskin is pulled through the hole of the base plate and over the bell (figure 2-F), the clamp's arm is fitted, confirm the length of foreskin to be excised, the nut on the Gomco clamp is tightened and left in place for about five minutes so the prepuce is squeezed between the bell and the base plate to make it bloodless (figure 2-G), A scalpel is used to make a circumferential incision in the foreskin at the level of the base plate (figure 2-H). In such way, the clamp allows clotting and hemostasis to occur, the nut is then loosened, and clamp's

base and bell are then removed from the penis. The penis now is inspected for any bleeding specially from the ventral frenulum region (figure 2-I). A dressing with Fucidin ointment gauze should be gently applied at the incision line, the baby observed for 2 hours in the ward then discharged home if no complications occurred.

Statistical analysis was done using SPSS-18 (statistical package for social sciences) software, and the results were expressed in mean  $\pm$  SD and percentage.



**Figure 2. Stages of Gomco circumcision**

### Results

The cases were divided into 3 groups; neonates (15 cases) with mean age 15.6 days, infants 1-3 months (35 cases) with mean age 2.4 months

and infants 4-11 months (70 cases) with mean age 6.5 months (Table 1).

The reasons of circumcision were as follow: according to the parent decision in 43 babies

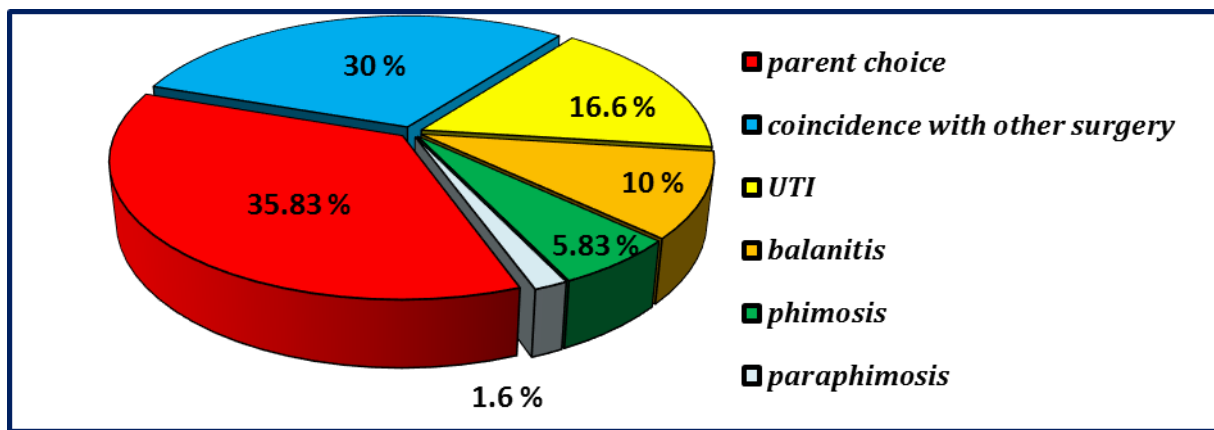
## Joda, Gomco Clamp Circumcision in Neonates and Infants .....

(35.83%), coincidence with other surgeries (like inguinal herniotomy, orchidopexy, release of ankyloglossia, excision of external angular dermoid cyst) in 36 babies (30%) when circumcision advised by doctor or requested by the family, urinary tract infection in 20 babies (16.6%), recurrent balanoposthitis in 12 babies

(10%), phimosis in 7 babies (5.83%), and paraphimosis in 2 babies (1.6%) (figure 3). The procedure was performed electively in all the cases except for the two cases of paraphimosis which were done as an emergency operation after failure of manual reduction.

**Table 1. Age groups of circumcision**

Age	No. of cases (%)	Mean±SD
Neonate	15 (12.5%)	15.6 days ± 3.9
1-3 months	35 (29.1%)	2.4 months ± 1.47
4-11 months	70 (58.3%)	6.5 months ± 1.65
Total	120 (100%)	



**Figure 3. Reasons for circumcision**

The procedure was done under local anesthesia in 70% of cases (84 babies) and general anesthesia was given for the remainder 36 babies (30% of cases) because it was coincidental with other surgeries. The average duration of the procedure was 20 minutes. Complications were seen in 11 out of 120 cases with the total rate of complications was 9.16%. (Table 2). All of the complications were simple and no serious adverse results were noticed. The lowest rate of complication (6.6%) was seen in neonates, (9% of all complication), while the group of infants older than 4 months had the highest complication rate, 10% (63.6% of all complication), (figure 5).

The most frequent complication recorded was bleeding, (figure 4) which was seen in 4 cases all were developed when circumcision performed beyond neonatal age, in three of them the bleeding was stopped by suturing immediately following release of clamp and one case was treated by re-enforcing dressing after he was discharged to the ward. Excess skin was seen in 2 cases of infants, infection was developed in 2 cases one in neonate and the other at age of 3 months, epidermal inclusion cyst was developed in one infant of 6 months age, and two cases were developed meatitis treated by topical application of antibiotic. No other complications were recorded.

Table 2. Complications of Gomco circumcision in different age groups

Complications		Cases	Neonates	1-3 m	4-11 m
Early	Bleeding	4	0	1	3
	Excess skin	2	0	0	2
	Glans injury	0	0	0	0
	Urethral injury	0	0	0	0
	Urine retention	0	0	0	0
	Edema	0	0	0	0
	Infection	2	1	1	0
Late	Epidermal inclusion cyst	1	0	0	1
	Preputial adhesion	0	0	0	0
	Buried penis	0	0	0	0
	Urethra-cutaneous fistula	0	0	0	0
	Meatitis	2	0	1	1
	Meatal stenosis	0	0	0	0
	Cosmetic dissatisfaction	0	0	0	0
<b>Total (%)</b>		<b>11 (9.16%)</b>	<b>1 (0.8%)</b>	<b>3 (2.5%)</b>	<b>7 (5.8%)</b>

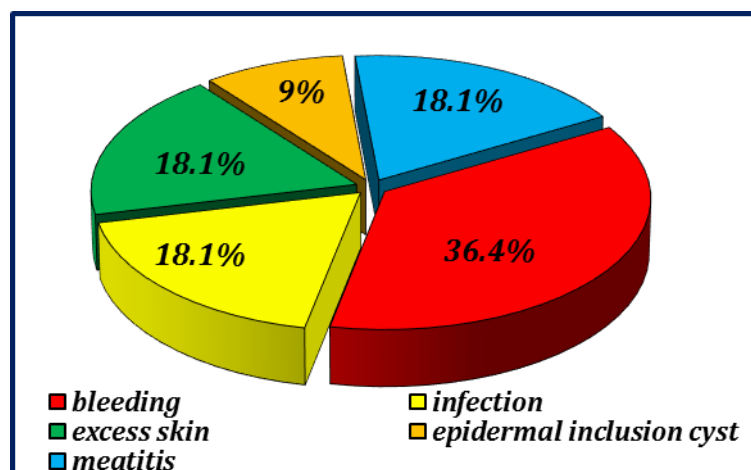


Figure 4. Types of complications

### Discussion

A Gomco clamp is being used in different parts of the world like USA, Canada, South Africa, Turkey and Saudi Arabia <sup>(3)</sup>, it was firstly started to be used in our country in 2014, so this study was implemented to present our preliminary experience with this device. We excluded the following groups of babies from the study in order not to affect the results:

- Cases of complicated previous circumcision that required re-circumcision.

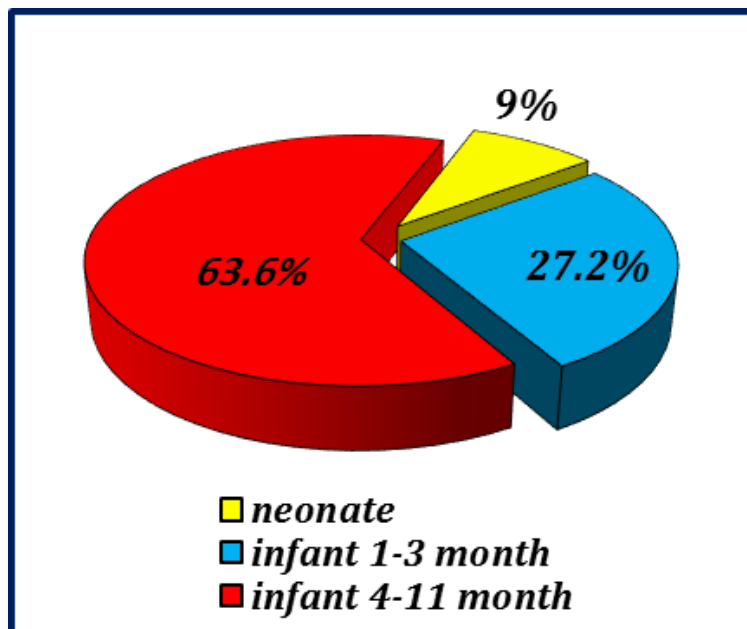
- Infants older than one year due to unavailability of the suitable size clamp.
- Those infants with bleeding tendency
- When the family refused to subject their baby to this technique of circumcision.

The reported complication rates of circumcision depend on the type of study performed (retrospective or prospective), setting (medical or non-medical facility), operating personnel (traditional or medical practitioner), patient age (neonate, infant and

**Joda, Gomco Clamp Circumcision in Neonates and Infants .....**

older child) and surgical technique or device used <sup>(3)</sup>. Our rate of complication was 9.16% which although higher than comparative studies (Table 3) but is accepted as an initial

experience with this technique. This high rate may be attributed to the large percent of old infants included in the study compared with other studies.



**Figure 5. Complications in different age groups**

**Table 3. Comparative complication rate with other studies <sup>(3)</sup>**

Study	Country	Year	No. of cases	Age	% of complication
Patel	Canada	1966	100	Neonates + infants	15 %
O'Brien	USA	1985	1951	Neonates	3.1 %
Amir	KSA	2000	1000	Neonates	1.6 %
Horowitz	USA	2001	130	Neonates + infants	7.4 %
Eroglu	Turkey	2002	214	Neonates	2.3 %
Perlmutter	USA	2007	51	Neonates	0.0 %
Baniqbal	South Africa	2009	583	Neonates	0.3 %
Current study	Iraq	2015	120	Neonates + infants	9.16 %

Most of complications from using Gomco clamp are resulting from technical error like not using suitable size of clamp (too large clamp result in removal of too much skin), the metal bell not covers the glans completely (result in glans injury), insufficient drawing up of skin will lead to an inadequate skin removal, insufficient tightening of the screw result in inadequate compression of the skin and subsequent bleeding, so it is better to keep the

screw tightened for 5 minutes before its release to secure hemostatic compression. Current data revealed that bleeding was the most frequent complication noticed accounting for 36.4% of all complications (figure 4). This is in agreement with other studies like Atikeler et al. <sup>(16)</sup>, Burgu et al. <sup>(17)</sup>. It was noticed that bleeding rate in 3.3% of all Gomco procedures (four cases out of 120 procedures) compared to Feinberg et al. study who reported bleeding

in 4.47% of all Gomco procedures <sup>(18)</sup> (24 bleeds out of 537 procedures). All of these bleeding cases were recorded in babies beyond neonatal ages and they were simple and easily treated by re-enforcing dressing or suturing. Kurtoğlu and Baştuğ in their study <sup>(19)</sup> demonstrated a higher risk of bleeding during the "minipuberty" of infancy, which starts after four weeks of age extends to three months of age because of hormonally mediated increase in vascularity and size of penis and prepuce. This is also confirmed by Horowitz and Gershbein <sup>(20)</sup> who reported zero rate of bleeding in babies circumcised with a Gomco clamp in their first month of life compared to 30% bleeding complication rate requiring suturing or cauterization in those aged 3-8 months.

Infection was the second most frequent complication constituting 18% of all complications. Infection rate was 1.6% (2 cases out of 120), which goes with the systemic review and meta-analysis done by Ford et al. <sup>(21)</sup> who reported infection rate in the range of 0.3-1.85% of cases. Nevertheless, infection rate in Gomco clamp is still lower than those reported by other techniques, four out of 95 plastibell circumcisions (4.2%) had local sepsis requiring surgical toilet <sup>(22)</sup>. Bowa et al also reported 1.4% infection rate after plastibell circumcission compared to 1% after Gomco clamp due to the presence of foreign body in case of plastibell <sup>(23)</sup>. An increased infection rate is also expected to develop when electrocautery used for incision of circumcission as stated by NICE guidelines (National Institute for Health and Clinical Excellence) about surgical site infection <sup>(24)</sup>. Most of the reported infections are minor without significant consequences and can be prevented by proper patient preparation, wearing gloves, good local wound care including cleaning the penis after circumcission and application of antibiotic ointment with diaper changes <sup>(25)</sup>.

The complication of excess skin was seen in 18% of our complication rate and this is quite common problem with many other techniques,

in a retrospective review done in USA 2010, 40% of late complication following circumcission done by different techniques were inadequate circumcission (excess skin) <sup>(26)</sup>. This problem can be avoided by choosing a size of Gomco bell according to the glans diameter rather than the length of the penile shaft, because the too small bell will fail to protect the glans and causes insufficient foreskin to be pulled through the hole of the base plate resulting in excess foreskin.

Post-circumcision meatitis was seen in 18% of our complication rate. It may account for up to 26% of the late complication of circumcission in one study <sup>(26)</sup>. It has been postulated to be resulting from ammoniacal dermatitis to the meatus after the removal of the prepuce due to friction between the exposed meatus and diaper <sup>(25)</sup>. Weiss et al. in his systemic review reported this problem as a well-recognized late complication of circumcission performed during diaper age <sup>(3)</sup>. However, meatitis is a self-limiting problem and can be treated with topical antibiotics and keeping the area dry. While post-circumcision meatal stenosis may be due to chronic meatitis or resulting from ligation of the frenular artery <sup>(25)</sup> and can be treated by simple dilatation or meatotomy under general anesthesia.

Traumatic amputation of the glans is rare but a devastating complication seen with bone cutter, Mogen clamp or plastibell circumcission <sup>(27,28)</sup> because of inability to directly visualize the glans prior to incising the foreskin. Bone cutter circumcission technique is widely used in our country and partial glans amputation can occur if the operator inadvertently catches the glans in the cutter, this is quite contrast to Gomco clamp as this device incorporate a glans protective mechanism that prevents its inclusion and injury during circumcission (zero rate of glans injury in our data).

We got good results about shape of penis, stream of urine following circumcission as stated by the parents (zero rate of dissatisfaction). The cosmetic contentment following circumcission is highly dependent on



the socioeconomic status and educational level of the parents, so when circumcision is performed for religious reasons, the cosmetic result will be highly accepted from the parents<sup>(29)</sup>. Sexual satisfaction and penile sensitivity need to be assessed in adult life but in general male circumcision does not adversely affect sexual satisfaction or clinically significant function in men as reported by Kigozi et al.<sup>(30)</sup>. This study concluded that Gomco Clamp circumcision is a safe and simple method of circumcision with good functional and cosmetic results, having the advantages of straight circumcision scar, no associated injury to the underlying glans or urethra and less infection rate but carry its drawbacks of having several small parts that need to be sterilized to minimize the risk of infection, the procedure take longer time than other techniques like Mogen clamp or the traditional way with bone cutter. Most of the complications with this device can be prevented by choosing the suitable size of clamp, sufficient training and good postoperative nursing care. A higher complication rate is associated with using this device beyond the neonatal period.

### Acknowledgments

None.

### Conflict of interest

None.

### Funding

Self-funding.

### References

1. Totaro A, Volpe A, Racioppi M, et al. Circumcision: history, religion and law. *Urologia*. 2011; 78(1): 1-9. doi: 10.5301/RU.2011.6433.
2. Hutson JM. Circumcision: A surgeon's perspective. *J Med Ethics*. 2004; 30(3): 238-40. <http://dx.doi.org/10.1136/jme.2002.001313>.
3. Weiss HA, Larke N, Halperin D, et al. Complications of circumcision in male neonates, infants and children: a systematic review. *BMC Urology* 2010, 10(1): 2. doi: 10.1186/1471-2490-10-2.
4. World Health Organization, UNAIDS. Neonatal and child male circumcision: a global review. UNAIDS/10.07E – JC1672E; 2010. p. 8.
5. Drain PK, Halperin DT, Hughes JP, et al. Male circumcision, religion and infectious diseases: An ecologic analysis of 118 developing countries. *BMC Infect Dis*. 2006; 6(1): 172. doi: 10.1186/1471-2334-6-172.
6. Anwar MS, Munawar F, Anwar Q. Circumcision: a religious obligation or 'the cruellest of cuts'? *Br J Gen Pract*. 2010; 60(570): 59-61. doi: 10.3399/bjgp10X482194.
7. Pdraig Malone, Henrik Steinberche. Medical aspect of male circumcision. *BMJ*. 2007; 335(7631): 1206-9. doi: 10.1136/bmj.39385.382708.AD.
8. Thorup J, Thorup SC, Ifaoui IB. Complication rate after circumcision in a paediatric surgical setting should not be neglected. *Dan Med J*. 2013; 60(8): A4681.
9. Muula AS, Prozesky HW, Mataya RH, et al. Prevalence of complications of male circumcision in Anglophone Africa: A systematic review. *BMC Urol*. 2007; 7(1): 4. doi: 10.1186/1471-2490-7-4.
10. Bhat NA, Raashid H, Rashid KA. Complication of circumcision. *Saudi J Med Med Sci*. 2014; 2(2): 86-9.
11. Meel BL. Traditional male circumcision-related fatalities in the Mthatha area of South Africa. *Med Sci Law* 2010; 50(4): 189-91. doi: 10.1258/msl.2010.010017.
12. Hedjazi A, Zarenezhad M, Hosseini SM, et al. Epidemiology of circumcision related mortality in Iran: A 10 year survey. *N Am J Med Sci*. 2012; 4(11): 608-10. doi: 10.4103/1947-2714.103338.
13. Wang J, Zhou Y, Xia S, et al. Safety and efficacy of a novel disposable circumcision device: A pilot randomized controlled clinical trial at 2 centers *Med Sci Monit*. 2014; 20: 454-62. doi: 10.12659/MSM.889722.
14. Bhat NA, Hamid R, Rashid KA. Bloodless, sutureless circumcision. *Afr J Paediatr Surg*. 2013; 10(3): 252-4.
15. Burns SD. GOMCO clamp circumcision. 2011. [www.Naturalfamilyonline.com](http://www.Naturalfamilyonline.com). [accessed at 18/11/2015].
16. Atikeler MK, Geçit I, Yüzgeç V et al. Complications of circumcision performed within and outside the hospital. *Int Urol Nephrol*. 2005; 37(1): 97-9. doi: 10.1007/s11255-004-6077-2.
17. Burgu B, Aydogdu O, Tungal S, et al. Circumcision: pros and cons. *Indian J Urol*. 2010; 26(1): 12-5. doi: 10.4103/0970-1591.60437.
18. Feinberg AN, Brust RA, Walker TA. Bleeding at Circumcision: Patient or Operator Issue? *Clin Pediatr (Phila)*. 2010; 49(8): 760-3. doi: 10.1177/0009922810364658.
19. Kurtoğlu S, Baştuğ O. Mini puberty and its interpretation. *Turk Pediatri Ars*. 2014; 49(3): 186-91. doi: 10.5152/tpa.2014.2038.
20. Horowitz M, Gershbein AB. Gomco circumcision: when is it safe? *J Pediatr Surg*. 2001; 36(7): 1047-9. doi: 10.1053/jpsu.2001.24739.
21. Ford N, Chu K, Mills EJ. Safety of task shifting for male medical circumcision: a systematic review and meta-

- analysis. *AIDS*. 2012; 26(5): 559-66. doi: 10.1097/QAD.0b013e32834f3264.
22. Lazarus J, Alexander A, Rode H. Circumcision complications associated with the Plastibell device. *S Afr Med J*. 2007; 97(3): 192-3.
23. Bowa K, Li MS, Mugisa B, et al. A controlled trial of three methods for neonatal circumcision in Lusaka, Zambia. *J Acquir Immune Defic Syndr*. 2013; 62(1): e1-6. doi: 10.1097/QAI.0b013e318275741b.
24. Surgical site infections: prevention and treatment. <http://www.nice.org.uk/nicemedia/CG74NICEGuideline.pdf>. 2008. [accessed at 17/11/15]
25. Hutcheson JC. Male neonatal circumcision: indications, controversies and complications. *Urol Clin North Am*. 2004; 31(3): 461-7, viii. doi: 10.1016/j.ucl.2004.04.011.
26. Pieretti R V, Goldstein A M, Pieretti-Vanmarcke R. Late complications of newborn circumcision: a common and avoidable problem. *Pediatr Surg Int*. 2010 May;26(5):515-8. doi: 10.1007/s00383-010-2566-9.
27. Krill AJ, Palmer LS, Palmer JS. Complications of circumcision. *Scient World J*. 2011; 11, 2458-68. doi: 10.1100/2011/373829.
28. Bode CO, Ikhisemogie S, Ademuyiwa AO. Penile injuries from proximal migration of the Plastibell circumcision ring. *J Pediatr Urol*. 2010; 6(1): 23-7. doi: 10.1016/j.jpuro.2009.05.011.
29. Corduk N, Unlu G, Sarioglu-Buke A, et al. Knowledge, attitude and behaviour of boys and parents about circumcision. *Acta Paediatr*. 2013; 102(4): e169-73. doi: 10.1111/apa.12152.
30. Kigozi G, Watya S, Polis CB, et al. The effect of male circumcision on sexual satisfaction and function, results from a randomized trial of male circumcision for human immunodeficiency virus prevention, Rakai, Uganda. *BJU Int*. 2008; 102(6): 762-3. doi: 10.1111/j.1464-410X.2008.07995\_3.x.

---

**E-mail: ali.egab.joda@gmail.com**

**alieagle677@yahoo.com**

**Received Oct. 10<sup>th</sup> 2016**

**Accepted Feb. 21<sup>st</sup> 2017**