

IRAQI JOURNAL OF MEDICAL SCIENCES

CHAIRMAN OF THE EDITORIAL BOARD

Professor Adnan A. Anoze *MRCP*.

CHIEF EDITOR

Professor Fakhir S. Al-Ani *PhD*.

EXECUTIVE EDITORIAL BOARD

Prof.	Ghassan A. Al-Shamma <i>PhD</i>	EDITOR
Prof.	Alaa G. Hussien <i>FICMS</i>	EDITOR
Prof.	Nidhal Abdul-Muhymen <i>PhD</i>	EDITOR
Asst. Prof.	Samir M. Jasim <i>PhD</i>	EDITOR
Asst. Prof.	Muataz A. Al-Qazzaz <i>FICMS</i>	EDITOR
Asst. Prof.	Hussam A. Ahmed <i>FRCS</i>	EDITOR
Asst. Prof.	Enas T. Abdul-Karim <i>DCH, PhD</i>	EDITOR
Asst. Prof.	Atheer J. Al-Saffar <i>FICMS</i>	EDITOR
Asst. Prof.	Hasan A. AL-Hamadani <i>FICMS</i>	EDITOR
Asst. Prof.	Hala S. Aref <i>CABP</i>	EDITOR
Asst. Prof.	Waseem F. Mohammed <i>FICMS</i>	EDITOR
Asst. Prof.	Haider J. Mobarak <i>PhD</i>	EDITOR
Asst. Prof.	Suhad M. Salih <i>FICOG</i>	EDITOR
Lecturer	Ali F. Hadi <i>PhD</i>	EDITOR

JOURNAL SECRETARY

Esraa' S. Naji

TECHNICAL EDITOR

Aliaa' N. Hatam

IRAQI JOURNAL OF MEDICAL SCIENCES

All articles published represent the opinions of the authors and do not reflect the policy of **IRAQI JOURNAL OF MEDICAL SCIENCES**. All rights are reserved to **IRAQI JOURNAL OF MEDICAL SCIENCES**. No part of the journal may be reproduced or transmitted in any form or by any means, electronic or mechanical, including photocopying, recording, or via any storage or retrieval system, without written permission from the journal.

All correspondence and subscription information requests should be addressed to:

The Editor of **IRAQI JOURNAL OF MEDICAL SCIENCES**

P. O. Box 14222, Baghdad, Iraq.

College of Medicine

Baghdad, Iraq

Tel and Fax: 964-1-5224368

E-mail: Iraqi_jms_alnahrain@yahoo.com

ADVISORY COMMITTEE

Deans of the Iraqi Colleges of Medicine

Medical College \ Al-Nahrain University	Adnan A. Anoze	Prof.
Medical College \ Baghdad University	Fadhil A. Al-Kafaji	Prof.
Al-Kindi Medical College \ Baghdad University	Faris Abdul kareem	Prof.
Medical College \ Al-Mustansiriya University	Mohammed H. Al-Alwan	Prof.
Medical College \ Al-Mosul University	Muzahim K.Al-Khyatt	Prof.
Medical College \ Nainewa University	Faris Bekir Al-Sawaf	Prof.
Medical College \ Babil University	Ali Khiralla Al-Shaeli	Asst. Prof.
Medical College \ Thiqaq University	Muaied N. Majeed	Asst. Prof.
Medical College \ Al-Anbar University	Abdullah Salih Hasan	Prof.
Medical College \ Tikreet University	Abid Ahmed Selman	Prof.
Medical College \ Diyala University	Khudier K. Ibrahim	Prof.
Medical College \ Karbala University	Zuhair U. Eissa	Prof.
Medical College \ Al-Kufa University	Mohammed S. Abdul-Zahra	Prof.
Medical College \ Al-Basra University	Thamir A. Hamdan	Prof.
Medical College \ AL-Qadisiah University	Rahi K. AL-Yasiri	Prof.
Medical College \ Kirkuk University	Fakhraddin N. Nassir	Prof.
Medical College \ Duhok University	Ferhad Suliffan	Asst. Prof.
Medical College \ Wassit University	Atta Gitti Allawi	Lecturer
Medical College \ Al-Emara University	Ali Abdul-Aziz Al-Shawi	Lecturer
Medical College \ Al-Muthana University	Musaed Al-Dehan	Lecturer

AL-NAHRAIN COLLEGE OF MEDICINE COMMITTEE MEMBERS

Dean Medical College	Adnan A. Anoze	Prof.
Vice Dean Administrative affairs	Hussam H. Ali	Prof.
Vice Dean Scientific & Students affairs	Abdul-Razak H. Ahmed	Asst. Prof.
Chief Microbiology department	Nidhal Abdul-Muhyemen	Prof.
Chief Medicine department	Hashim M. AL-kadimy	Prof.
Chief Gynecology & Obstetrics department	Maha M. AL-Bayati	Prof.
Chief Pathology&Forensic Medicine department	Alaa G. Hussien	Prof.
Chief Chemistry and Biochemistry department	Samir M. Jasim	Asst. Prof.
Chief Surgery department	Abd Ali Muhsin	Asst. Prof.
Chief Physiology department	Farqad Badir Hamdan	Asst. Prof.
Chief Humman Anatomy department	Haider J. Mobarak	Asst. Prof.
Chief Pediatric department	Lamia A.K. AL-Saady	Prof.
Chief Community department	Atheer J. Al-Saffar	Prof.
Chief Pharmacology&Theraputies department	Abdul-Kareem H. Abid	Lecturer
Representative of teaching staff members	Mohammed A.Kadhim	Asst. Prof.

SCIENTIFIC ADVISORY BOARD

(Jordan\ Retierd)	Mahmood Hayawi Hamash	Prof.
(U.A.E\ Retierd)	Rafi M. Al-Rawi	Prof.
(Irf Institute of Embryo Research & Infertility Treatment / Al-Nahrain University)	Anam Rasheed AL-Salihi	Prof.
(Iraqi Board for Medical Specialization \ Retierd)	Amjad Dawood Niazi	Prof.
(Iraqi Board for Medical Specialization \ Retierd)	Nazar Al-Hasani	Prof.
(U.A.E\ Retierd)	Usama N. Rifat	Prof.
(Al-Nahrain University)	Usama S. Al-Nasiri	Prof.
(U.A.E)	Akrem J. Abod	Prof.
(Baghdad University \ Retierd)	Sarmad Khunda	Prof.
(Al-Nahrain University)	Hikmat A.R. Hatam	Prof.
(U.A.E\ Retierd)	Ryadh Abdul-Satar	Prof.
(Al-Nahrain University\ Retierd)	Faroq H. Al-Jawad	Prof.
(Al-Nahrain University\ Retierd)	Sami E. Matlob	Prof.
(Al-Nahrain University)	Sawsan S. Al-Haidari	Prof.
(Al-Nahrain University)	Yarub I. Khattab	Prof.

IRAQI JOURNAL OF MEDICAL SCIENCES

Aims and Scope

IRAQI JOURNAL OF MEDICAL SCIENCES is published by College of Medicine, Al-Nahrain University. It is a quarterly multidisciplinary medical journal. High quality papers written in English, dealing with aspects of clinical, academic or investigative medicine or research will be welcomed. Emphasis is placed on matters relating to medicine in Iraq in particular and the Middle East in general, though articles are welcomed from anywhere in the world.

IRAQI JOURNAL OF MEDICAL SCIENCES publishes original articles, case reports, and letters to the editor, editorials, investigative medicine, and review articles. They include forensic medicine, history of medicine, medical ethics, and religious aspects of medicine, and other selected topics.

IRAQI JMS FORMAT INSTRUCTION TO AUTHORS

Iraqi Journal of Medical Sciences (Iraqi JMS) is a periodic, peer-reviewed journal published quarterly by College of Medicine, Al-Nahrain University. Iraqi JMS publishes manuscripts in all fields of health and medicine written in English.

TYPES OF CONTRIBUTIONS: Original articles, review articles, case studies, editorials, medical education, history of medicine, ethics, practical points, medical quiz, conferences, meetings and letters to the Editor.

MANUSCRIPTS:

- Submission of a manuscript implies that is not being considered for publication anywhere.

- The autor should provide the following:

A. a document officially state that the current work was carried out at the site which provides the certification. The document should be signed by the highest authorized member at that location.

B. a document stated clearly that his current work is in agreement with the medical ethics provided either from the local ethical committee in the place where he did his work or from the Ministry of Health\Depart. Of Training & Improving skill\Research & Educational facilities, the approval has to be stated separately in the method section

C. Publication fees are 50,000 Iraqi dinars and extra fees will be taken for extended paper (6000 dinars for each additional page (more than six pages) and up to 24000 dinars only).

- Manuscripts submitted to IJMS are subject to editorial evaluation and revision by three referees.

- The format of IJMS complies with the uniform requirements for manuscripts submitted to Biomedical Journals, published by the International Committee of Medical Journals Editors (ICMJE) (Vancouver, British Columbia, 1979) and its last update in October 2001, available on the web site www.icmje.org.

- Manuscript should be typewritten double spaced on size A4 (29.5x21 cm) paper with wide margins. Page should be numbered consecutively. One original and three photocopies including figures, tables, and photographs should be submitted. Begin each of following sections on separate page in the following sequence: Title page, abstract and keywords, text, acknowledgments, references, tables, and legends for illustration.

- Manuscript and figures will not be returned to the authors whether the editorial decision is to accept, revise or reject.

- Manuscripts must be accompanied by a covering paper signed by all authors that the paper has not been published in and will not be submitted to any other journal if accepted in IJMS.

- The page should contain (a) title of the manuscript, (b) names of each author (first name, middle initial and family name) including highest academic degree, (c) official academic and/or clinical title and affiliation (d) name and address of the institution where the work was done (e) name and address (E-mail if available) of the author to whom correspondence should be sent.

ABSTRACT: manuscript should include an abstract of not more than 150 words. Structured abstract typed on a separate sheet and consist of background, objective, method, results, and conclusion. Translation in Arabic to be included:

(خلفي الدراسة، هدف الدراسة، طريقة العمل، النتائج و الاستنتاج).

- **KEYWORDS:** three to ten keywords should be provided on the same page as the abstract in Arabic and English. As far as possible, be selected from the National Library of Medicine Medical Subject Headings.
- The Arabic abstract should follow the United Medical Dictionary (Council of Arab Ministers of Health/WHO/ Arab Medical Union/ALESCO, 3rd edition).
- **Manuscript format:** It should be divided into the following parts: introduction, materials and methods, results and discussion.
- **REFERENCES:** All references should be listed in consecutive numerical order by English numerical, in the order of citation in the text. Once a reference is cited all subsequent citations should be to the original number.

EXAMPLES

1. Standard Journal Article: use et al when the number of authors exceeds 6.
Halliwell B, Gutteridge JMC. Oxygen toxicity, Oxygen radicals, transition metals and disease. *Biochem J.* 1984; 219: 1-14.
2. Books: Mann JI, Pyorala K, and Teuscher A. Diabetes in epidemiological perspective. London: Churchill Livingstone. 1983.
3. Chapter in book: Phillips SJ, and Whisnant JP. Hypertension and strock. In: Laragh JH, and Brenner BM. editors. Hypertension: Pathophysiology, diagnosis, and management. 2nd ed. NewYork: Raven Press; 1995. p. 465-78.

• **TABLES:** Each table should be typed on a separate page double-spaced, including all headings, number all tables with English numerals and include a short title. Vertical lines between columns are to be avoided.

• **FIGURES:** All figures must be suitable for reproduction without being retouched or redrawn. Figure number, name of senior author, and title of the work should be written lightly on the back with red pencil. Photographs must be supplied as glossy black and white prints. The top of the figures should be indicated clearly.

• **LEGENDS:** Captions for figures must be typed; double spaced, and must not appear on the figure.

Proof Reading will be done by the secretarial office of the journal. The principal author will receive a copy of the journal. The authors are responsible for accuracy of all statements, data, and references included in the manuscript.

- After the manuscript has been accepted for publication, authors are required to supply the final version of the manuscript on CD in MS word version 6 or later.
- All corresponding to be addressed to the Chief Editor on the address below:

Chief Editor:
Iraqi Journal of Medical Sciences
College of Medicine,
Al-Nahrain University,
P.O. Box 14222,
Tel. 5231521,
Al-Kadhiymia,
Baghdad,
IRAQ.

IRAQI JOURNAL OF MEDICAL SCIENCES

**A MEDICAL JOURNAL ENCOMPASSING ALL MEDICAL SPECIALIZATIONS
ISSUED QUARTERLY**

CONTENTS

EDITORIAL

- ❖ DEATH UNDER ANESTHESIA AND SURGICAL PROCEDURES.
Mutaz Abdulmajeed Al-Qazzaz1-2

ARTICLES

- ❖ COMPARATIVE STUDY BETWEEN CLOSE REDUCTIONS VERSUS CLOSE REDUCTION WITH K-WIRE FIXATION IN COMPLETELY DORSALLY DISPLACED DISTAL RADIAL METAPHYSEAL FRACTURE, IN CHILDREN AND ADOLESCENT.
Abd Ali Muhsin.....3-9
- ❖ ISOLATION AND PURIFICATION OF GLUCOSYLTRANSFERASE FROM MUTANS STREPTOCOCCUS SOBRINUS (SEROTYPE G) LOCAL ISOLATE.
Nada H. Al-Mudallal, Essam F. Al-Jumaily, Nidhal Abdul Muhymen , Abd Al-Wahid Al-Shaibany.....10-18
- ❖ PRE-OPERATIVE STAGING OF RENAL CELL CARCINOMA : SPIRAL CT VERSUS PATHOLOGICAL CONSIDERATIONS.
Mohammed abd kadhim , Ula Mohmmmed Ridha Al-Kawaz , Haider Abdul Hussein Ahmed.....19-27
- ❖ MEDICO-LEGAL STUDY ON NEONATAL DEATHS IN BAGHDAD.
Faik Amin Baker, Hussein Mahmood Gazi, Nabeel Ghazi Hashim.....28-33
- ❖ INDUCTION OF CARDIOMYOGENIC DIFFERENTIATION OF ADULT BONE MARROW STEM CELLS IN ALBINO RATS BY USING 5-AZACYTIDINE.
Intidhar M. Mnati34-40
- ❖ PREVALENCE OF DELIRIUM AMONG MEDICAL INPATIENTS IN TEACHING HOSPITAL IN BAGHDAD.
Uday A.J. Khalid41-46

- ❖ EVALUATION OF THE EFFECT OF ORAL VERSUS INTRAVENOUS IRON TREATMENTS ON ANEMIA IN PATIENTS WITH CHRONIC KIDNEY DISEASES.
Arif Sami Malik47-52

- ❖ POLYTHELIA: ANATOMIC AND CLINICAL IMPLICATIONS.
Mohammad O. Selman53-56

- ❖ ASSESSMENT OF COLOR ALTERATION OF HEAT POLYMERIZED RESIN BY VISUAL INSPECTION AND SPECTROPHOTOMETER AFTER IMMERSION IN CHEMICAL DENTURE CLEANSER.
Israa Mohummed Hummudi , Ala'a Ezzat Abdul Majeed57-64

- ❖ CLINICAL EVALUATION OF LOW LEVEL LASER THERAPY IN SKIN WOUND HEALING IN MAXILLOFACIAL SURGERY.
Ammar Salih Al-Alawi ,Hussain A. Jawad , Ayad M. Ismael65-70

- ❖ IDENTIFICATION OF A CLASS OF HEMOPOIETIC COLONY-FORMING CELLS FROM HUMAN UMBILICAL CORD BLOOD IN CULTURE.
Baydaa H. Mutlak71-77

Editorial:

Death under anesthesia and surgical procedures.

Mutaz Abdulmajeed Al-Qazzaz *FIBMS, BFM.*

In most countries around the world, death occurring during or within a short time after surgical operation or invasive diagnostic procedures (e.g. angiography) or under anesthesia should be referred for medico legal investigation which must include an autopsy.

Alfred A. Angrist wrote in Bulletin of the New York during 1971 “ the autopsy is the moment of truth for all medical care and the time of reckoning to improve the care of the patient.... It becomes a stimulus and incentive for better care and increases both empathy and science in medicine ...It crystallizes errors, exposes abuses and points out fads and fancies”.

The forensic pathologist in charge of such a problem should be independent of the institution in which death occurred and autopsy should never be carried out by the clinical histopathologist of that hospital.

It is always important to have the expert opinion and advice of an independent clinical consultant who works in a separate institution or hospital and who has no connection with the team involved in that incident.

Dept. Pathology and Forensic Medicine,
College of Medicine, Al-Nahrain University.
E.mail : mutazabdulmajeedq@yahoo.com

For autopsy to be informative and the report to be precise and accurate a number of steps have to be taken in to consideration:

Any surgical or anesthetic device which have been introduced to the patient in the operation theater should never be removed but retained in the body for examination of its proper placement and its patency to be checked (e.g. airways, endotracheal tubes, indwelling needled, I.V. cannulae, catheters, wound drains, chest tubes, monitoring electrodes, and metal or plastic prostheses) .Special attention to endotracheal tube and its malposition as oesophageal intubation is fatal if not corrected rapidly.

The hospital lab, where death occurred should be ordered to retain any ante-mortem blood or body fluid samples which might be needed for analysis such as blood groups in transfusion mistakes or enzyme analysis.

Full information should be provided to the forensic pathologist before stating any autopsy including the circumstances of death with a copy of the patient case sheet including its medical and surgical notes.

Discussion between the forensic pathologist, surgeon and the

anesthesiologist may sometimes leads to an acceptable conclusion to present to the court in cases where autopsy might reveal little or no valuable information.

Bernard Knight classified the cause of death under surgical intervention in to 4 categories:

1- Those directly caused by the disease or injury for which the operation or anesthetic was been carried out.

2- Those caused by a disease or abnormality other than that for which the procedure was been carried out.

3- Those resulting from an act during or a complication of the surgical or diagnostic procedure.

4- Those resulting from an act during or a complication of the anesthetic being administered.

Comparative study between close reductions versus close reduction with K-Wire fixation in completely dorsally displaced distal radial metaphyseal fracture, in children and adolescent.

Abd Ali Muhsin *FICMS*.

Abstract

Background: Distal Fracture of the radius in children-sometimes (erroneously) called 'Juvenile colles' is among the commonest sites of childhood fractures. Cases with completely dorsally displaced fracture of distal radial metaphysis were collected, evaluated, and treated with either closed reduction or closed reduction with K-wire fixation.

Objective: is to evaluate the advantage of percutaneous K-wire with cast immobilization over cast immobilization alone in management of displaced distal metaphyseal fracture in children and adolescent below 15 years with respect to maintenance of reduction and Joint Motion.

Methods: In this study 34 children all sustained completely displaced distal metaphyseal fracture of the radius were divided into two groups:

Group A consist of 16 children (10 boys and 6 girls), with a mean age 7.9 years.

Group B consist of 18 children (11 boys and 7 girls), with a mean age 8.6 years.

In both groups reduction was achieved by closed method under general anaesthesia and image intensifier and reduction was easily achieved beyond 70% of cortical contact and less than 15° of angulation.

For group A: the fracture was immobilized by complete above elbow cast. **For Group B:** the fracture was immobilized by insertion of a percutaneous K-wire across the fracture with complete above elbow pop cast. The patients (in both groups) were discharged from the hospital in the second postoperative day. The patients in

group A reviewed once weekly for the first 3-4 weeks with anteroposterior and lateral radiographs and four children (25%) of this group was complicated by redisplacement of the fracture, three of them required remanipulation under general anaesthesia, while in group B the complications rate were low regarding redisplacement and there was no need for remanipulation. These patients were reviewed every 3 weeks and X-ray exposure was low. The union rate in both groups was the same.

Results: Risk of displacement was greater in group A (25%) compared with no displacement in group B. Pin track infection in group B occur only in one case (5-6 %) regarding limitation of pronation supination and dorsiflexion (as compared with uninjured side)in both groups ; for group A wrist flexion 35°(58.3% of normal range)while pronation- supination was 40° (44.4% of normal range) for group B wrist flexion 40° (66.4% of normal range) and pronation – supination was 55°(61.1% of normal range)

Conclusion: supplementary percutaneous K – wire fixation results in better maintenance of alignment, reduces the need for follow up radiographs and the need for further procedures to correct loss of position.

Keywords: completely displaced fracture left radius, cast, K-wire.

IRAQI J MED SCI, 2010; VOL.8 (4):3-9

Introduction

Paediatric forearm and distal radius fractures are common injuries. Resultant deformities are usually a product of indirect trauma involving angular loading combined with

rotational displacement. Successful outcomes are based on restoration of adequate pronation, supination and to a lesser degree acceptable cosmeses. ⁽¹⁾

The displaced fracture may be difficult to reduce anatomically due to the interposition of stripped periosteum, muscle, interosseous membrane or tendon. There have been reports of lost reduction after closed procedure resulting in the

Dept. Surgery, College of Medicine, Al-Nahrain University.

Address Correspondence to: Dr. Abd Ali Muhsin,

E- mail: abdalimuhsin@yahoo.com

Received: 4th May 2010, Accepted: 2nd June 2010.

restriction of full extension of the digits, which necessitated open reduction⁽²⁻⁴⁾.

Satisfactory remodeling of angular deformities would occur if displacement were in the plane of joint movement⁽⁵⁾. Even complete translocation (bayonet apposition) is tolerated in a child because of remodeling potential of the periosteum. This will not occur for rotational deformities. The movements of pronation and supination will also be adversely affected by interosseous space loss, which could occur during external plaster immobilization, from early resumption of vigorous activity before stable callus is formed.

Patients and methods

This is a prospective, randomized controlled study conducted at the Department of Orthopedics' surgery, Al-Kadhimiya Teaching Hospital in the period between October 2005 and October 2006.

The study included 34 patients (aged between 4-15 years), 21 boys (61.8%) and 13 girls (38.2%) with an overall mean age 8.3 years. The right hand was involved in 19 of the cases (55.88%) and the left hand in 15 of the cases (44.12%), all had completely dorsally displaced fracture of distal radial metaphysis, 12 of the cases (35.3%) had an associated ipsilateral distal ulnar fracture, two of the patients with associated ulnar fracture required K-wire for ulnar fracture in addition to the radial fracture.

The patients excluded from the study were:

- 1- Those with open fracture.
- 2- Those with the physeal fracture.
- 3- Patients with fracture involving distal radial epiphysis.
- 4- Those with irreducible fracture (need open reduction and internal fixation)

5- Patients presented more than 10 days after injury.

6- Patients with associated fractures other than distal ulna like; patient with fracture radial neck, supracondylar fracture, and fracture clavicle.

Standard anteroposterior and lateral X-ray views; including the whole forearm and elbow joint, were obtained for all patients.

All patients were treated initially by applying plaster back slab from above the elbow to the metacarpals necks with an arm sling and elevation for the first 5-7 days to decrease swelling and to have adequate time to prepare the patient for general anaesthesia.

The patients were divided into two groups:-

- *Group A* consist of 16 patients (10 boys and 6 girls), with a mean age 7.9 years. Three cases of those patients had an associated fracture of distal ulna.
- *Group B* consists of 18 patients (11 boys and 7 girls) with a mean age 8.6 years. Nine cases of those patients had an associated fracture of distal ulna.

Follow up

Patients of group A were assessed weekly for first 4 weeks with anteroposterior and lateral radiographs to evaluate the maintenance of reduction.

Patients of group B reviewed after 3 weeks for radiographic evaluation, removal of K-wire, and changing the cast.

In both groups the cast was removed at 6 weeks, the patients were assessed at the twelfth week both clinically, and radiographically, joints motions were assessed by Goniometer.

Removal of K-wire was easily done during routine outpatient clinic visit.

In both groups the fractures were reduced:

1. under general anaesthesia with screen monitoring,
2. Applying traction through the band in the line of the length of forearm with counter traction by assistant through the proximal forearm for about few seconds for relaxation of the muscle,
3. Applying an extension force with traction for the distal fragment for disimpaction ,
4. The distal fragment was then pushed into place by pressing on its dorsum with the thumb ,
5. Manipulating the wrist into flexion, ulnar deviation, and pronation.
6. Reduction was then checked by fluoroscopy.

Reduction aimed at more than 70% of opposition at fracture site with less than 15° of angulation. No rotation was permitted

For group A; a complete plaster cast extending from above the elbow to the metacarpal heads was applied with wrist in 20° flexion and forearm in neutral rotation (midway between pronation and supination) for relaxation of deforming muscles.

For group B; after reduction a smooth K-wire was introduced either from

1. Radial styloid process, when the fracture was more distal, after passing

through the fracture the wire directed to the opposite cortex of the radius or;
2. Lister's tubercle, when the fracture was more proximal, then the wire directed toward the medulla.

For fracture of the ulna; which needed a K-wire fixation, the wire was introduced through the head of the ulna and directed toward the medulla.

After insertions the K- wire, the wire bent and sterile gauze was applied over the entry point and a complete above elbow cast was applied with forearm and wrist in neutral position.

Results

There were 21 boys (61.8%) and 13 girls (38.2%) with male to female ratio 1.6: 1. The right hand involved in 19 of the cases (55.88%), the left hand is involved in 15 of the cases (44.12%).

❖ 19 cases (55.88%) ; 13 boys and 6 girls, where recorded in 5-9 years age group, where as children under 5 years account for 3 cases (8.82%) of these one boy and two girls. The children between 9-15 years account for 12 cases (35.3%) of these 7 boys and 5 girls . the results are summarized in the following tables and figures:

Table 1: Age and sex distribution

Age	No. of children	Percentage %	Male	Female
Under 5 years	3	8.82	1	2
5-9	19	55.88	13	6
9-15	12	35.3	7	5
total	34	100	21	13

Table 2: Group classification and mode of treatment

Patients group	No. of patient			Mean age ""	Method of treatment
	total	male	female		
Group A	16	10	6	7.9	MUA+Plaster Cast
Group B	18	11	7	8.3	MUA+K- wire+Cast

Table 3: The incidence of redisplacement in Group A

Sex	No.of patient	% of patient from Group A	Mean age	Time
Male	3	18.75	8.6	2nd -3rd week
Female	1	6.25	11.6	2nd week

Table 4: Outcome

Parameters	Closed reduction and cast	Closed reduction C with K-wire and cast
No. of patients	16	18
Mean age	7.9	8.6
Type of plaster	Complete p.o.p	Complete p.o.p
No. of plaster application within 6 weeks	3 occasions	2 occasions
No. of x-ray exposure at 12weeks	3-4 occasions	2 occasions
Union rate	Within 6 weeks	Within 6 weeks

Table 5: Complications

Parameter	Group A	Group B
Redisplacement	4 (25%)	Nil
Pin track infection	-	1 (5.6%)
Pronation/supination	40° (44.4% of normal range)	55°(61.1°/0 of normal range)
Wrist flexion	35° (58.3% of normal range)	40°(66.7% of normal range)

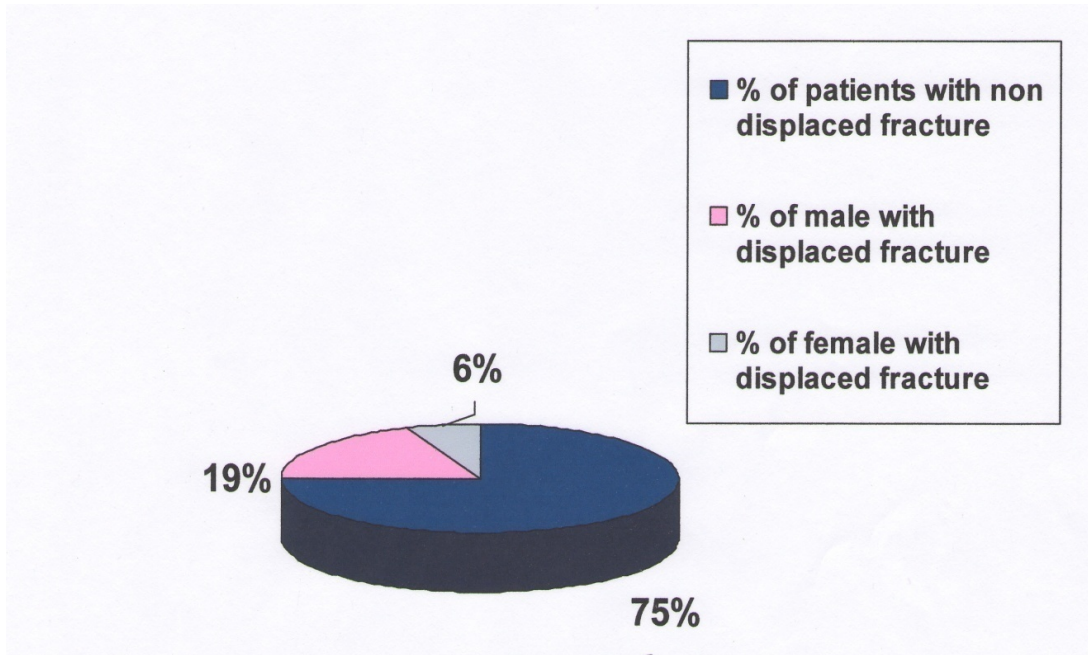


Figure 1: The percentage of displaced fracture among male and female of group A

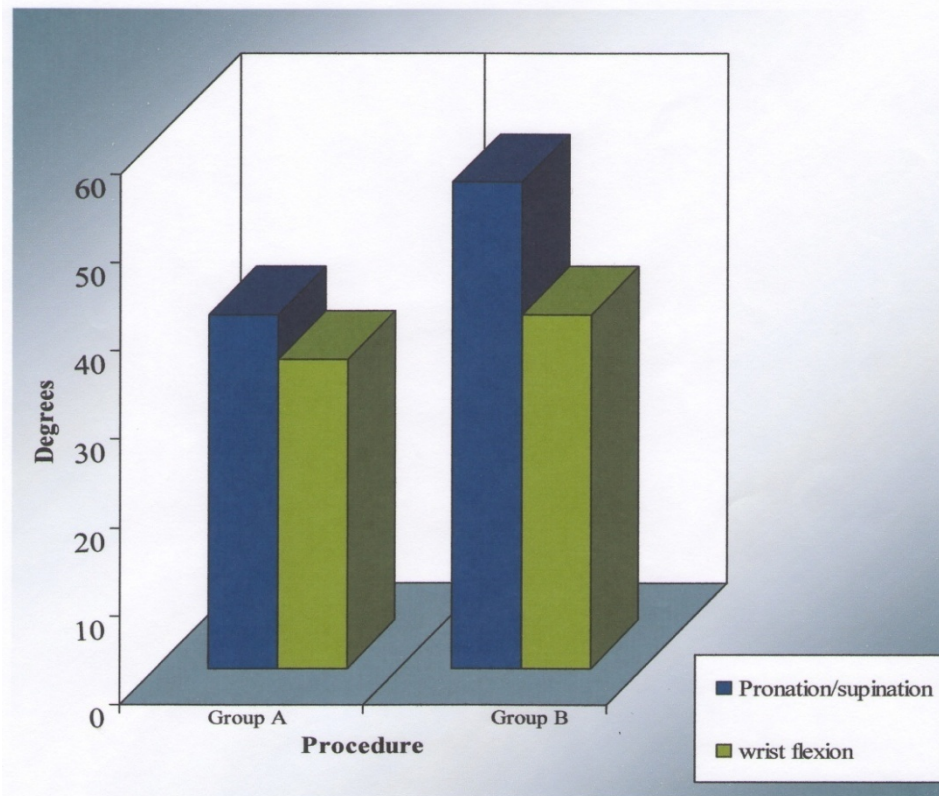


Figure 2: Range of joint motion at 12 weeks

Discussion

Distal metaphyseal fracture of the radius is among the commonest fractures in children, completely displaced fracture may be difficult to reduce or to maintain reduced after close reduction.

Management by external casting alone may be inadequate because of the difficulty in maintaining alignment.

The need for adequate alignment is important for forearm pronation/supination, fingers flexion and extension and for better cosmesis.

Although a reduction of 50% or more is desirable for adequate remodeling to occur with growth, some of these fractures may unite with rotation and malalignment due to loss of reduction during period of immobilization as trauma edema resolve^(5,9).

Closed reduction and percutaneous K-wire fixation decrease the incidence of these complications.

Arguments abound for and against K-wire fixation that cross the distal radial epiphysis and physis^(8,10).

The possibility of subsequent growth delay has been highlighted. No such complications among these patients were recorded probably due to short term follow up (12weeks), Smooth K-wire was used to avoid this complication^(6,7).

The K-wire fixation is a versatile technique for osseous fixation, though it provides stabilizations rather than rigidity. It avoids the open surgery, frequent displacement in plaster cast fixation and the need for plaster re-application, the removal of the K-wire is easily done during routine out patient clinic visit.

The procedures require the experienced assistant as the reduced fracture should be held in place during pin insertion. The outcome is often a direct function of initial reduction obtained.

Group A (mean age 7.9 years) was treated by closed reduction and casting alone, the redisplacement was significant (25 %) during 2nd-3rd weeks.

In group B (mean age 8.6 years) it was found expedient to insert percutaneous K-wires ,because the stability after reduction was unreliable at time of reduction and during plaster immobilization for reasons as resolution of traumatic edema ,muscle action on fracture fragment and greater activity of these children.

The complications rate was low in this study most were recorded in Group A. Redisplacement occur in 25 % of children in this group during the second – third week of plaster immobilization, reduction of pronation and supination was greater in group A, which was 40° (44.4 % of normal range) compared to 55° (61.1 % of normal range) in group B at 12 weeks .wrist flexion also reduced to about 35° (58.3 % of normal range)in group A compared with 40°(66.7% of normal range) in group B at 12 weeks. The difference in wrist range of motion between group A and group B may be related to wrist flexion position in which patients in group A were held compared with neutral position in group B. (these readings were measured in comparison with the normal side).

A complete plaster cast was used in both groups to ensure uniformity between the two groups.

The K-wire fixation of completely displaced fractures of distal radius was found to be effective in preventing subsequent loss of position and complications from the use of K-wire are generally minor.

Infrequent visits and fewer radiographs were required in K-wire group during the follow up.

It could be concluded that completely dorsally displaced fracture of the distal radial metaphysis in children have a high propensity for redisplacement, despite satisfactory initial reduction.

Supplementary percutaneous k-wire fixation resulted in a significantly better maintenance of the alignment of the fracture. It was safe and reduces the need for follow up radiographs. It reduces the need for further procedures to correct loss of position. No detrimental effect on the outcome.

distal radius treated by percutaneous wire fixation. 1981. in chapchal O. Ed. Fractures in children. Thieme-Stratton.

References

1. Noonan MD, Charles T Price; forearm and distal radius fracture in children; Journal of American Academy of Orthopaedics Surgery 1998;6- 146-156 .
2. Ghazi MR and Hayes M. Entrapment of the flexor digitorum profundus in the ulna, with fractures of both bones of the forearm. J. Bone Joint Surg. 1990, 68A: 1102-1 103.
3. Voto SJ, Weiner DS, Leighley RN. Redisplacement after closed reduction of forearm fractures in children. J. Pediatr. Orthop. 1990, 10: 79-84.
4. Fatti JF and Mosher JF. An unusual complication of fracture of both bones of the forearm in a child. J. Bone Joint Surg. 1980, 68A: 3, Mar. 451-453.
5. Nelson AB and Simonsen D. Displaced forearm fractures in children treated with plates. Injury 1986, 15: 393.
6. Money BF, Askew Lj, An KN, Chao EY. A biomechanical study of non-nal functional elbow motion. I Bone joint Surg Am 1981; 63:872877.
7. Evans EM. Fractures of the radius and ulna. I Bone Joint Surg Br 1951;33: 548-561.
8. Davis DR, Green DP. Forearm fractures in children: Pitfalls and complications. Clin Orthop 1976; 120:172-184.
9. Voto SJ, Weiner DS, Leighley RN. Use of pins and plaster in the treatment of unstable paediatric forearm fractures. 1. Paediatr. Orthop. 1990, 10:85.
10. Muller J, Roth B, and Willenegger H. long term results of epiphyseal fractures to the

Isolation and Purification of glucosyltransferase from mutans *Streptococcus Sobrinus*(serotype G) local isolate.

Nada H. Al-Mudallal¹ PhD, Essam F. Al-Jumaily² PhD, Nidhal Abdul Muhymen³ PhD, Abd Al-Wahid Al-Shaibany¹ PhD.

Abstract

Background: Glucosyltransferase is an extracellular enzyme produced by mutans streptococci responsible for polymerizing the glucose moiety of sucrose to form glucan.

Objective: Isolation and purification of glucosyltransferase from mutans *Streptococcus sobrinus*.

Methods: The enzyme was purified from mutans *Streptococcus sobrinus* by ultrafiltration, adsorption chromatography, ion-exchange by DEAE-cellulose and gel filtration by Sephacryl S-200.

Results: Large scale production, concentration and purification of mutans streptococci (*S.sobrinus*) (serotype G) N₁₀ glucosyltransferase (GTF) were done by ultrafiltration-method using an Amicon-filter P50, adsorption chromatography (hydroxyapatite beads), ion-exchange chromatography (DEAE-cellulose column) and gel-filtration chromatography using (Sephacryl S-200)

column. Three purified GTF enzymes (GTF-I_a, GTF-I_b, GTF-II) were detected with a specific activity of (31.60; 31.50 and 66.270) Unit/mg protein respectively and the fold of purification are (27.59; 27.92 and 58.75 respectively with yield of enzymes (14; 10.94 and 17.11 %) respectively.

Conclusion: The purified enzyme with accepted yield may open new approaches for its using in oral passive immunization against dental caries in experimental animals by using hen egg yolk antibodies specific for cell associated GTF of mutans streptococci bacteria.

Keywords: glucosyltransferase, *Streptococcus sobrinus*, purification, adsorption chromatography.

IRAQI J MED SCI, 2010; VOL.8 (4):10-18

Introduction

Glucosyltransferase is an extracellular enzyme produced by mutans streptococci responsible for polymerizing the glucose moiety of sucrose to form glucan which plays an important role in caries formation process^(1, 2). Several methods have been used for purification of mutans streptococci GTF enzyme. Challacombe⁽³⁾ purified glucosyltransferase (GTF) enzyme from culture fluid of *S. mutans* by the use of hydroxyapatite column

chromatography. Stepwise elution in 0.2 M and 0.5 M phosphate buffer resulted in two pools of activity as determined by isoelectrical focusing of this preparation revealed it to be a mixture of at least seven GTFs.

Other purification procedures were made from 20L culture supernatant of *S. mutans* by filtration through different ultrafiltration membranes in an Amicon Ultrafiltration cells in order to concentrate the enzyme and to remove any contaminating D-glucan. Polyacrylamide gel electrophoresis was used in order to quantitate the enzyme activity and the degree of purification⁽⁴⁻⁶⁾.

Taubman⁽⁷⁾ purified two types of GTF enzymes from *S. sobrinus* using SDS-PAGE and named them GTF-I and GTF-S with molecular weights of 153 KDa and 148 KDa, respectively. Purification procedures were

¹Dept. Biotechnology, College of Science, Al-Nahrain University, ² Genetic Engineering and Biotechnology Institute for postgraduate studies, Baghdad University, ³ Dept. Microbiology, College of Medicine, Al-Nahrain University

Address Correspondence to: Dr. Essam F. Al-Jumaily.

E- mail: Samgen992003@yahoo.com

Received: 17th 2009, Accepted: 30th August 2009.

performed by Sephadex G-100 column, Sepharose 4B-CL, and then the two enzymes were separated on a column of DEAE-Bio gel A as two peaks.

Purification of *S. sobrinus* GTF enzymes was also done from culture supernatant of this bacterium by chromatography on Sephadex G-100. The GTF-rich pools were then subjected to fast protein liquid chromatography on Superose 6. The gel filtration step separates non-GTF and other glucan-binding proteins as demonstrated by (SDS-PAGE). *S. sobrinus* GTF preparation obtained after gel filtration on Superose 6 contained a mixture of water (GTF-I)-insoluble glucan product [IG], (GTF-U) primer stimulated soluble glucan [SG] product and (GTF-S) primer independent SG-product^(8,9).

Methods

Bacterial local isolate *S. sobrinus* (serotype G) N10 which was isolated and identified as GTF producers isolate by Al-Mudallal⁽¹⁰⁾ was grown on the surface of blood agar medium and incubated anaerobically at 37°C for 48 hrs.

A (2.5 ml) of this stock culture was inoculated into (250 ml) Todd-Hewitt broth medium containing (1.8%) glucose and incubated anaerobically for 18-24 hrs at 37°C⁽¹¹⁾.

Determination of GTF activity

The amount of glucan produced by GTF was estimated following the method of phenol-sulfuric acid by Debois⁽¹³⁾.

The protein concentration was estimated in the supernatant by Bradford⁽¹²⁾.

Extraction of GTF

Large scale production of GTF was done from the chosen bacterial isolate after growing in (750ml) Todd-Hewitt broth medium. Total viable count was determined for the stock bacterial culture (O.D. =0.25) by

making a serial dilutions of the bacterial growth (10^{-1} - 10^{-6}). After the extraction of GTF from bacterial culture was done the GTF activity and protein concentration as well as specific activity were calculated in (10 ml) of bacterial suspension.

The producible crude GTF was passed through an Amicon-filter P50 in (Ultrafiltration-cell) and concentrated to (40 ml). GTF activity and protein concentration then specific activity were also determined in (10 ml) of the concentrated suspension.

Purification of GTF by Adsorption Chromatography

The purification of GTF was done by using adsorption chromatography using hydroxyapatite beads which was prepared and packed with the enzyme according the manufacturing company (Bio-Rad-USA) and following the batch-wise method described by Scopes⁽¹⁴⁾. The 40 ml of crude concentrated GTF enzyme were added at (5°C) with a gentle stirring and left for a time to adsorb the enzyme with the beads. This mixture was then transferred to an Amicon-filter P50 in (Ultrafiltration-cell) and filtrated under pressure. To the remaining precipitates on the filter washing was made by the addition of 25 ml of 0.15M phosphate buffer pH 7.5 and fractions of 5 ml were collected from the out-part of the filter. Then 25 ml of 0.3M phosphate buffer pH 7.5 were used to elute the protein from the remaining precipitate on the filter then fractions of 5 ml were collected.

The presence of GTF was estimated by measuring GTF activity for all fractions which represented the washing and elution parts then after collection of active GTF fractions together, protein concentration, GTF activity and specific activity were determined.

The exchanger DEAE-cellulose was prepared and packed into a

column (7.5 x 3.5 cm) following the method described by Whitaker⁽¹⁵⁾.

Partially purified concentrated GTFs 12 ml were separately passed after loaded onto the column carefully. Then 100 ml of 0.05M phosphate buffer pH 7.5 were added. Proteins were eluted by using 200 ml of a gradient from 0.05-0.3 M phosphate buffer pH 7.5. Fractions of 5 ml were collected and absorbency was monitored at 280 nm. The presences of the GTFs was estimated from each fraction of the major peaks then protein concentration and specific activities were determined.

To Sephacryl S-200 column (67x2.1cm), a 3 ml sample of each concentrated partially purified GTFs were added to the column, Elutions of proteins were done with the application of 200 ml of 0.3 M phosphate buffer pH 7.5. A 5 ml fraction was collected and the absorbency was monitored at 280 nm.

Different standard proteins (Thyroglobulin, ferritin, catalase, aldolase, bovine serum albumin with molecular weight 660000,440000, 230000, 158000 and 67000 respectively were applied through Sephacryl S-200.

Results

Before the purification process, large scale production of GTFs was done from mutans streptococci (*S.sobrinus*) N₁₀ bacteria chosen isolate. After extraction of GTF, protein concentration, GTFs activity then specific activity were determined in 10 ml of bacterial suspension. Results showed that bacteria about 1×10^8 cells/ml were able to produce 0.7 mg/ml of crude GTFs with an activity of 0.790 U/ml which had a specific activity of 1.128 U/mg protein after 1 fold of purification, when 750ml crude GTFs concentrated by an Amicon-filter P50 in Ultrafiltration-cell to 40ml. Table 1 indicates that

protein concentration and GTFs activity were recorded to be 0.601 mg/ml and 11.076 U/ml with a specific activity of 18.42 U/mg protein after 16.32 folds of purification which represented 74.77% yield of enzyme.

Purification of GTFs was done by Adsorption chromatography using hydroxyapatite beads. Results showed that when washing with 25 ml of 0.15 M phosphate buffer pH 7.5 then elution with 0.3M of the same buffer, GTFs activity appeared in all fractions of the washing and elution parts. The collection of fractions of the washing part as well as for fractions of the elution part in separated sterile containers was done. GTFs activity, protein concentration and specific activity which were determined for these separated parts. Table 1 indicates that washing with 0.15M phosphate buffer produced a GTF-I activity of 6.699 U/ml, with a specific activity of 18.66 U/mg protein after 16.54 folds of purification which represented 28.265% yield of enzyme. The elution with 0.3M phosphate buffer produced a GTF-II activity of 6.922 U/ml, protein concentration of 0.365 mg/ml and a specific activity of 18.96 U/mg proteins after 16.80 folds of purification which represented 29.206 % yield of enzyme.

Accordingly,adsorption chromatography (hydroxyapatite beads) is capable to produce two GTF enzymes with very close activity and protein concentration values. These two enzymes were named GTF-I and GTF-II. GTF-I represented the collection of fractions after washing and GTF-II represented the collection of fractions after elution. Purification of GTF enzymes (GTF-I and GTF-II) were done by ion-exchange chromatography (DEAE-cellulose column). 12ml of the concentrated samples from the previous step (GTF-I and GTF-II) were passed separately through the

DEAE cellulose column. Results shown in figures (1) and (2) indicate that washing with 100 ml of 0.05M phosphate buffer pH 7.5 allowed the presence of two peaks which were represented by fractions 9-16 for GTF-I and fractions 11-20 for GTF-II. Then after elution of proteins with 200 ml of a gradient from 0.05M to 0.3M phosphate buffer pH 7.5, two peaks were obtained for GTF-I which were

represented by fractions 20-26 and 32-38 and one peak was obtained for GTF-II represented by fractions 47-52. Each fraction of GTF-I and GTF-II which represented the peaks after washing and elution processes were tested for GTF activity. Accordingly, only fractions 20-26 and 32-38 of GTF-I and fractions 47-52 of GTF-II were able to reflect GTF activity.

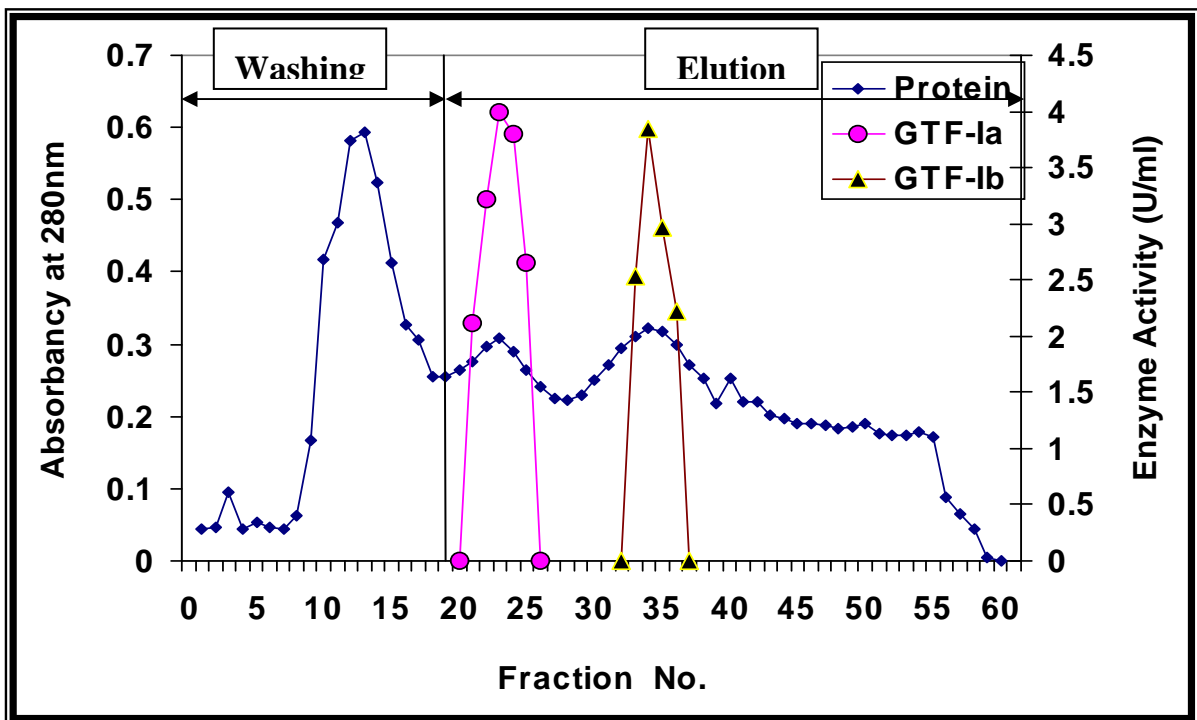


Figure 1: Purification of GTF-I enzyme by ion exchange chromatography (DEAE-Cellulose) column (7.5x3.5cm). The column was washed by using (0.05M) phosphate buffer pH (7.5), and then eluted by using a gradient of (0.05M) to (0.3M) phosphate buffer pH (7.5).

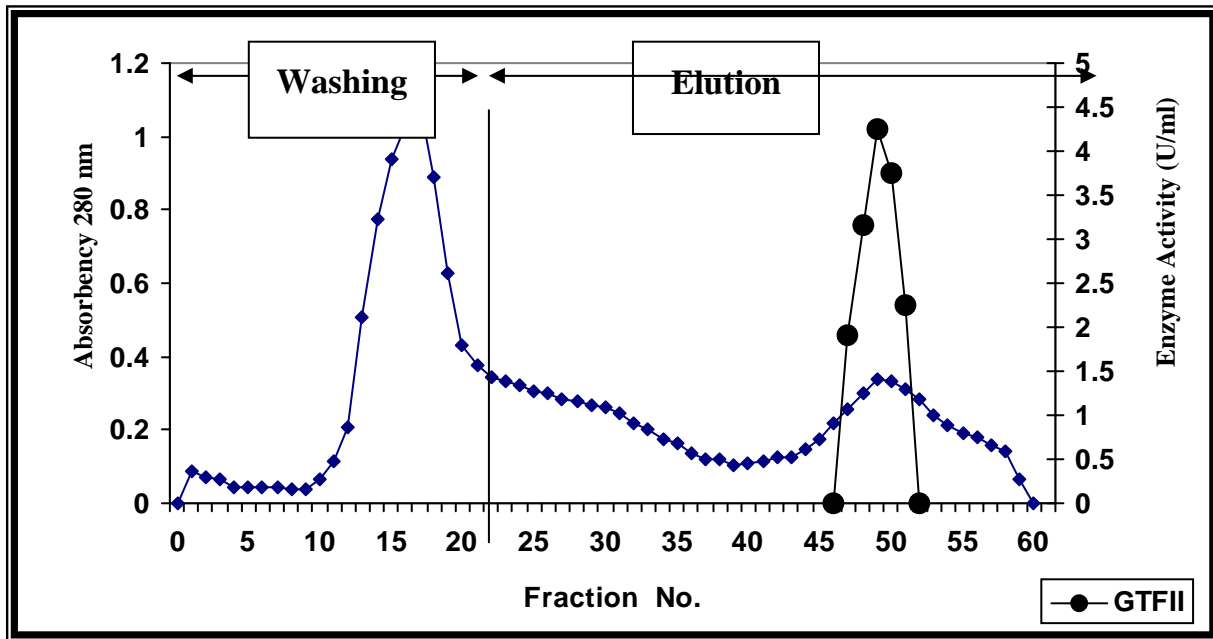


Figure 2: Purification of GTFII enzyme by ion exchange chromatography (DEAE-Cellulose) column (7.5x3.5cm).The column was washed by using (0.05M) phosphate buffer pH (7.5), and then eluted by using a gradient of (0.05M) to (0.3M) phosphate buffer pH (7.5).

Table (1), indicates that specific activities of (17.52 U/mg protein), 22.464 U/mg protein with purification folds of 15.53, 19.91 and yield of 15.088%, 13.269% were obtained respectively for GTF-I_a and GTF-I_b. For GTF-II a specific activity of (26.88 U/mg protein) was obtained with purification folds of 23.82 and yield of GTF of 17.353%.

Accordingly, three GTF enzymes (GTF-I_a, GTF-I_b and GTF-II) were obtained after purification with ion-exchange chromatography. Partially purified (GTF-I_a, GTF-I_b and GTF-II) were passed separately through an Amicon-Filter P50 in (Ultrafiltration-Cell) to concentrate them to (5 ml).

Figures 3, 4 and 5 indicate the presence of six peaks (two for GTF-I_a, three for GTF-I_b and one for GTF-II) . After the determination of GTF

activity for all these peaks it is clear that fractions (30-33) of GTF-I_a, Fractions (32-36) of GTF-I_b and fractions (25-28) of GTF-II were able to produce GTF enzyme. Fractions (30-33) of GTF-I_a, fractions (32-36) of GTF-I_b and fractions (25-28) of GTF-II were pooled separately for each enzyme then GTF activity, protein concentration and specific activity were determined.

Results shown in table (1), indicate that GTF-I_a, GTF-I_b and GTF-II were able to reflect GTF activity, and specific activity of (5.531 U/ml), (4.320 U/ml), (6.760 U/ml); (31.60 U/mg protein), (31.50 U/mg protein), (66.270 U/mg protein) after (27.59), (27.92), (58.75) folds of purification and yield of 14.001%, 10.936% and 17.113% respectively.

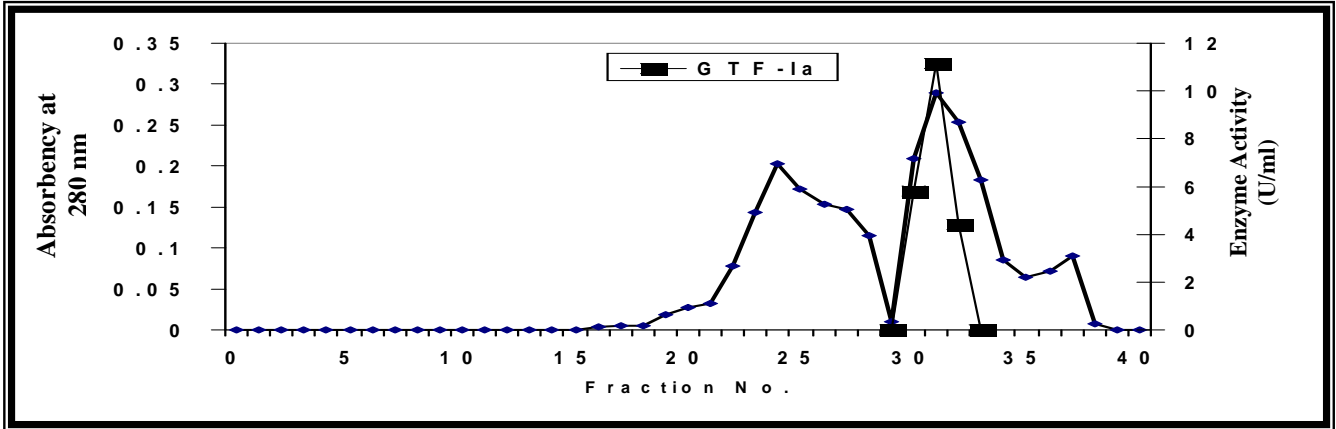


Figure 3: Purification of GTF-I_a by gel-filtration chromatography (Sephacryl S-200) column (67x2.1cm). Eluent: (0.3M) phosphate buffer pH (7.5) at a flow rate of (50ml/hour).

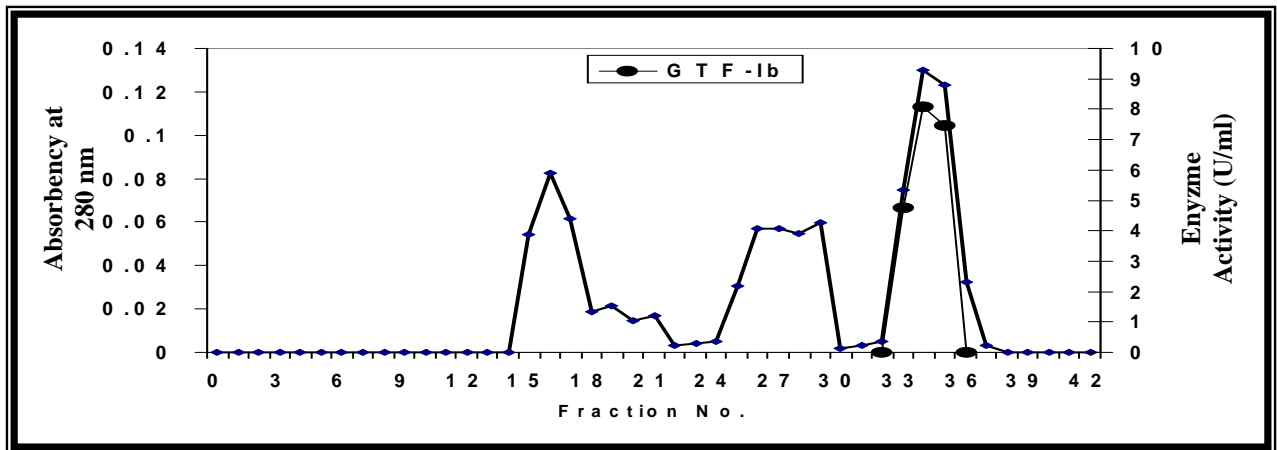


Figure 4: Gel filtration column chromatography (Sephacryl S-200) of GTF-I_b (67x2.1cm). Eluent: (0.3M) phosphate buffer pH (7.5) at a flow rate of (50ml/hour).

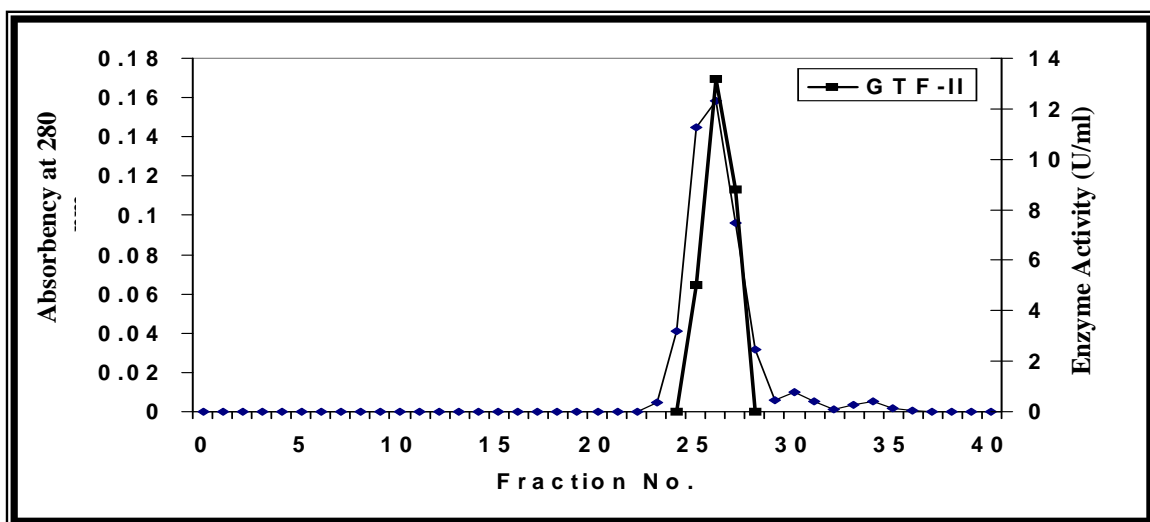


Figure 5: Purification of GTF-II enzyme by gel-filtration chromatography (Sephacryl S-200) column (67x2.1cm).

Table 1: Purification and yield of GTF enzymes from mutans streptococci (N₁₀) (*S. sobrinus*) (serotype G).

Steps	Volume (ml)	Enzyme activity (U/ml)	Total activity (U)	Protein Concen. mg/ml	Specific activity (U/mg)	Purification factor (fold)	Yield (%)
Crude Enzyme	750	0.790	592.50	0.7	1.128	1	100
Concentrated crude GTF by Amicon Filter	40	11.076	443.05	0.601	18.42	16.32	74.77
Adsorption chromatography hydroxyapatite beads (Batch wise)							
GTF-I	25	6.699	167.475	0.359	18.66	16.54	28.265
GTF-II	25	6.922	173.05	0.365	18.96	16.80	29.206
DEAE-Cellulose column chromatography							
GTF-I _a	25	3.576	89.40	0.204	17.52	15.53	15.088
GTF-I _b	20	3.931	78.62	0.175	22.46	19.91	13.269
GTF-II	25	4.113	102.82	0.153	26.88	23.82	17.353
Gel-filtration Sepharacryl S-200 column chromatography							
GTF-I _a	15	5.531	82.96	0.175	31.60	27.59	14.001
GTF-I _b	15	4.320	64.80	0.137	31.50	27.92	10.936
GTF-II	15	6.760	101.40	0.102	66.27	58.75	17.113

Discussion

Figures and Edwards⁽¹⁶⁾ concentrated their GTF from three liters bacterial culture (*S. mutans*) by using an Amicon "on-line" column effluent-concentration (Amicon-module (ECI) equipped with a PMI10 Ultrafiltration membrane). After concentration to (60 ml), protein concentration, GTF activity and specific activity were (0.660 mg/ml), (4 U/ml) and (12 U/mg protein) respectively.

Al-Hayali⁽¹⁷⁾ began the purification procedure of GTF of mutans streptococci (Biotype I-*S. mutans*) and mutans streptococci (Biotype IV-*S. sobrinus*) with precipitation by saturated ammonium sulfate from (450 ml) and (400 ml) respectively. After precipitation, GTF

activity and specific activity values for each were recorded to be 0.315 U/ml; 0.406 U/ml; 0.16 U/mg proteins and 0.15 U/mg protein respectively. Three types of GTF were obtained after the purification step by gel-filtration chromatography using (Sepharose CL-6B). The purification scheme of this step for the third GTF reflected GTF activity, protein concentration and specific activity of 0.208 U/ml, 0.09 mg/ml and 2.3 U/mg protein after 153.3 folds of purification with yield of 20.8% respectively.

Koga⁽¹⁸⁾ purified GTF of mutans streptococci (*S. sobrinus*) (serotype D) by hydroxyapatite column after precipitation with 50% saturated ammonium sulfate. GTFase-S and GTFase-I were separated with specific

activities of 3.7 U/mg protein and 1.8 U/mg protein respectively.

Yamashita ⁽¹⁹⁾ described the purification of four glucosyltransferase from mutans streptococci (*S. sobrinus*) (serotype G) by DEAE-cellulose chromatography. GTF fractions were collected from the first DEAE-cellulose each separately and entered to the second DEAE-cellulose column. The specific activity, fold of purification and yield (%) for [P₂] (one kind of glucosyltransferase enzymes) after the first and second DEAE-cellulose were recorded to be 2.39 U/mg protein, 8.35 U/mg protein; 8.54 and 29.8 folds of purification with 43.6% , 27.0% yields of GTF respectively.

Turchi and Edwards ⁽²⁰⁾ characterized and purified GTF from *S. mutans* (serotype C). The last step in the purification procedure was Gel-filtration chromatography with the use of Bio-Gel A1.5cm. The purification scheme described the presence of three GTF enzyme with specific activity were recorded to be 37 U/mg protein, 208 U/mg protein, 178 U/mg protein after 25 , 140 and 120 folds of purification with of yield of 50%.

According to the specific activities, fold of purification and yields of enzyme purification of GTF by gel filtration chromatography using (Sephacryl- S-200) column is more efficient than purification by (Sephacryl CL-6B) and less efficient than purification by (Bio-Gel A1.5 cm).

References

1. Tsumori M and Kuramitsu H. The role of *Streptococcus mutans* glucosyltransferase in the sucrose dependent attachment to smooth surfaces: essential role of the GTF-C enzyme. Oral microb. Immun. (1997) 12: 274.
2. Wunder D E and Bowen W H. Action of agents on glucosyltransferase from *Streptococcus mutans* in solution and adsorbed to experimental pellicle. Arch. Oral Biol. 1999; 44: 203-214.

3. Challacombe S J, Guggenheim B and Lehner T. Antibodies to an extract of *Streptococcus mutans* containing glucosyltransferase activity, related to dental caries in man. Arch. Oral Biol. 1973; 18:657-668
4. Ciardi J E, Beaman A J and Wiltenberger C L. Purification, resolution and interaction of the glucosyltransferase of *Streptococcus mutans* 6715. Infect. Immun. 1977; 18(1): 237-246.
5. Figures W R and Edwards J R. Improved purification procedure for the extracellular D-Glucosyltransferase from *Streptococcus mutans*. 6715. Carbohy. (1978). Res.30:248-251.
6. Smith D J, Taubman M A and Ebersole J L. Preparation of glucosyltransferase from *Streptococcus mutans* by elution from water-insoluble polysaccharide with a dissociating solvent. Infect. Immun. (1979). 23: 446-452.
7. Taubman M A, Smith D J, King W F, Eastcott J W, Bergey E J. and Levine M J. Immune properties of glucosyltransferases from *S. sobrinus*. J. Oral. Path. 1988; 17: 466-470.
8. Taubman M A, Smith D J, Holmberg C J and Eastcott J W. Coimmunization with complementary glucosyltransferase peptides results in enhanced immunogenicity and protection against dental caries. Infect. Immun. 2000; 68: 2698-2703.
9. Smith D J, Barnes L A, King W F, Peacock Z, Wise D L, Trantolo D J. et al. Remote glucosyltransferase microparticle vaccine delivery induces protective immunity in the oral cavity. Oral Microbiol. and Immunol. 2003; 18: 240-248.
10. Al-Mudallal N H. Characterization of Glucosyltransferase of Mutans *Streptococci Streptococcus sobrinus* (Serotype G) functional and immunological assessment. PhD. Thesis. College of Science, Al-Nahrain University (2006).
11. Christine D, Yuan-Wu Tai, S and Slade H D. Properties of *Streptococcus mutans* grown in a synthetic medium. Binding of glucosyltransferase and *in vitro* adherence, and binding of dextran / glucan, glycoprotein and agglutination. 1979; 23(3): 600-608.
12. Bradford M M. A rapid and sensitive method for the quantitation of microorganism's protein utilizing the principle of protein-dye binding. Analytical Bioch. 1976; 72: 248-254.
13. Dubois M, Gilles K A, Hamilton J K, Rebers P A and Smith F. Colorimetric method for determination of sugars and related substances. Anal. Chem. 1956; 28: 350-356.
14. Scopes R K. Inorganic adsorbents. In: Protein Purification Principles and Practice. 2nd

ed. SpringoVerlag. (1972). New York. PP. 675-678.

15. Whitaker J R. Principles of enzymology for the Food Science. Mocal Dekker, Inc. New York (1972).

16. Figures W R and Edwards J R. D-glucosyltransferase of *Streptococcus mutans*, Isolation of two forms of the enzyme that bind to insoluble dextran. Carbohydrate. (1981). Res. 88: 107-117.

17. Al-Hayali A M. Isolation and purification of gluosyltransferase from mutans streptococci and the relation to dental caries, dental plaque and parameters of saliva. Ph.D. (2002). Thesis, College of Dentistry, University of Baghdad.

18. Koga T, Sato S, Tnoue M, Takeuchi K, Furuta T and Hamada S. Role of primers in glucan synthesis by gluosyltransferases from *Streptococcus mutans* strain OMZ 176. J. Gene. Micorbio. (1982). 129: 751-754.

19. Yamashita Y, Hanada N and Takehara T. Purification of a forth glucosyltransferase from *Streptococcus sobrinus*. J. of Bact. (1989). 171(11): 6265-6270.

20. Turchi S L and Edwards J R. Characteristics of glucosyltransferase from cultures of *Streptococcus mutans* 6715 grown in Trypticase soy broth and chemically defined media. Curr. Microbiol. (1985); 12: 135-140.

Pre-operative staging of renal cell carcinoma: Spiral CT versus pathological considerations.

Mohammed abd kadhim *MBChB; FIBMS*, Ula Mohmmmed Ridha Al-Kawaz *MBChB; FIBMS; FEBU*, Haider Abdul Hussein Ahmed *MBChB, FIBMS*.

Abstract

Background: Renal cell carcinoma (RCC) is the commonest renal malignancy, comprising 85-90% of all malignant renal tumours and represents 3% of all adult malignancies. The prognosis of RCC depends on the size, stage, and grade of the tumor. CT has proved to be the most important imaging technique for the evaluation of renal lesions and the preoperative staging of renal cell carcinomas.

Objective: The aim of our study was to evaluate the accuracy of spiral CT in the preoperative assessment of patients with renal cell carcinoma correlated with histopathological findings.

Patients and methods: Between February 2008 and September 2009, a prospective study included 40 patients (age range, 36–66 years; 28 men, 12 women) with solid renal masses. All the patients were diagnosed by CT as having renal cell carcinoma, underwent total nephrectomy & proved to be renal cell carcinoma at histopathological examination. In all patients, initial CT images were obtained without administration of contrast Material, 100ml of Intravenous contrast material was administered, a repeated scan was done 120 seconds after contrast injection, both scans should covered the entire volume of the abdomen. Percentage of the parameters used in the study was calculated. Diagnostic accuracy of CT in staging renal cell carcinoma was calculated.

Results: The study included 40 patients (28 men, 12 women) with solid renal masses.

Tumor size ranged from 1.7 to 6.5 cm (mean size, 3.1 cm). All the patients showed evidence of contrast enhancement by about 47HU. Thirty seven patients (92.5%) show heterogeneous enhancement while only 3 patients (7.5%) show homogenous enhancement. Calcification was seen in 10 patients (25%). A pseudocapsule was present in 16 patients. Lymph node (LN) involvement with adenopathies larger than 1 cm in diameter was found in 7 patients (17.5%), only one patient (2.5%) show false negative diagnosis, the over all diagnostic accuracy of LN detection was 83%. Renal vein or inferior vena cava thrombosis was detected in 8 patients (20%), diagnostic accuracy was 87.5%. The overall diagnostic accuracy of CT in staging renal cell carcinoma was 90% (36 out of 40).

Conclusions: CT is an excellent imaging technique for the evaluation of solid renal masses and the preoperative staging of renal cell carcinomas. CT has some difficulty in differentiating T3a from T2. CT has a limited ability to identify lymph node involvement by malignancy because it is still based on only size criteria, with 10 mm as the limiting size for normal nodes.

Keywords: Spiral CT, pre-operative staging, renal cell carcinoma.

IRAQI J MED SCI, 2010; VOL.8 (4):19-27

Introduction

Renal cell carcinoma is the commonest renal malignancy, comprising 85-90% of all malignant renal tumours and represents 3% of all adult malignancies⁽¹⁻⁵⁾.

Dept. Surgery, College of Medicine, Al-Nahrain University, Al-Kadhimiya teaching hospital.

Address Correspondence to: Dr. Mohammed abd kadhim

E- mail: Dr_a_mohammed@yahoo.com

Received: 22nd November 2009, Accepted: 6th June 2010

It occurs bilaterally in 2–5% of cases^(1, 6, 7), and is the eighth most common malignancy, accounting for 3% of newly diagnosed neoplasms⁽¹⁾. Most cases arise spontaneously, peaks in the 5th to 7th decades, with a male predominance^(1, 5, 8), and a male to female ratio of approximately 2.5:1⁽²⁾. Today, most newly diagnosed RCCs are discovered incidentally during imaging performed for non urologic symptoms^(5, 9).

Investigators have also concluded that renal cell carcinoma is not a single disease but, rather, a group of several disease entities ^(1, 10). According to the First International Workshop on Renal Cell Carcinoma held by the World Health Organization, renal cell carcinoma can be classified into conventional (i.e., clear cell) renal carcinoma, papillary renal carcinoma, chromophobe renal carcinoma, collecting duct renal carcinoma, and unclassified renal carcinoma ⁽¹¹⁻¹³⁾.

The prognosis of renal cell carcinoma depends on the size, stage, and grade of the tumor ⁽¹⁴⁾. The stage of a renal cell carcinoma at the time of treatment correlates directly with its prognosis ⁽¹⁵⁾. The tumor stage is the most important factor affecting the prognosis and survival rate. Tumor type also affects survival, with aggressive anaplastic renal cell carcinomas having a worse prognosis compared to clear cell carcinoma ⁽¹⁶⁻¹⁹⁾. An accurate diagnostic assessment of the extent of a renal cell carcinoma is valuable for determining the

therapeutic approach, which may include partial or radical nephrectomy, possibly with tumor thrombectomy or resection of infiltrated adjacent organs ⁽²⁰⁾.

Computed Tomography (CT) has proved to be the most important imaging technique for the evaluation of renal lesions and the preoperative staging of renal cell carcinomas ^(21, 22), with accuracy ranging between 72 and 90% ^(1, 2). The role of preoperative imaging is to define the tumor, detect and delineate the extent of venous involvement if any, as well detect the presence of local and distant metastases ⁽²³⁾. Furthermore, with the use of helical CT, it is possible to analyze the dynamic enhancement pattern of the tumor ⁽²⁴⁾.

The two most common staging systems that have been used for renal cell cancer staging are the Robson and TNM classification. Tumor staging for renal cell carcinoma has been incorporated into the TNM system of the UICC in 1997, which has been modified in 2002 (Table 1) ^(1, 16-19, 23).

Table 1: TNM classification and staging system of renal cell carcinoma (UICC, 2002)

T-classification	
T1	Confined to kidney, T1a < 4 cm, T1b < 7 cm
T2	Confined to kidney, >7 cm
T3	Confined to Gerota's fascia
T3a	Extending to ipsilateral adrenal or perirenal fat
T3b	Extending to renal vein or IVC below diaphragm
T3c	Extending to IVC above diaphragm
T4	Extending beyond Gerota's fascia
N-classification	
N0	No regional lymph node metastasis
N1	Metastasis in one regional lymph node
N2	Metastasis in more than one regional lymph node

Nx	Regional lymph nodes cannot be evaluated		
M-classification			
M0	No distant metastasis		
M1	Distant metastasis		
Mx	Distant metastasis cannot be evaluated		
Stage I	T1	N0	M0
Stage II	T2	N0	M0
Stage III	T3	N0	M0
	T1, T2, T3	N1	M0
Stage IV	T4	N0, N1	M0

Patients and methods

Between February 2008 and September 2009, a prospective study was done at Al-Kadhimiya teaching hospital, Baghdad, Iraq. The study included 40 patients (age range, 36–66 years; 28 men, 12 women; male: female ratio is 2.3:1) with solid renal masses.

Tumor size ranged from 1.7 to 6.5 cm (mean size, 3.1 cm). All the patients were diagnosed by CT as having renal cell carcinoma, underwent total nephrectomy and proved to be renal cell carcinoma at histopathological examination.

All the patients have an ultrasound examination that reveals the presence of a solid renal mass, being referred to CT.

Examinations were performed with the CT unit (Somatom plus4; siemens medical system, Germany). In all patients, initial CT images were obtained without administration of contrast material. In this examination the site and the density of the lesion were noticed. Two large pour IV canula were inserted into each antecubital vein, manual injection of 100ml of Intravenous contrast material (iohexole, Omnipaque 350, Schering, Berlin, Ireland) was administered, a

repeated CT scan was done 120 seconds after contrast injection (nephrographic phase (NP)), both scans should have covered the entire volume of the abdomen. During this perfusion phase, uniform contrast enhancement of the renal parenchyma was achieved. The NP mainly reflected the advanced distribution of contrast material in the renal interstitial space and the filtered contrast material entering the loops of Henle and the collecting tubules. In this phase the fallowing parameters were assessed: the size of the tumor, degree of contrast enhancement, and pattern of enhancement (heterogeneous or homogenous), presence of calcification, and presence of pseudo-capsule, perinephric involvement, LN enlargement, renal vein or inferior vena cava thrombosis, tumor extension into the ipsilateral adrenal gland.

Percentage of the above parameters was calculated. Diagnostic accuracy of CT in staging renal cell carcinoma was also calculated.

Results

Tumor size ranged from 1.7 to 6.5 cm (mean size, 3.1 cm). The entire patient underwent radical nephrectomy & proved to be renal cell carcinoma.

All patients included in the study showed a solid mass on unenhanced CT, with mean attenuation of 38HU (mean 30-54HU).

After IV contrast all the patients showed evidence of contrast enhancement by about 47HU. Thirty seven of our patients (92.5%) show evidence of heterogeneous enhancement while only 3 patients (7.5%) show homogenous enhancement. Calcification was seen in 10 patients (25%).

A pseudocapsule was present in 16 patients. Peri-nephric extension was seen in 18 patients. Adrenal glands were involved in 3 patients (7.5%).

Lymph node involvement with adenopathies larger than 1 cm in diameter was found in 7 patients (17.5%), only one patient (2.5%) showed false negative diagnosis, the over all diagnostic accuracy of LN detection was 83%.

Renal vein or inferior vena cava thrombosis was detected in 8 patients (20%), diagnostic accuracy was 87.5%.

Tumor extension beyond Gerota's fascia was observed in 5 patients (12.5%) (3 show evidence of liver metastases, & 2 patients show multiple lung metastases at follow-up examination).

CT showed that: 6 patients (15%) were stage I, 10 (25%) were stage II, 19 (47.5%) were stage III, 5 (12.5%) were stage IV.

Histopathological examination showed that: 6 patients (15%) were stage I, 14 (35%) were stage II, 15 (37.5%) were stage III, 5 (12.5%) were stage IV.

The overall diagnostic accuracy of CT in staging renal cell carcinoma was 90% (36 out of 40).

Figures 1 & 2 show examples of CT images of different patients having RCC at different stages of the disease.

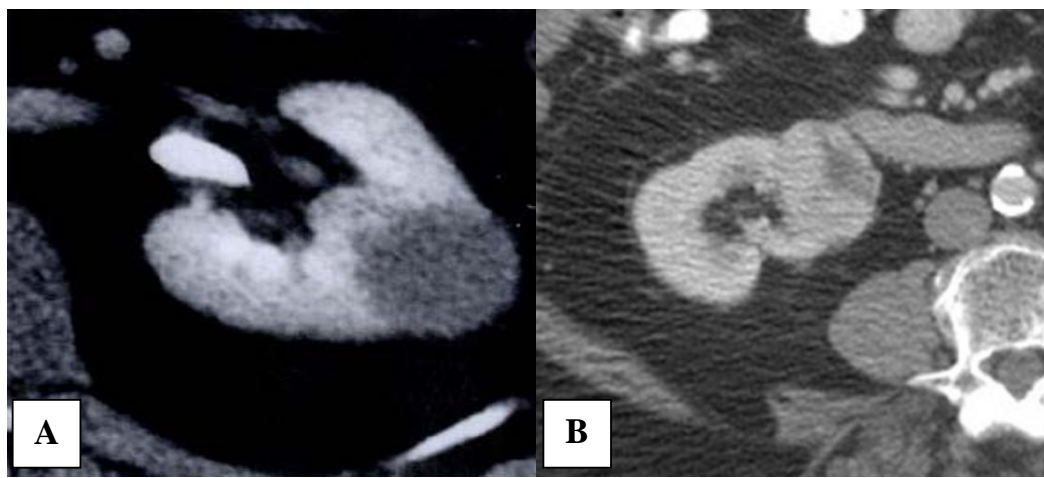


Figure1: A: 46 year old male with RCC of the Lt. Kidney (stage I) which is proved at histopathological examination. **B:** 45 year old male patient with RCC of right kidney shows evidence of perinephric extension (T3a), which was confirmed at histopathological examination.

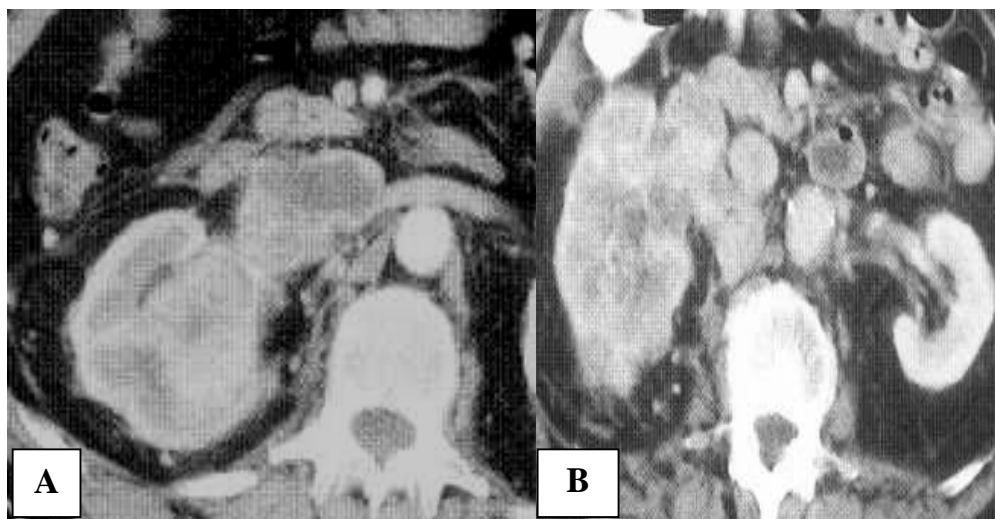

Figure1: **A:** 55year old male with RCC of the Rt. Kidney showing thrombosis of the Rt. Renal vein. **B:** 60 year old male patient with RCC of right kidney shows evidence of extra-renal extension and para-aortic LN enlargement.

Discussion

The prognosis of renal cell carcinoma depends on the size, stage, and grade of the tumor⁽¹⁴⁾. Improvement in imaging modalities continues to have a large impact on the diagnosis and treatment of solid renal masses⁽²⁵⁾. CT has proved to be the most important imaging technique for the evaluation of renal lesions and the preoperative staging of renal cell carcinomas^(21, 22). Spiral CT eliminates respiratory misregistration⁽²⁶⁾, and so is useful in evaluating renal lesions because the entire lesion is imaged free of skip areas and even small features can be depicted. Similarly, spiral CT might be useful in assessing contrast enhancement, considered by some the most important feature of small renal lesions^(27, 28).

Most renal cell cancers are solid, with attenuation values of more than 20HU on unenhanced CT images⁽¹⁾. In our study all patients showed solid mass on unenhanced CT, with mean attenuation of 38HU (mean 30-54HU).

The most important criterion used in differentiating surgical from non surgical renal masses is the

determination of enhancement. Renal mass enhancement is dependent on multiple factors, including the amount and rate of the contrast material injection, the imaging delay, and the nature of the tissue within the mass. Obviously, tumors that are very vascular will enhance considerably, while hypovascular tumors will enhance to a lesser degree, some tumors will enhance heterogeneously⁽²⁹⁾. Enhancement of more than 20HU indicates malignancy⁽¹⁾, in our study all the patients showed evidence of contrast enhancement of the renal mass by more than 47HU & this result was comparable to that seen by Jeong Kon Kim et al⁽³⁰⁾, where the tumors that enhanced more than approximately 44 H in the excretory phase were likely to be conventional renal carcinoma. Thirty seven of our patients (92.5%) showed evidence of heterogeneous enhancement while only 3 patients (7.5%) showed homogenous enhancement, these results were comparable to that seen by Jeong Kon Kim et al⁽⁸⁾.

In the current study calcification was seen in 10 patients (25%). In general, intratumoral calcification is not an uncommon finding in RCCs and may be seen in about 30% of cases ^(6, 31, 32). Calcification was associated with a better prognosis and is more frequently seen in papillary and chromophobe renal carcinomas ⁽²⁵⁾.

CT showed that a pseudocapsule was present in 16 patients & Perinephric extension was seen in 18 patients, 4 cases were over-staged as stage III disease on CT which later were proved to be stage II or stage I disease on histopathological examination i.e there is difficulty in differentiating T3a from T2 or T1 cases. The presence of pseudocapsule or its infiltration by a significant amount of tumoral tissue is a specific sign, which, nevertheless, cannot always and easily be recognized ^(33, 34).

The probable cause of the misinterpretation was the presence of perinephric edema (that was erroneously related to previous inflammatory processes), vascular engorgement, or fibrosis ^(1, 33). Perinephric spread of tumor has been reported as the most common cause of under- and overstaging of renal cell carcinoma on CT ⁽³⁵⁾. Renal cell carcinoma also acquires a collateral or parasitic blood supply which is often visible in the perinephric space and may be mistaken for tumour extension through the capsule ⁽²⁾. Fortunately, preoperative differentiation of stages II and III tumor is not essential for determining the therapeutic approach, which would be the complete resection of the kidney including the perinephric fat tissue in either case ⁽³⁵⁾, and this show little prognostic difference ⁽²⁾. Currently, however, nephron-sparing surgery (partial nephrectomy) is increasingly being offered under certain circumstances. These include situations where there is only one

functioning kidney and/or where the tumour is small (less than 4 cm diameter) and localised, especially if there is a possibility of a more benign pathology such as an oncocytoma. In these patients it becomes much more important to attempt accurate differentiation between stage II and III ⁽²⁾. With the recent surgical developments, this sign represents in some centers the main limitation for a conservative, possibly laparoscopic approach, which is feasible in stage I or II when no evidence of perinephric fat invasion is present ⁽³⁶⁾. In fact, the infiltration of perirenal fat tissue modifies the surgical approach from conservative to radical nephrectomy ^(15, 35, 37).

Adrenal glands were involved in 3 of our patients (7.5%). The overall incidence of adrenal metastases is between 1.2% and 8.5%, CT with normal appearing adrenal glands has a high negative predictive value for adrenal involvement with metastases, but a positive CT is not always due to malignancy, as adrenal adenomas are more commonly seen even in patients with underlying extra-adrenal malignancy ^(38, 39).

CT has a limited ability to identify lymph node involvement; the diagnosis of malignancy with regard to lymph node involvement is still based only on size criteria, with 10 mm as the limiting size for normal nodes ^(1, 40). Enlargement above 2 cm diameter is almost always due to metastases ⁽²⁾. In this study Lymph node involvement with adenopathies larger than 1 cm in diameter was found in 7 patients (17.5%), Lymph node metastases occur in about 15% of patients in the absence of other metastases ⁽⁴¹⁾. In our study only one patient (2.5%) showed false negative diagnosis and this result was approximate to that seen in the previously reported studies ^(1, 40) where 4% of lymph nodes had a false-

negative finding because micro-metastases could not be identified. There is also a variable false-positive rate due to nodal enlargement caused by reactive hyperplasia, this is more common when tumour necrosis or tumour thrombus is present^(1, 2). The reported accuracy of conventional CT in lymph node involvement was between 83% and 89%^(1, 2, 40) and this was similar to our study which showed the diagnostic accuracy of LN detection to be 83%. Nevertheless, it has been recently shown that there is no clinical benefit in performing regional lymph node dissection in patients with no suspected adenopathy before surgery or in those patients with lymph nodes smaller than 10 mm⁽⁴²⁾.

The evaluation of renal vein and inferior vena cava thrombosis is crucial for treatment planning; in fact, if tumor thrombus spreads into the inferior vena cava, the exact extent of the thrombus is essential for planning the correct surgical approach⁽²⁵⁾. Thrombus is seen as a filling defect within the vein. Isolated renal vein enlargement is an unreliable sign because it can be caused by increased blood flow secondary to tumour hypervascularity⁽¹⁾. In our study renal vein or inferior vena cava thrombosis was detected in 8 patients (20%) and this result was approximately similar to that seen in previously reported study where approximately 23% of renal cell carcinomas invade the renal veins and 7% invade the inferior vena cava⁽⁴³⁾. The diagnostic accuracy was 87.5% where only one patient had false positive CT diagnosis of renal vein thrombosis. The reported accuracy for detection of renal vein and inferior vena cava involvement using CT is 72-88%^(23, 44).

Tumor extension beyond Gerota's fascia was observed in 5 patients (12.5%) (3 showed evidence of liver metastases, and 2 patients showed

multiple lung metastases at follow-up examination). Staging of renal cell carcinoma also requires assessment of the lungs and liver where metastases can be found. Metastatic lesions to the liver may be, like the primary tumor, hypervascular⁽³¹⁾.

The overall diagnostic accuracy of CT in staging renal cell carcinoma was 90% (36 out of 40), and this was comparable with that seen in the previously reported literatures where the accuracy ranging between 72 and 90%^(1, 2, 45).

In Conclusions CT :

1. is an excellent imaging technique for the evaluation of solid renal masses and the preoperative staging of renal cell carcinomas.
2. has some difficulty in differentiating T3a from T2.
3. has a limited ability to identify lymph node involvement by malignancy because it is still based on size criteria only, with 10 mm as the limiting size for normal nodes.

References

1. Rottenberg G, Rankin S. NEOPLASTIC RENAL MASSES In: Andy Adam, Adrian K. Dixon, Grainger & Allison's Diagnostic Radiology, A Textbook of Medical Imaging, 5th ed, volume 1, London: Churchill Livingstone, 2008, P1420-1424.
2. Julian E. Kabala with a contribution from Carl Roobottom. The kidneys & the ureters In: David Sutton, textbook of radiology & imaging, 7th ed, volume 2, China: Churchill Livingstone, 2003. P. 954-956
3. Pantuck AJ, Zisman A, Belldegrun AS. The changing natural history of renal cell carcinoma. J Urol. 2001; 166:1611-1623.
4. Pickhardt PJ, Lonergan GJ, Davis CJ Jr, Kashitani N, Wagner BJ. Infiltrative renal lesions: radiologic-pathologic correlation. RadioGraphics 2000; 20:215-243.
5. Cohen HT, McGovern FJ. Renal-cell carcinoma. N Engl J Med. 2005; 353:2477-2490.
6. Levine E, King BF Jr. Adult malignant renal parenchymal neoplasms. In: Pollack HM, McClennan BL, eds. Clinical urography. 2nd ed. Philadelphia, Pa: Saunders, 2000; 1440-1559.
7. Zagoria RJ, Dyer RB. The small renal mass: detection, characterization, and

- management. *Abdom Imaging* 1998; 23:256–265.
8. Jeong Kon Kim, Soo-Youn Park, Jeong-Hee Shon, and Kyoung-Sik Cho. Angiomyolipoma with Minimal Fat: Differentiation from Renal Cell Carcinoma at Biphasic Helical CT. *Radiology* 2004; 230: 677-684.
 9. Leslie JA, Prihoda T, Thompson IM. Serendipitous renal cell carcinoma in the post-CT era: continued evidence of improved outcomes. *Urol Oncol* 2003; 21:39–44.
 10. McClennan BL, Deyoe LA. The imaging evaluation of renal cell carcinoma: diagnosis and staging. *Radiol Clin North Am* 1994; 32:55 -69.
 11. Reuter VE, Presti JC Jr. Contemporary approach to the classification of renal epithelial tumors. *Semin Oncol* 2000; 27:124 -137.
 12. Bostwick DG, Eble JN, Murphy GP. Conference summary: diagnosis and prognosis of renal cell carcinoma—1997 workshop. *Cancer* 1997;80:975 -976 .
 13. Bostwick DG, Eble JN. Diagnosis and classification of renal cell carcinoma. *Urol Clin North Am* 1999; 26:627 -635.
 14. Butler BP, Novick AC, Miller DP, et al. Management of small unilateral renal cell carcinomas: radical versus nephron-sparing surgery. *Urology* 1995; 45:34-41.
 15. Trasher JB, Paulson DF. Prognostic factors in renal cancer. *Urol Clin North Am* 1993;20:247-262
 16. Fleming ID, Cooper JS, Henson DE et al., eds. 5th ed. Philadelphia, PA: Lippincott-Raven; 1997. *AJCC Cancer Staging Manual*.
 17. Minervini R, Minervini A, Fontana N, Traversi C, Cristofani R. Evaluation of the 1997 tumour, nodes and metastases classification of renal cell carcinoma: experience in 172 patients. *BJU International*. 2000; 86(3):199–202.
 18. Gettman MT, Blute ML, Spotts B, Bryant SC, Zincke H. Pathologic staging of renal cell carcinoma: significance of tumor classification with the 1997 TNM staging system. *Cancer*. 2001; 91:354–61.
 19. Gofrit ON, Shapiro A, Kovalski N, Landau EH, Shenfeld OZ, Pode D. Renal cell carcinoma: evaluation of the 1997 TNM system and recommendations for follow-up after surgery. *European Urology*. 2001; 29:669–75.
 20. Moll V, Becht E, Ziegler M, Kidney preserving surgery in renal cell tumors: indications, techniques and results in 152 patients. *J Uml* 1993;150:319-323
 21. Rotte KM, Kriedemann E. Computed tomography of renal cell carcinoma. *Radiologe* 1992;32: 114-120.
 22. Zagoria Ri, Bechtold RE, Dyer RB. Staging of renal adenocarcinoma: role of various imaging Kopka et al. 1578 *AJR*: 169, December 1997 procedures. *AiR* 1995;164:363-370
 23. Isaac R Francis. Detection, staging and surveillance in renal cell carcinoma. *Cancer Imaging*. 2006; 6(1): 168–174.
 24. Garant M, Bonaldi VM, Taourel P, Pinsky MF, Bret PM. Enhancement patterns of renal masses during multiphase helical CT acquisitions. *Abdom Imaging* 1998; 23:431 -436.
 25. Catalano C, Fraioli F, Laghi A, Napoli A, Pediconi F, Danti M, et al. High-Resolution Multidetector CT in the Preoperative Evaluation of Patients with Renal Cell Carcinoma. *AJR* 2003; 180:1271-1277.
 26. Kalendar WA, Seissier W, Kiotz E, vock P. Spiral volumetric CT with single breath-hold technique, continuous transport, and continuous scanner rotation. *Radiology* 1990;176:181-183
 27. Bosniak MA. The small (<3.0 cm) renal parenchymal tumor: detection, diagnosis, and controversies. *Radiology* 1991 179:307-317.
 28. Levine E, Huntrakoon M, wetzell H. Small renal neoplasms: clinical, pathologic, and imaging features. *AJR* 1989; 153:69-73.
 29. Gary M, Israel and Morton A. Bosniak. How I Do It: Evaluating Renal Masses. *Radiology* 2005; 236:441-450.
 30. Jeong Kon Kim, Tae Kyoung Kim, Han Jong Ahn, Chung Soo Kim, Kyu-Rae Kim and Kyoung-Sik Cho. Differentiation of Subtypes of Renal Cell Carcinoma on Helical CT Scans. *AJR* 2002; 178:1499-1506.
 31. Sheth S, Scatarige JC, Horton KM, Corl FM, Fishman EK. Current concepts in the diagnosis and management of renal cell carcinoma: role of multidetector CT and three-dimensional CT. *RadioGraphics* 2001; 21:S237–S254.
 32. Dunnick NR, Sandler CM, Newhouse JH, Amis ES Jr. Renal tumors. In: *Textbook of uro radiology*. 3rd ed. Philadelphia, Pa: Lippincott Williams & Wilkins, 2001; 123–149.
 33. Kopka L, Fischer U, Zoeller G, Schmidt C, Ringert RH, Grabbe E. Dual-phase helical CT of the kidney: value of the corticomedullary and nephrographic phase for evaluation of renal lesions and preoperative staging of renal cell carcinoma. *AJR* 1997; 169:1573 –1578.
 34. Takahashi S, Ueda J, Furukawa T. Renal cell carcinoma: preoperative assessment for

enucleative surgery with angiography, CT, and MRI. *J Comput Assist Tomogr* 1996; 20:863 – 860.

35. Levine E. Malignant parenchymal tumors in adults. In: Pollack HM, ed. *Clinical urography*, vol. 2. Philadelphia: Saunders, 1990:1216 –1291.

36. Novick AC. Nephron sparing surgery for renal cell carcinoma. *Br J Urol* 1998; 82:321 – 324.

37. Flanigan RC. Partial nephrectomy and tumor enucleation. In: Glenn JF, ed. *Urologic surgery*, 4th ed. Philadelphia: Lippincott, 1991:51 –59.

38. Tsui KH, Shvarts O, Barbaric Z, Figlin R, de Kernion JB, Belldegrun A. Is adrenalectomy a necessary component of radical nephrectomy? UCLA experience with 511 radical nephrectomies. *J Urol*. 2000; 163:437–41.

39. Autorino R, Di Lorenzo G, Damiano R. Adrenal sparing surgery in the treatment of renal cell carcinoma: when is it possible? *World J Urol*. 2003; 21:153–8.

40. Studer UE, Scherz S, Scheidegger J. Enlargement of regional lymph nodes in renal cell carcinoma is often not due to metastases. *J Urol* 1990; 144:243 –245.

41. Herrlinger A, Schrott KM, Schott G. What are the benefits of extended dissection of the regional renal lymph nodes in the therapy of renal cell carcinoma? *J Urol*. 1991; 146:1224–7.

42. Minervini A, Lilas L, Morelli G. Regional lymph node dissection in the treatment of renal cell carcinoma: is it useful in patients with no suspected adenopathy before or during surgery? *BJU Int* 2001; 88:169 –172.

43. Laissy JP, Menegazzo D, Debray MP. Renal carcinoma: diagnosis of venous invasion with Gd-enhanced MR venography. *Eur Radiol*. 2000; 10:1138–43.

44. Hallscheidt PJ, Fink C, Haferkamp A. Preoperative staging of renal cell carcinoma with inferior vena cava thrombus using multidetector CT and MRI: Prospective study with histopathological correlation. *J Comput Assist Tomogr*. 2005; 29:64–8.

45. Hallscheidt PJ, Bock M, Riedasch G. Diagnostic accuracy of staging renal cell carcinoma using multidetector-row computed tomography and magnetic resonance imaging: a prospective study with histopathologic correlation. *J Comput Assist Tomogr*. 2004; 28:333–9.

Induction of Cardiomyogenic Differentiation of Adult Bone Marrow Stem Cells in Albino Rats by using 5-azacytidine.

Intidhar M. Mnati *PhD.*

Abstract

Background: Mesenchymal stem cells have capability for proliferation, self renewing, and differentiation into different types of cells *in vitro* and the medical potential use of these cells is in tissue replacement therapy.

Objective: This study aimed to isolate and cultivate mesenchymal stem cells (MSCs) of adult albino rats *Rattus rattus norvegicus albinus* and enhancement their growth, proliferation and maintainance in active state for several weeks.

Methods: The successively passaged cells were exposed on the second day of cultivation to the Minimum essential medium (MEM) with 5-azacytidine at a concentration of 10µmol/L.

Results: The results of *in vitro* study showed that the mesenchymal stem cells showed fibroblast like morphology appearance before 5-azacytidine treatment, but its morphology began to change after 5-azacytidine treatment

in about 50% of the adherent cells. These cells were connected with adjoining cells after one week and began to form myotube-like structures at the end of the second week. The immunocytochemical staining demonstrated that the differentiation of mesenchymal stem cells into cardiac-like muscle cells, which was detected by using specific marker (anti-cardiotin), expressed positive response for this marker.

Conclusion: Rat mesenchymal stem cells can be extensively expanded *in vitro* and chemical –induced cardiomyogenic differentiation by 5-azacytidine treatment

Key words: Bone marrow stromal cells; Proliferation; Differentiation; 5-azacytidine; Cell culture.

IRAQI J MED SCI, 2010; VOL.8 (4):34-40

Introduction

Stem cells are a subject of intense and increasing interest because of their biological properties and potential medical importance in treating and repairing injured and damaged tissues. Stem cells have been regarded as undifferentiated cells capable of proliferation, self-renewal, and production of a large number of differentiated progeny⁽¹⁾.

Recent attention has focused on bone marrow (BM) as a source of stem cells for transplantation .At present, BM transplantation is a normal operation used for the treatment of many diseases⁽²⁾. There are at least two populations of adult stem cells that have been identified

in the BM which represented by hematopoietic stem cells (HSCs) and mesenchymal stem cells (MSCs).

Mesenchymal stem cells are nonhematopoietic multipotent stem – like cells and their isolation is based on their adhesive properties and expanded *in vitro*⁽³⁾. MSCs have been considered as one of the most promising candidates for medical applications⁽⁴⁾.

The potential of MSCs to differentiate into myogenic cells was first reported by Wakitani *et al.*,(1995)⁽⁵⁾ and then by a number of other investigators⁽⁶⁾. More recently, cardiomyogenic cell line was isolated from immortalized MSCs exposed to 5-azacytidine⁽⁴⁾, followed by a report that primary culture of rat MSCs treated with 10µmol/L 5-azacytidine were able to form myotubes – like structure and express myocardial specific proteins, such as cardiac troponin I and cardiac myosin heavy chain (MHC)⁽⁷⁾. The

Dept. Biology, College of Education / Ibn AL-Haitham /Baghdad University.

Address Correspondence to: Dr. Intidhar M. Mnati ,

E- mail: entidhar.1973@yahoo.com

Received: 25th January 2010, Accepted: 30th July 2010.

MSCs were isolated from isogenic Lewis rats, and then treated with 5-aza-2-deoxycytidine. The treated cells showed more myotube – like with elongated nuclei and stained positive for the cardiomyocyte – specific marker troponin I⁽⁸⁾. Various strategies have been adopted for directed differentiation of Bone marrow stromal cells (BMSCs) into cardiomyocytes. The induction of cardiomyogenic differentiation of these cells has been achieved by culturing BMSCs *in vitro* using culture media supplemented with retinoic acid (RA), dimethyl sulphoxide (DMSO) and 5-azacytidine⁽⁹⁾.

The potential use of BMSCs as a cellular therapy for chronic cardiac diseases relies on the ability of the cell to replicate extensively *in vitro* and to give rise to myogenic cells that replace the damaged cardiomyocytes. For this reason the present study investigated the chemical –induced cardiomyogenic differentiation of rat MSCs *in vitro* depending on available potentials and stimulation of the growth and differentiation of MSCs into myogenic phenotype after being treated with 5-azacytidine for different exposure periods and detection of the resulting cells by using specialized marker.

Materials and Methods

-Cell Isolation and Culturing

Young male rats (*Rattus rattus norvegicus albinos*) were used as an animal model for the isolation of MSCs from the BM and were cultured *in vitro*. These animals were obtained from the animal house in Medical Research Unit of College of Medicine in Al-Nahrain University. Isolation and culturing of BM–MSCs took place in the same unit.

Bone marrow was extruded from femur and tibiae and mixed with 3mL Minimum Essential Medium (MEM) supplement with 10% Fetal Calf Serum(FCS).The tube was centrifuged at 2000 rpm for 10 minutes, after centrifugation, the fat and serum layers

were discarded and the cell pellet was resuspended with 3ml of complete growth medium⁽¹⁰⁾.The cell suspension (top layer) was loaded carefully into 5ml of 60% percoll(separation liquid) (bottom layer) in a sterile conical tube, centrifuged at 2000 rpm for 20-25 minutes at 8C° using cooling centrifuge. After density gradient centrifugation, the mononuclear cells (MNCs) were retrieved from the buffy coat layer, and washed two to three times with Phosphate buffer saline (PBS) to remove the percoll at 2000 rpm for 10 minutes at 8C°.After the determination of cells count and viability,the cell suspension were seeded into 50 cm² culture flasks with 5 mL of MEM supplement with 10%FCS at a plating density of 1x10⁶ cells/mL and incubated with 5%CO₂ at 37C°.The medium was changed to remove the nonadherent cells 24h after seeding and every 3 days thereafter.The attached cells were grown and developed within 5-7 days and after 10 days ,the primary culture of MSCs reached nearly 70-80% confluence and was expanded by two passages⁽¹⁰⁾.

-Stimulation and Differentiation of Mesenchymal stem cells in vitro

The second passage of rat BM-MSCs were resuspended after trypsin treatment. The cells were seeded into 4-well tissue culture plates at a density of 1x10⁴ cells/mL. The tissue culture flasks were divided into two groups as follows:-

-Control group: treated with MEM +10% FCS only.

-Treated group: treated with MEM +10% FCS with 5-azacytidine.

The treated group was divided into three different periods for 1week, 2weeks and 3weeks. Forty- eight hours after seeding, 5- azacytidine was added to the culture medium at a final concentration of 10µmol/L. The medium was changed 24h later,and the cells continually cultured for 3-4 weeks

The medium was changed twice a week until the experiment was terminated. The differentiated cells were fixed with 4% phosphate buffered formalin for 10 minutes, and preserved at 4C°. The cells were detected by using immunocytochemistry examination which was performed with primary monoclonal against anti-cardiotin ⁽¹¹⁾.

Results

- Cardiomyocytes Differentiation of Mesenchymal Stem Cells *in vitro*

In the tissue culture flask, two major types of cells were noticed, HSCs and MSCs. During the first few hours of culturing, most of BMSCs were floating and began to adhere on the culture flask progressively. The MSCs appeared a fibroblast-like morphology before 5-azacytidine treatment (Figure1). After 5-azacytidine treatment, the morphology of the cells gradually changed. The first 24h exposure of the cultured cells to 5-azacytidine, which occurred two days after the second passage of cultivation, did not cause any obvious morphological changes. Approximately 50% of all remaining adherent cells had lengthened in one direction and formed a stick-like morphology at one week (Figure2). At the end of second week, the cells began

to be connected to each other and then formed myotube-like structure (Figure3). After three weeks, most of the cells were mononuclear and some of them were binuclear (Figure 4). The differentiated cells can be distinguished from skeletal muscle cells by the presence of a number of branches and these cells began interface with each other to form cardiac-like cells (Figure5). These morphological changes of BM-MSCs in treated groups during different exposure periods were not seen in control groups.

-Immunocytochemical Examination for Differentiation of Mesenchymal Stem Cells *in vitro*

The immunostaining of the differentiated MSCs with anti-cardiotin at two and three weeks after 5-azacytidine treatment showed that about 80% of the resulting differentiated cells expressed the protein and were positive for cardiotin. This protein was found in the longitudinal sarcoplasmic reticulum of mature cardiomyocytes. These cells represented with brown granular Diamino benzidine (DAB) reaction product in the cytoplasm and were considered positive for the protein (Figure 6).

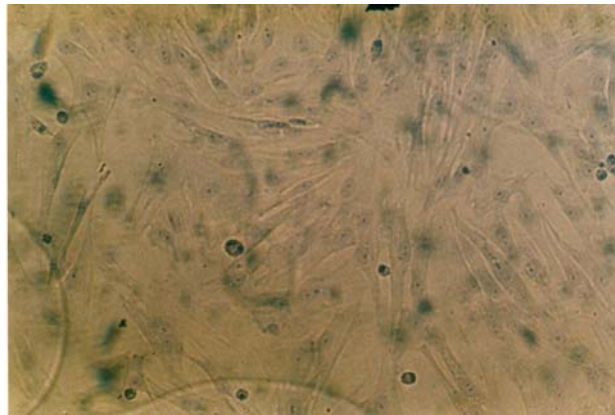


Figure 1: The morphology of MSCs at second passage revealed under inverted microscope showed the fibroblast like morphology. (X100.8)

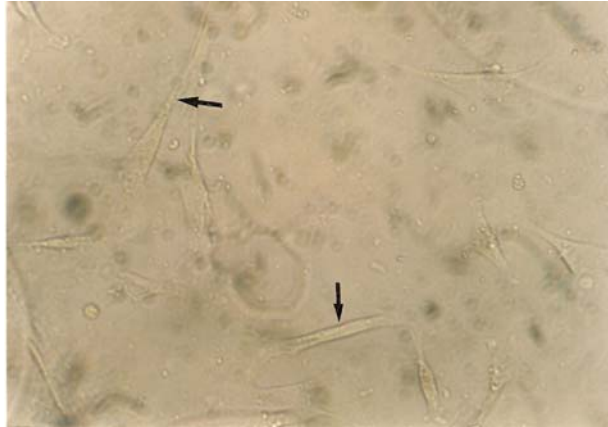


Figure 2: The cells in the first week after 5-azacytidine treatment showed that most of adherent cells lengthened and formed stick-like morphology (arrows) (X160).

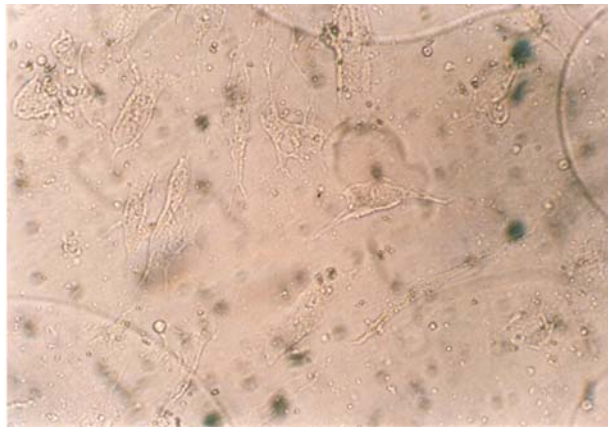

Figure 3: The cells at the end of second week of culturing showed that the cells connected with adjoining cells and began to form myotube-like structure (X100.8).

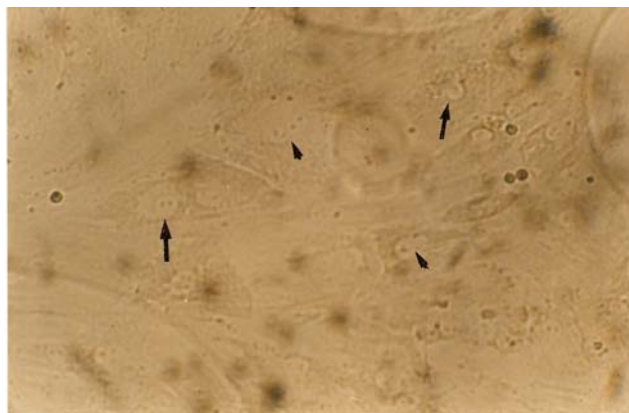


Figure 4: The cells at the third week of culturing showed that the most of cells were mononuclear (thick arrows) and some were binuclear (head arrows)(X100.8).



Figure 5: The cells after third week of treatment showed that the branches of these cells interface with each other (arrows) (X100.8).




Figure 6: Immunocytochemical analysis for differentiation of MSCs in treated groups showed that the most of these cells expressed positive response for anti-cardiotin and stained with brown color (DAB) stain(X400).

Discussion

Cardiomyogenic Differentiation of Mesenchymal Stem Cells *in vitro*

Mesenchymal stem cells were first described by Freidenstein *et al.*, (1968)⁽¹²⁾, who discovered that MSCs adhered to tissue culture plates, resembled fibroblasts in morphology and grew in the form of a colony. These characteristics have been identified in MSCs from numerous species including human, rats, mice, rabbits and monkeys⁽¹³⁾. To direct the differentiation of MSCs into specialized population need to change the growth conditions of MSCs in specific ways, such as by adding

growth factors to the culture medium or changing the chemical composition of the surface on which MSCs were growing⁽¹⁴⁾. 5-azacytidine was used as stimulating factor to induce the differentiation of MSCs towards myogenic cells with cardiomyocytes – like characteristics for different exposure periods.

The results of present study are consistent with many of prior reports by Makino *et al.*(1999)⁽⁴⁾ and Wakitani *et al.*,(1995)⁽⁵⁾ who suggested that by using 5-azacytidine induced BM-MSCs to differentiate into myogenic cells, these adherent and differentiated

cells formed a stick-like morphology resembling the myotube-like structure. The effects of several materials such as Amphotericin-B or drug of 5-azacytidine was similar to the effect of heart muscle extract (HME) treatment in stimulation and differentiation of HSCs or MSCs into myogenic cells in culture^(15, 16). The role of these embryonic extract in most embryonic tissues is regarded as an important source of extracting factors that stimulate the growth and differentiation of stem cells into special direction. In studies on myogenic differentiation of the mouse embryonic cell line, Konieczny *et al.*, (1984)⁽¹⁷⁾ found that these cells contain a myogenic determination locus in a methylated state with a transcriptionally inactive phase, which become demethylated and transcriptionally active with 5-azacytidine causing the cells to differentiate into myogenic cells.

Immunocytochemical Examination of Mesenchymal Stem Cells *in vitro*

Cardiotin is a high molecular weight protein complex (300KDa) located in the longitudinal sarcoplasmic reticulum (SR) of cardiac muscle. The immunostaining analysis using anti-cardiotin marker demonstrated that most of the differentiated cells expressed this protein and these cells represented with brown granular DAB reaction product in the cytoplasm, and there considered to be positive for this protein, these findings are similar to that described by Pochampally *et al.*, (2004)⁽¹¹⁾.

References

1. Morrison SJ, Shah NM and Anderson DJ. Regulatory mechanisms in stem cell biology. *Cell*, 1997; 88: 287-298.
2. Nilsson S K, Simmons PJ and Bertoncello I. Haematopoietic stem cell engraftment. *Exp. Hematol.* 2006; 34: 123-129.
3. Pittenger MF and Martin BJ. Mesenchymal stem cells and their potential as cardiac therapeutics. *Circ. Res.* 2004; 95:9.

4. Makino S, Takahashi T, Hori S, Abe H, Hata J I, Umezawa A and Ogawa S. Cardiomyocytes can be generated from marrow stromal cells *in vitro*. *J. Clin. Invest.* 1999; 103(5): 697-705.
5. Wakitani S, Saito T and Caplan AI. Myogenic cells derived from rat bone marrow mesenchymal stem cells exposed to 5-azacytidine. *Muscle Nerve*, 1995;18: 1417-26
6. Tomita S, Mickle DAG, Weisel RD, Jia ZQ, Tumiati LC, Allidina Y, Liu P and Li RK. Improved heart function with myogenesis and angiogenesis after autologous porcine bone marrow stromal cell transplantation. *J. Thorac. Cardiovasc. Surg.* 2002; 123:1132-40.
7. Tomita S, Li RK, Weisel RD, Mickle DAG and Jia ZQ. Autologous transplantation of bone marrow cells improves damaged heart function. *Circ.* 1999;100 (19 suppl.): II247-56.
8. Bittira B, Kuang JQ, Al-Khalidi A, Shum-Tim D and Chiu RCJ. *In vitro* pre-programming of marrow stromal cells for myocardial regeneration. *Ann. Thorac. Surg.* 2002; 74: 1154-1160.
9. Heng BC, Haider KH, Sim EK, Cao T and Ng SC. Strategies for directing the differentiation of stem cells into the cardiomyogenic lineage *in vitro*. *Cardiovasc. Res.* 2004; 62: 34-42.
10. Dodson SA. Cell suspension comparisons of bone production in bone marrow stem cells of young and adult aged rats as measured *in vitro* by bone colony assays. Thesis. www.term.paperpower.com./stem-cell-thesis.2000.
11. Pochampally RR, Neville BT, Schwarz EJ, Li MM and Prockop DJ. Rat adult stem cells (marrow stromal cells) engraft and differentiate in chick embryos without evidence of cell fusion. *PNAS.* 2004; 101 (25): 9282-9285
12. Freidenstein AJ, Chailakhjan RK and Lalykina KS. The development of fibroblast colonies in monolayer cultures of guinea-pig bone marrow and spleen cells. *Cell Tissue Kinet.* 1968; 3: 393-403.
13. Javazon EH, Colter DC, and Prockop DJ. Rat marrow stromal cells are more sensitive to plating density and expand more rapidly from single-cell-derived colonies than human marrow stromal cells. *Stem Cells.* 2001;19 (3): 219-225.
14. Odorico JS, Kaufman DS and Thompson JA. Multilineage differentiation from human embryonic stem cell lines. *Stem Cells.* 2001; 19: 193-204.
15. Al-Jumely BA. Long-term culture of adult bone marrow stem cells in albino mice. M.Sc. Thesis, College of Science, Baghdad University, 112p. 2006. (In Arabic)

16. Mnati IM. *In vivo* and *in vitro* studies of adult bone marrow stem cells and its role in induced myocardial infarction in albino rats. Ph.D. Thesis, College of Education (Ibn AL-Haitham) , Baghdad University ,157p.2007.

17. Konieczny SF and Riley GP. 5-azacytidine induction of stable mesodermal stem cell lineages from 10T1/2 cells: evidence for regulatory genes controlling determination. *Cell*.1984; 38: 791-800.

Prevalence of delirium among medical inpatients in Teaching Hospital in Baghdad.

Uday A.J. Khalid *MBChB; CAB (Psych.); FIBMS (Psych.)*

Abstract

Background: Delirium is a syndrome characterized by the rapid onset of variable and fluctuating changes in attention resulting in disturbed behavior, illusions, hallucinations & changing level of consciousness caused by physiological consequences of a medical disorder, its prevalence is estimated to be about 15-20% of general medical wards.

Objectives: The aim of this study is to measure the prevalence of delirium in patients admitted to medical wards and to study signs and symptoms of delirium.

Methods: A cross sectional study of all patients who were admitted to the medical wards of Al Kadhymia General Teaching Hospital in Baghdad during the study period which is from 21 March 2008 to 21 April 2008, the total admissions were 510 patients, with excluding criteria: a pre-existing

psychiatric disorder and age less than 18 year.

- Approval to the questionnaire was taken from the relatives.

- All patients with delirium were referred by residents during the study period

- Delirium cases were diagnosed according to DSM IV criteria; prevalence was estimated and symptoms studied

Results: The prevalence of delirium was about 3% among the medical inpatients.

Conclusion: The prevalence of delirium reported in this study is low in comparison to other studies. This is explained in terms of difference of methodology used in this study in comparison with other studies.

Key words: delirium, inpatients, medicine

IRAQI J MED SCI, 2010; VOL.8 (4):41-46

Introduction

Delirium is a syndrome characterized by the rapid onset of variable and fluctuating changes in mental status caused by physiologic consequences of a medical disturbance⁽¹⁾. According to the fourth edition of the Diagnostic and Statistical Manual of Mental Disorders (DSM-IV). "The essential feature of a delirium is a disturbance in consciousness that is accompanied by a change in cognition that cannot be better accounted for by a pre-existing, established or evolving dementia⁽²⁾."

It's an acute and relatively sudden (developing over hours to days) decline in attention-focus, perception, and cognition. In medical usage it is not synonymous with drowsiness, and may occur without it.

It is commonly associated with a disturbance of consciousness (e.g., reduced clarity of awareness of the environment), change in cognition (memory deficit, disorientation, language disturbance) or the development of a perceptual disturbance. Usually the rapidly fluctuating time course of delirium is used to help in the latter distinction⁽³⁾.

Typically, delirium develops over a course of hours to days, and changes in mental status wax and wane over a short period of time. Because delirium is the direct result of an underlying medical condition, it typically improves fairly quickly when the causative factor is identified and corrected. The diagnosis of delirium is challenging because it has variable presentations that include disturbance in one or more of the following domains: orientation, thought process, perception, memory, mood, and behavior with or without hyperactivity⁽⁴⁾. Delirium has been known by a

Dept. Medicine, College of Medicine, Al-Nahrain University.

Address Correspondence to: Dr. Uday A.J. Khalid ,

E- mail: udaykhalid@yahoo.com

Received: 12th October 2009, Accepted: 14th June 2010.

variety of names, including acute confusional state, acute brain syndrome, metabolic encephalopathy, toxic psychosis⁽⁴⁾.

Because it represents a change in cognitive function, diagnosis cannot be made without knowledge of the affected person's baseline level of cognitive function⁽⁶⁾. Without careful assessment, delirium can easily be confused with a number of psychiatric disorders because many of the signs and symptoms of delirium occur in conditions such as dementia,

depression, and psychosis⁽⁷⁾.

Delirium itself is not a disease, but rather a clinical syndrome (a set of symptoms), which result from an underlying disease or new problem with mentation. Like its components (inability to focus attention and various impairments in awareness and temporal and spatial orientation), delirium is simply the common symptomatic manifestation of early brain or mental dysfunction (for any reason)⁽⁸⁾.

Table 1: Potential Causes of Delirium⁽⁹⁾.

1- <u>drugs</u> : intoxication/withdrawal
2- <u>Infections</u> :
○ Systemic infections.
○ CNS infections: Meningitis, encephalitis.
3- <u>Post operative</u> :
4- <u>Metabolic & Endocrine</u>
○ Hepatic encephalopathy.
○ Thyroid
○ Parathyroid
○ Pancreatic
5- <u>CNS Causes</u> :
○ CNS:
○ TIA
○ Brain trauma
○ Seizures and postictal states
○ Neoplasm
● Steroids

Methods

Cross sectional observational study of all patients admitted to the medical department of Al Kadhimyia General Teaching Hospital during the study period from 21 March 2008 to 21 April 2008.

All patients diagnosed as complaining of delirium who were referred by doctors were studied by specific interviewing procedure according to DSM IV criteria of delirium together with special form for

collecting the demographic criteria of patients and the symptoms of delirium.

Exclusion Criteria

- Presence of their psychiatric disorders.

- Age group less than 18 years.

Simple statistical analysis for results was performed.

Results

The prevalence of delirium was 2.95 %. The total no. of inpatients during study period was 510. The total

no. of delirium cases was 15. Among delirious patients 8 (53.3%) were females and 7 (46.7) were males. 12(80%) of patients were married and

3(20%) were single. The average age of patients was 58 years (SD 4.8) as in table 2.

Table 2: Distribution of delirium cases according to age groups

Age groups	Frequency	Percent
Valid 20-29	1	6.7
40-49	2	13.3
50-59	4	26.7
60-69	3	20.0
70-79	4	26.7
80-89	1	6.7
Total	15	100.0

Regarding the presenting symptoms; all the patients had confusion, 53.3% had labile mood, 53.3% had hallucinations, 40% had agitation, and 60% had gross retardation. all the patients had disturbed attention and concentration and 86.7% had memory disturbance (Tables 3-8).

The distribution of causes of delirium in this study is shown in table- 9. Intracranial hemorrhage (ICH) was the most common cause followed by diabetic ketoacidosis (DKA) and pyrexia of unknown origin (PUO) and then renal failure (RF).

Table 3: Frequency of labile mood among delirium patients.

	Frequency	Percent
Valid Yes	8	53.3
No	7	46.7
Total	15	100.0

Table 4: Frequency of hallucination among delirium patients.

	Frequency	Percent
Valid Yes	8	53.3
No	7	46.7
Total	15	100.0

Table 5: Frequency of agitation among delirium patients.

	Frequency	Percent
Valid Yes	6	40.0
No	9	60.0
Total	15	100.0

Table 6: Frequency of gross retardation in mental and physical activity among delirium patients.

	Frequency	Percent
Valid Yes	9	60.0
No	6	40.0
Total	15	100.0

Table 7: Frequency of disturbance in attention and concentration among delirium patients.

	Frequency	Percent
Valid Yes	15	100.0

Table 8: Frequency of disturbance of memory among delirium patients.

	Frequency	Percent
Valid Yes	13	86.7
No	2	13.3
Total	15	100.0

Table 9: Frequency of causes of delirium patients

	Frequency	Percent
Valid ICH	5	33.3.
DKA	2	13.3.
PUO	3	20.0
RF	2	13.3
Hypoglycemia	1	6.7
Tumor	1	6.7
Drug over dose	1	6.7
Total	15	100.0

Discussion

this study showed that the prevalence of delirium among the total admissions of 510 patients to medical wards in our hospital during study period is about 3% and it is found that the rate is very low in comparison to prevalence reported in studies by Plaschkek, Hill H. & Engelhar; ⁽¹⁰⁾ which is about 28.9% , by Johanna C. Korevaar & Barbara C Van Munster ⁽¹¹⁾ which is about 29%, Wakefield B & Johanson J.A.⁽¹²⁾ which is about 69.6% among their sample group of terminally ill patients, and Kanaayiram

Alagiakrishnan⁽¹³⁾ which is about 10-22% .

the possible explanation of that may be related to the method used in this study, cases reported in this study are those which are referred by residents or staff members. It is possible that residents or staff consider a case to be that of delirium only when there is emergency situation, gross retardation or agitation among patients while cases with mild cognitive impairment caused by delirium are not recognized as such. This means that it

is possible that only agitated, or severely retarded or grossly disturbed patients were included in this study. This needs further confirmation by further studying and revising diagnostic criteria set by residents about delirium. Of course better recognition of such cases is important as missed cases may be left without treatment and prognosis may be worse as delirium has very variable clinical presentation and not necessarily presented with agitation or retardation, the support for this explanation is the high level of agitation and retardation reported in the cases of this study.

Regarding the methodology of this study; ideally there should be daily screening of all patients in the ward with specific psychometric tests for diagnosis of delirium. In this way all cases of delirium even with minimal cognitive functions without behavioral disturbance can be recorded. This was not possible with limitation in the time of the study and availability of the relevant clinical tests.

The mean age of delirious patients in our sample was 58 years and 53.4% of them were above 60 years. The mean age was reported to be 73.5-83.7 by Wakefield B. & Johanson J.A. ⁽¹²⁾, Johanna C. Korevaar & Barbara c Van Munster ⁽¹¹⁾, and Plaschkek, Hill H. & Engelhard's ⁽¹⁰⁾. The explanation for lower age average as reported in this study is that life expectancy is now increasingly higher in western countries than developing countries and this will yield more cases with old age that are vulnerable to delirium as noticed in the studies above.

In our study, 46.7% of the subjects (patients) who were diagnosed as delirium are women and the rest 53.3% are men. In comparison with Wakefield B. & Johanson J.A. ⁽¹²⁾ who reported that women represents 31.2% and men 68.8%, while Johanna C.

Korevaar & Barbara c Van Munster ⁽²⁰⁾ reported that 45% of patients were women. Regarding the marital status of the patients, 80% of them were married. As was noticed most patients in this study are above middle age and most Iraqi people are married by this age .

Confusion and disturbance of attention and concentration reported in all cases in this study. 53.3% of the patients had either visual or auditory Hallucination, while it was reported in 43% of patients in Kanaayiram Alagiakrishnan ⁽¹³⁾.

Agitation manifestation appeared in 40% of the present sample and 58.5% among patients of Wakefield B & Johanson J.A. study ⁽²¹⁾ and 22% in Kanaayiram Alagiakrishnan study ⁽¹³⁾. Gross retardation in mental and physical activity reported in 60% of our patients while it was 35.6% in patients included by Wakefield B & Johanson J.A study ⁽¹²⁾, and 26% only by Kanaayiram ⁽¹³⁾.

According to Kanaayiram`s study ⁽¹³⁾, (labile mood) was present in 70% of his sample while in the present study it was only 53.3%. The difference between the above variables in this study and the studies mentioned above may also be related again to the same concepts discussed above in relation to case detection in this study i.e. only grossly disturbed, agitated or retarded or confused patients are referred and such patients usually have full blown picture of the syndrome. This means that the above results are related to the low reported prevalence because this prevalence may not reflect the true possible No. of cases of delirium that actually occurred during study period because of the factors mentioned above. In other words this recorded no. may not reflect the actual no. of cases which if identified may give similar results to other studies regarding these variables, similarly regarding the

underlying causes delirium in our patients, the results detected may not reflect the true possible frequency of pathologies that may lead to delirium and this may be related to the low reported prevalence of delirium in this study. While delirium appears to be a common presentation in patients, especially in old age group, it's necessary to do more researches on this subject, with giving attention to longer study time, larger sample to be studied with varying demographic background and improved facilities for case detection including instruments for detecting mild cases

It can be concluded that Prevalence of delirium is reported to be low in comparison with other studies. This was explained by methods used in this study as only emergency cases with full blown picture of delirium might have been included in this study. This supposed fact was thought to be the cause for other differences with other studies such as type of symptoms and signs and causes reported in this study.

References

1. Lipowski ZJ. Delirium (acute confusional states). 1987 Oct 2; 258(13):1789-92.
2. American Psychiatric Association. *Diagnostic and Statistical Manual of Mental Disorders (DSM-IV-TR)*. 4th Ed. Washington, DC: American Psychiatric Association; 2000.
3. Lipowski ZJ. Delirium in the elderly patient. *N Engl J Med*. 1989 Mar 2; 320(9):578-82.
4. Liptzin B, Levkoff SE, Gottlieb GL. Delirium. *J Neuropsychiatry Clin Neurosci*. 1993 spring; 5(2):154-60.
5. Francis J, Kapoor WN. Delirium in hospitalized elderly. *J Gen Intern Med*. 1990 Jan-Feb; 5(1):65-79.
6. American Psychiatric Association. Practice guideline for the treatment of patients with delirium. *Am J Psychiatry*. May 1999.
7. Trzepacz PT. Delirium. Advances in diagnosis, pathophysiology, and treatment. *Psychiatr Clin North Am*. Sep. 1996.
8. Liptzin B, Levkoff SE. An empirical study of delirium subtypes. *Br J Psychiatry*. 1992 DEC. 161:843-854

9. Elie M, Cole MG, Primeau FJ, et al. Delirium risk factors in elderly hospitalized patients. *J Gen Intern Med*. 1998 Mar; 13(3):204-12.
10. Plaschke K, Hill H, Engelhardt R, et al. EEG changes and serum anticholinergic activity measured in patients with delirium in the intensive care unit. *Anaesthesia*. 2007 Dec; 62(12):1217-23.
11. Johanna C Korevaar, Barbara C van Munster Risk factors for delirium in acutely admitted elderly patients: a prospective cohort study. *BMC Geriatr*. 2005 Apr 13; 5:6.
12. Wakefield B, Johnson JA. Acute confusion in terminally ill hospitalized patients. *J Gerontol Nurs*. 2001 Apr; 27(4):49-55.
13. Kannayiram Alagiakrishnan, Simple cognitive testing (Mini-Cog) predicts in-hospital delirium in the elderly. *J Am Geriatr Soc*. 2007 Feb; 55(2):314-6

Evaluation of the effect of oral versus intravenous iron treatments on anemia in patients with chronic kidney diseases.

Arif Sami Malik *FICMS*.

Abstract

Background: Correction of anemia as a result of renal failure improves cardiovascular function and also provides significant cognitive and emotional benefits. The most appropriate route for iron supplementation has not been determined for patients with chronic renal failure who are not yet on dialysis.

Objective: It is to compare the efficacy and tolerability of oral and intravenous iron as an adjuvant therapy for erythropoietin treated anemic patients with chronic kidney disease in predialysis state.

Methods: Forty five anemic patients with chronic kidney disease were prospectively randomized to receive an oral (ferrous sulfate 200 mg three times daily), or intravenous (300 mg iron dextran/ monthly) iron treatment, the duration of treatment was six months. Erythropoietin (rHuEpo) was simultaneously commenced and the dose adjusted according to pre-established protocol.

Results: There were no significant differences in baseline patients characteristics between the two groups. Four patients suffered possible

allergic reaction to iron dextran. Hemoglobin response in the end of study was similar in two groups, but serum ferritin was significantly higher in the intravenous group. The starting dose of rHuEpo temporarily discontinued in the patients on oral iron and the patients receiving iron dextran rHuEpo was increased after 3 months, final doses on EPO were (33.5) and (41.6) units /Kg/week respectively in the oral and intravenous group. Although gastrointestinal symptoms were more commonly reported in patients taking oral iron.

Conclusions: In pre-dialysis patients; the efficacy of monthly 300 mg iron dextran administered intravenously is not superior in regard to haemoglobin response and EPO dose as compared with daily oral dose of 300 mg of ferrous sulfate or equivalent.

Key words: Chronic renal failure, Erythropoietin, Dialysis, Ferritin, Iron dextran

IRAQI J MED SCI, 2010; VOL.8 (4):47-52

Introduction

Anemia increases cardiovascular risk in patients with chronic renal disease⁽¹⁻³⁾. Left ventricular hypertrophy (LVH) is present in approximately three quarters of patients commencing dialysis and predicts mortality⁽⁴⁻⁶⁾. Correction of anemia has been shown to improve cardiovascular function with partial reversal of LVH^(7, 8). There are also cognitive and emotional benefits, which are reflected in improved quality of life scores^(9, 10).

Previous studies have demonstrated that recombinant EPO can improve anemia in patients with renal insufficiency that are waiting for dialysis treatment^(11, 12). The importance of adjuvant iron therapy has not been demonstrated as clearly as for dialysis population^(13, 15), and there have been calls for more detailed studies, particularly comparative trials to ascertain the relative efficacy of different methods of administration⁽¹⁶⁾.

Patients and Methods

This prospective study (interventional study) was carried out in the Al-Kadhimiya Teaching Hospital, department of Internal Medicine. Records of data for all patients whether outpatients or inpatients who were examined to identify individual need to identify individual with Chronic kidney disease (defined

Dept. Medicine, College of Medicine, Al-Nahrain University.

Address Correspondence to: Dr. Arif Sami,
E-mail: dr_arif31@yahoo.com

Received: 16th February 2010, Accepted:
14th June 2010.

as progressive deterioration in renal function with serum creatinine more than 250µmol/L) and worsening of anemia (defined as progressive reduction in hemoglobin concentration to a value of less than 11 gm/dl) , irrespective of gender⁽⁵⁶⁾. Patients who had been treated with IV iron during the previous 6 months were excluded from the study, other exclusion criteria were recurrent gastrointestinal bleeding , previous intolerance of oral iron, poor compliance with medication and allergic reaction to intravenous iron (2, 6,2 and 4 respectively). After obtaining informed consent patients, they were assigned to one of either treatment schedule. One group received an oral ferrous sulfate at dose of 200 mg t.d.s, and the other group received infusion of iron dextran (300 mg over two hours repeated monthly according to serum ferritin level). All patients received subcutaneous EPO. The intended duration of follow up was 6 months. Age, gender, and baseline biochemical, and hematological and serological studies to exclude collagen vascular disease and hepatitis screen were recorded. Measurement of Hb, serum ferritin, creatinine, and CRP, were repeated on monthly basis, three stool specimen were checked for faecal occult blood after three months and whenever there was clinical suspicion of gastro-

intestinal hemorrhage, rHu EPO treatment at adose of 2000 units was discontinued if Hb concentration of 14 gm/dl was exceeded and then re-introduced if values below 12 gm/dl were obtained with subsequent measurements, in cases where the Hb response to treatment was delayed (failure to achieve Hb above 12gm/dl within three months of starting treatment (resistant anemia), EPO was increased to 4000 units twice weekly after the third month, further increase of EPO to maximum dose of 4000 units three times weekly was made if monthly Hb concentration remained below 12 gm/dl, iron therapy was not interrupted unless serum ferritin estimation exceeded 500mg/l.

Results

Fifty nine patients were identified from a systemic review of record and case notes. , 10 patients were excluded because of (recurrent gastrointestinal bleeding 2, previous intolerance of oral iron therapy 6 and four were unable to give their informed consent (Figure 1). Baselines characteristics of the remaining 45 patients are summarized in table one. Twenty-three patients were assigned to a group for which the randomized treatment was oral iron therapy, and the remainder was assigned to a group for which the treatment was a monthly intravenous infusion of iron dextran.

Table 1: Baseline characteristics of treatment group.

	Group receiving oral iron (n=23)	Group receiving IV iron (n=22)
Age	59.9 ± 13.4 *	57.3 ± 14
Gender (M:F Ratio)	15:8	10:12
Haemoglobin (g/dl)	9.7 ± 1.3	9.9 ± 1.6
Ferritin (µg/l)	74 ± 25	100 ± 31

* Mean ± SD

Table 2: The main possible causes of chronic kidney disease

	Group receiving oral iron (n=23)	Group receiving IV iron (n=22)
Pyelonephritis	9	7
Polycystic kidney disease	2	4
Diabetic renal disease	5	0
Glomerular disease (biopsy wise)	1	2
Uncertain	6	9

Two of the included patients had previously commenced low dose of rHuEpo (weekly doses of 2000 and 3000 unit started approximately 4 months prior to enrolment). Both patients were randomized to receive oral iron treatment.

Patients were followed up for an average of 5.2 months. The reasons for an early withdrawal from the study were intolerance to oral iron or gastrointestinal bleeding.

During the study period, a mean of 0.91(0.84-0.98) infusions of iron dextran per patient per month were administered.

The overall response to iron therapy in the both study groups is in table 3. There was no statistical difference in Hb response 12.2(10.6-12.8) versus 12.5(11.6-13.3) g/dl at 6months of treatment in patients who took the oral and I.V groups respectively).

Hb of 12 g/dl was achieved within the first 3 months of treatment in 70% of patients taking an oral iron compared with 59% of patients receiving iron dextran.

Serum ferritin estimation was significantly higher in those receiving intravenous iron from the second

month of treatment 95 (63-149) versus 330 (186-423) µg/l at 6 months.

The initial Epo prescription of 4000U/week could be temporarily discontinued in 43% of the oral iron group vs 33% of the intravenous group after mean intervals of 2.4 and 2.7 months, respectively (NS). The rHuEpo was increased after 3 months in 9% of patients taking oral iron and 19% of patients receiving IV iron. Of those who completed 6 months of treatments, median finishing doses Epo were 33.5 (0-66) U/Kg/week and 41.6(0-124) U/Kg/wk, respectively, in the oral and IV groups, with higher mean and median values in the iron dextran groups for preceding months (figure 4). For patients who discontinued EPO temporarily, the median fall in Hb concentration in the first month after discontinuation for the study population as a whole was 1.1 (0.7-1.2) g/dl, with no significant difference between both treatment groups.

Faecal occult blood testing after 3 months gave uniformly negative results for the 31 patients who provided stool sample.

Table 3: Mean Hb concentration in oral and IV iron treatments.

Months	Mean of Hb concentration(g/dl) in oral iron	Mean of Hb concentration(g/dl) in IV iron
0	9.5	9.7
1	11	11
2	11.4	11.8
3	13	12
4	13.2	11.5
5	12.4	12.8
6	12.2	12.5
Calculated t = 0.3197		
P value = 0.7547		
Degree of freedom =12		
Statistical analysis: p value > 0.05, there is no significant difference between the two groups in mean of Hb concentration		

Table 4: Serum ferritin level in oral and IV iron treated patients.

Months	Serum Ferritin in oral iron	Serum Ferritin in IV iron
0	80	102
1	50	105
2	45	150
3	45	190
4	72	280
5	100	286
6	96	327
Calculated t =3.7839		
p value = 0.0026		
Degree of freedom =12		
Statistical analysis: p value < 0.05, there is significant differences between the two groups.		

Discussion

Early correction of renal anemia is desirable, although the evidence-based for recommending a target Hb, a means of achieving it, has not been firmly established. It has previously been reported that IV iron has greater additive effect with EPO than has oral iron, perhaps as a result of reduced iron absorption from the gut⁽¹⁸⁾, and poor patient compliance with oral medications. Silverberg et al.⁽¹⁹⁾, reported a mean rise Hct of 1.9 vol %

(0.6 g/dl), for dialysis patients not receiving EPO in whom iron dextran (200mg monthly for 5 months) was substituted for oral iron. Later study showed that approximately one third of patients with chronic renal failure achieved Hct of 35% using iron dextran without EPO⁽²⁰⁾.

Individual response to iron could not be predicted from laboratory measurements such as serum creatinine, ferritin, or iron saturation,

The same group has administered more than 20000 mg infusion of iron dextran without complication. Other groups have reported infrequent symptoms with doses of 100⁽²¹⁾ and 200 mg⁽²²⁾ of iron dextran including chest pain, loin pain, and bronchospasm.

The aim of this prospective study was to directly compare the efficacy & tolerability of oral and IV iron as adjuvant therapy for EPO treated anemic patient with chronic renal failure.

The Hb response to EPO and iron was similar with oral and IV iron, a finding that runs contrary to the aforementioned reports but is consistent with observation of Anstasiades et al.⁽²³⁾

There were few limitations affect the results of the current study, the small sample, the adequacy of dialysis and the findings of high prevalence of anemia and malnutrition among our patients

In pre-dialysis patients; the efficacy of monthly 300 mg iron dextran given intravenously is not superior in regard to haemoglobin response and EPO dose as compared with daily dose of oral 600 mg of ferrous sulfate or equivalent.

References

1. Levin A, Singer J, Thomson CR. Prevalence of left ventricular hypertrophy in pre dialysis population: identifying opportunities for intervention. *Am J Kid Dis* 1996; 27:347-354.
2. Levin A, Thomson CR, Carlisle E. Left ventricular mass index growth in early renal disease: impact of decline in hemoglobin. *Am J Kid Dis* 1999; 34:125-134.
3. NKF-DOQI WORK GROUP. NKF-DOQI clinical practice guidelines for the treatment of anemia in chronic renal failure. *Am J Kid Dis* 1997;30(supple 3): S 192-S240.
4. Mann JFE. What are the short term & long term consequence of anemia in CRF patients' *nephrol dial transplant* 2004; 14(supple 18):29-36
5. Silberberg JS, Rahall DP, Patton R, Sniderman AD. Role of anemia in the pathogenesis

of LVH in end stage renal disease. *Am J Cardiol* 1999; 94:222-224

6. Foley RN, Prfrey PS, Harnett JD. The prognostic importance of the left ventricular geometry in uremic cardiomyopathy. *J Am Soc Nephrol* 1995;5:2024-2031
7. Wizemann V, Schafer R, Kramer W. Follow up of the cardiac changes Induced by anemia compensation normotensive hemodialysis patients with left ventricular hypertrophy. *Nephron* 2003; 64: 202-206
8. Fellner SK, Lang RM, Neumann A, Kocacz C, Borow KM. Cardiovascular consequence of the correction of anemia of renal failure with erythropoietin. *Kidney Int* 1993; 44:1309-1315
9. Moreno F, Lopez Comes JM, Sanz Guajardo. Quality of life in dialysis patient. Spanish multicenter study. *Nephrol Dial Transplant* 2006; 11(Supple 2):125-129
10. Beusterian KM, Nissenson AR. The effect of recombinant human erythropoietin on functional health & well being in chronic dialysis patient. *J Am Soc Nephrol* 1996; 7:763-773
11. The US recombinant Human Erythropoietin predialysis study group. Double Blind, placebo controlled study of the therapeutic use of recombinant Human Erythropoietin for anemia associated with CKD in pre-dialysis patient. *Am J Kid Dis*, 2001; 138:50-59
12. Koch KM, Koene RAP. The use of epoetin beta in anemic pre-dialysis patients with chronic renal failure. *Clin Nephrol* 1995; 44:201-208
13. Drueke TB, Barany P. Management of iron deficiency anemia in renal anemia; *Clin Nephrol* 1997;48:1-8
14. Fishbane S, Frei GL. Reduction in recombinant human erythropoietin doses by the use of chronic intravenous iron supplementation. *Am J Kid Dis* 1995; 26:41-46
15. Macdougall IC, Hutton RD. Poor response to treatment of renal anemia with erythropoietin by iron given intravenously. *BR Med J* 2006; 299:157-158
16. Levin A. How should anemia be managed in pre-dialysis patient, *Nephrol transplant* 1999; 14 : (Supple 2) 66-74
17. Boddy K, Lawson DH. Iron metabolism in patient with chronic renal failure. *Clin Sci* 2003; 124:115-121
18. Silverberg DS, Iaina A. Intravenous iron supplementation for the treatment of anemia of moderate to severe chronic renal failure in patient not receiving dialysis. *Am J Kid Dis* 1996; 27:234-238

19. Silverberg DS Blum M. Intravenous iron for the treatment of pre-dialysis anemia. *Kidney Int* 1999; 55(Supple 69):79-85
20. Sounder-Plassmann G, Importance of iron supply for erythropoietin therapy *Nephrol Dial Transplant* 1995; 10:2070-2076
21. Jones CH, Richardson D. Percentage of hypochromic red cells & response to intravenous iron therapy in anemic haemodialysis patient, *Nephrol Dial Transplant* 1998 ;13:2873-2876
22. Anastassiades EG, Howarth D. monitoring of iron requirement in renal patients on erythropoietin. *Nephrol Dial Transplant* 1993; 8:846-853
23. Macdougall IC, Cavill I .Detection of functional iron deficiency during erythropoietin treatment: new approach. *Br Med J*, 2002; 304:225-226.

Polythelia: Anatomic and clinical implications.

Mohammad O. Selman *MBCChB; FIBMS.*

Abstract

Background: Polythelia or supernumerary nipple (also called third or accessory nipple) is an additional nipple occurring in mammals including humans. These additional nipples develop during embryonic life as part of abnormal development of mammary glands.

Objectives: To describe the polythelia and its most frequent locations also to give a perspective of polythelia in a series of observations. And lastly to assess if there is any genetic inheritance present.

Methods: Forty three cases of polythelia were collected from attendants of general practice clinic in Baghdad. The polythelia was observed during routine physical examination, which included examination of the chest and abdomen.

Results: From 43 cases of polythelia, males constituted 23 (53.5%) of cases. Regarding the anatomical location of polythelia, 2(4.65%) were on the anterior axillary fold, 28(65.1%)

on the anterior thoracic wall, 12(27.9%) on the anterior abdominal wall and one (2.3%) was in the inguinal region. Only five cases (11.6%) had family history of previous similar conditions.

Conclusion: Polythelia is a fairly common abnormality. Men and women may have extra nipple, but no significant difference was detected that can be related to gender difference. Nevertheless presence of extra nipples was sometimes linked to heart disease, no such relationship was noticed. All cases in this study had their polythelia along the milk line. Nevertheless, there had been reports on polythelia presenting as far away as the foot.

Keywords: polythelia, mammary gland, Supernumerary nipple.

IRAQI J MED SCI, 2010; VOL.8 (4):53-56

Introduction

Polythelia or supernumerary nipple (also called third or accessory nipple) is an additional nipple occurring in mammals including humans. These additional nipples develop during embryonic life as part of abnormal development of mammary glands⁽¹⁾.

The first indication of mammary glands is found in the form of a band like thickening of epidermis along the mammary line or mammary ridge. In a 7-week embryo this line extends on each side of the body from the base of the forelimb to the region of the hind limb. Although the major part of the mammary line disappears shortly after it forms, a small portion in the thoracic region persists and penetrates the

underlying mesenchym. Here it forms 16 to 24 sprouts, which in turn give rise to small, solid buds. By the end of the prenatal life, the epithelial sprouts are canalized and form the lactiferous ducts, and the buds form small ducts and alveoli of the gland. Initially the lactiferous ducts open into a small epithelial pit. Shortly after birth, this pit is transformed into the nipple by proliferation of underlying mesenchyme⁽²⁾.

Polythelia refers to the presence of an additional nipple alone while polymastia denotes the presence of additional mammary gland. Polythelia often looks like moles or freckles and do not always have a connection with breast tissue or milk ducts⁽³⁾.

Polythelia is classified into eight levels of completeness from a simple patch of hair to a milk bearing breast. This study will investigate the condition of polythelia as regards the anatomical location of the additional nipples, the presence of family history

Dept. Human Anatomy, College of Medicine, Al-Nahrain University.

Address Correspondence to: Dr. Mohammad O. Selman,

E-mail: mohammadoda@yahoo.com

Received: 8th June 2010, Accepted: 25th August 2010.

of such condition in the first and second degree relatives, gender differences and the possible relation to other diseases⁽⁴⁾.

Material and Methods

This study was performed on 43 cases with polythelia. They were collected from attendants of general practice clinic at Baghdad. The polythelia was observed during routine physical examination, which included examination of the chest and abdomen. Once observed, detailed information were recorded about the condition in a study form which includes:

- Personal data of name and residence
- Age and gender
- Physical examination of the condition, included inspection, palpation and fluctuation test for presence of fat. Data regarding presence of glandular tissue, nipple, pigmented areola, fatty tissue and presence of hair.
- The anatomical position was recorded as being on anterior axillary fold, thoracic wall, anterior abdominal wall and the inguinal region (groin).
- Presence of similar condition in family, including first and second degree relatives.

- Presence of other notable systemic diseases.

Results

The total number of cases enrolled in this study was 43. The age was very variable; however most of observed cases were in 3rd or 4th decade of life. Males constituted 23(53.5%) cases and females were 20(46.5%).

Regarding the anatomical location of polythelia, 2(4.65%) were on the anterior axillary fold, 28(65.1%) on the anterior thoracic wall, 12(27.9%) on the anterior abdominal wall and one (2.3%) was in the inguinal region (Table 1).

Regarding the family history of such condition in first degree relatives (parents and offspring) and second degree relatives (brothers and sisters) only five (11.6%) had such family history.

No notable systemic diseases were recognized in these cases who were seeking medical consultation for no major systemic disease.

Careful inspection was done for the condition and palpation was performed to detect underlying glandular tissue. Two fingers fluctuation test was done to identify fatty material if a lumpy structure was present.

Table 1: Sites of polythelia (supernumerary nipples) in mammals including humans

Total number (43)		Sites of polythelia			
Gender		AAW	AAF	ACW	IR
male	23 (53.5%)	12 (27.9%)	2 (4.65%)	28 (65.1%)	1 (2.3%)
female	20 (46.5%)				

The abbreviations: AAW: Anterior abdominal wall, AAF: Anterior axillary fold, ACW: Anterior chest wall and IR: Inguinal region.

Discussion

The aim of this study was to give a perspective of the condition of additional nipple or polythelia in a series of observation. According to our observations, polythelia is a fairly

common abnormality. It is proposed that this type of congenital abnormality occurs at rate of 1 in 18 human⁽⁵⁾.

Larger study is required to investigate the prevalence of this

condition since many mistake it as mole, navus, freckle or pigmented skin condition. Men and women may have extra nipple. In this work no significant difference was detected that can be related to gender difference.

All the cases included in this study had no glandular tissue, so they were not polymastia. The observed additional nipples can be designated as pseudo mamma when they possess a nipple, areola and fat tissue.

They are considered classical polythelia when they are just a nipple. Polythelia areolaris, when only an areola is present and polythelia pilosa when it consists of a conglomerated patch of hair⁽⁶⁾.

From the anatomical point of view, the most frequent location of polythelia is the thorax. Commonly an additional nipple was found to be present inferior and medial to the location of the genuine nipple.

The second most common site was on the anterior abdominal wall. Other sites observed were along the anterior axillary fold and above medial inguinal region.

All cases in this study had their polythelia along the milk line. Nevertheless, there had been reports on polythelia presenting as far away as the foot⁽⁷⁾.

The development of breast is under genetic control, and the gene coding for this process is called Scaramanga gene. This gene is responsible for the expression of a protein called Neuregulin-3 (NRG3) which provides a signal to embryonic cells to differentiate into mammary cells⁽⁸⁾. Although polythelia tends to occur sometimes in families⁽⁹⁾, it is more likely to develop at random. Only five cases with familial background in the form of the presence of polythelia was found in first and second degree relatives, in the whole study group. This finding does not support a genetic

inheritance or predisposition to this condition.

In this study no concomitant pathological conditions with polythelia were found and unable to link it to other disease entities. Nevertheless presence of extra nipples was sometimes linked to heart disease, and a possible relationship with mitral valve prolapse had been proposed⁽¹⁰⁾, no such relationship was noticed in the study group.

However in general any breast tissue, whether it appears in the standard location or elsewhere is vulnerable to the same diseases that can affect typical breast tissue. Extra mammary Paget's disease of the nipple can affect these additional nipples⁽⁶⁾.

In most people, extra nipples are benign and may never be noticed. But if they change, develop a lump, rash or discharge, they should be taken seriously, otherwise polythelia may be surgically removed, just like a mole.

In western folklore, an extra nipple was held to be indicative that the women concerned was a witch, the nipple used to suckle the devil!

References

1. Fuchs E. Epidermal differentiation: the bare essential. *J. Cell Biol.* 1990; 111: 2807-2815.
2. Sadler TW. *Langman's Medical Embryology* 11th. Edition. Lippincott, Williams & Wilkins. 2010; pp. 431-432
3. Rapini RP. Boolognia JL & Jorizzo JL. *Dermatology* st. Louis. Mosby, 2007.
4. Newman M. Supernumerary nipples. *Am. Fam. Physician*, 1988; 38:183-188.
5. Beller F. Development and anatomy of the breast. In Mitchell: GWJr, Bassett (eds): *The female breast and its disorders*. Baltimore. Williams & Wilkins, 1990.
6. Ostas MO & Gurer MA. Dermoscopic features of accessory nipples. *International Journal of Dermatology*, 2007; 46/10:1067-1068. Published Online.
7. "Pseudomamma on the foot: An unusual presentation of supernumerary breast tissue". http://dermatology.cdlib.org/124/case_presentations/pseudomamma/conde.html. Retrived 2007-12-03

8. Howard BA. The role of NRG3 in mammary development. *J. Mammary Gland Biol. Neoplasia*, 2008; 13/2: 195-203. Published Online.
9. Galli-Tsinopoulou A, Krohn C and Schmidt H: familial polythelia over three generations with polymastia in the youngest girl. *Eur.J.Pediatr*, 2002; 160(6): 375-377.
10. Rajaratnam K, Kumar PD, Sahasvanam KV: Supernumerary nipple as a cutaneous marker of mitral valve prolaps in Asian Indians. *Am. J. Cardiol*, 2000; 86/6: 695-697.

Assessment of color alteration of heat polymerized resin by visual inspection and spectrophotometer after immersion in chemical denture cleanser.

Israa Mohammed Hummudi MSc, Ala'a Ezzat Abdul Majeed MSc.

Abstract

Background: Denture cleanser should be designed to remove and prevent re accumulation of microbial plaque. Cleaning the denture by chemical immersion have several advantages that solutions reach all areas of the denture and results in complete cleaning. One problem associated with their use has been bleach and discoloration the surface layer of acrylic dentures.

Objective: to assess the color alteration of heat polymerized acrylic resin after immersed in different types of chemical denture cleanser.

Method: forty five rectangular specimens (50x3.5x3mm) (length-width-thickness) of heat activated acrylic resin were divided in three denture cleansers groups (sodium hypochlorite NaOCl 0.5%) and vinegar (acetic acid 6%) and control group (immersed in distal water). Soaking trial 8 hours simulated 30 days of use. Color alterations were assessed by

visual examination of photographs and by spectrophotometer testing device.

Results: the results of spectrophotometer testing device did not show any interaction between different type of chemical cleansers and acrylic resin during 30 days 8 simulated use, also visual examination did not detect any color alteration.

Conclusion: denture clearers, when used according to the manufacturer's instructions, did not cause any mechanical or visual alterations in the heat polymerized acrylic resin.

Keywords: Acrylic resin – denture cleanser-color changes.

IRAQI J MED SCI, 2010; VOL. (4):57-64

Introduction

Acrylic resins have been used to produce dentures for more than 60 years. Heat activated acrylic resin is the most common type used for construction of denture base⁽¹⁾. Dentures can be cleaned mechanically, chemically or by the combination of both methods. Mechanical methods are the most common way for bio film removed from denture surfaces⁽²⁾. The use of chemical cleansers is usually associated to its efficacy in removing stains and bio film formation on the dentures⁽³⁾. The most commonly used cleansers are represented by the group of alkaline hypochlorite.

NaOCl solutions have been used for along times as denture cleansers and several regimes have been proposed^(4, 5).

Nevertheless, the effect of those solutions on the properties of denture base acrylic resins can be influenced by some factors which were not still evaluated. Several studies assessed NaOCl as a disinfecting agent for dental clinics to reduce cross contamination of dentures, and used high concentrations during short times⁽⁶⁻⁸⁾.

The use of vinegar (acetic acid) solution was evaluated by (Bassoon et al, 1992)⁽⁹⁾, who found it effective at killing adherent micro organisms although less effective than bleach solution.

One advantage of vinegar over bleach is that in adequate rinsing after soaking in vinegar dose not result in mucosal damage⁽¹⁰⁾.

College of Health and Medical Technology.
Address Correspondence to: Israa
Mohammed Hummudi,
E- mail: tualin 1112006@yahoo.com
Received: 4th April 2010, Accepted: 15th
August 2010.

Factors like water temperature and immersion period are considered critical when complete denture cleansers are used, sometimes, the prostheses need to replace due to the patients abuse of hygienic methods^(4, 6, 11, 12).

Denture base materials can be damaged if the cleaning agents are not used according to the manufacturer's instructions^(12, 13).

The importance of following the manufactures instructions is emphasized because the transverse strength of acrylic resins depends on several factors such as polymer bead size⁽¹⁴⁾, amount of cross linking agents⁽¹⁵⁾, type of polishing and action of chemical agents⁽¹⁶⁾.

One of the problems frequently reported by chemical cleanser users is a whitening effect on the denture. Denture base polymers are susceptible to color changes if the cleaning solutions are not used correctly⁽⁶⁾. The whitening effect is related to the high temperature of water used in the solution^(11, 13).

When peroxide based cleansers are used in a warm water solution as recommended by the manufacturer, no deleterious effects on correctly processed denture acrylic have been found⁽¹⁷⁾.

It is of clinical importance to determine whether chemical solutions or denture cleansers alter the acrylic resins color when dentures are cleaned repeatedly and for various amounts of time⁽⁴⁾. Therefore the aim of this study was to evaluate whether soaking of heat polymerized acrylic resins in chemical solution (NaOCl, vinegar) may affect the resin color when subjected to the recommended instructions of the use for a simulated period of 30 days.

Materials and methods

Specimen's preparation

Heat cures acrylic specimen's preparation:

Wax plate 50x3.5x3 mm in dimensions was prepared and fixed into flat glass plate. Stone slurry was prepared (33ml water/100gm powder) and poured in the lower half of flask before the stone in the lower half of the flask was harden, the glass plate, which is larger than the surface area of the flask, was loaded and wax plate placed over the stone, so that the level of the wax plate would be with level of the stone. When the stone reached its initial set, it was coated with the separating medium (cold mold seal), than the upper half of the flask was positioned on the lower half and a second mix of dental stone was poured into the flask and kept under the hydraulic press, after completing the setting of the stone, wax elimination, was done by immersing the flask in the boiling water for 4 minutes, then the flask was opened, washed with boiled water to remove the remaining wax. Then it was allowed to cool, the flask opened again and the surface of the mold was coated with the separating medium.

Heat cure acrylic powder was mixed with the liquid in a proper polymer-monomer ratio of 3:1 (v: v) for 45 second at room temperature, the container was left until it reached the dough stage. The mixture was packed into the stone mold, covered with polyethylene sheet, the two halves of the flask were closed together, and then the flask assembly was placed into the hydraulic press 20 bars to allow the resin dough to flow evenly throughout mold, the flask was opened, the flow material and the polyethylene separating sheet was removed. Then the halves of the flask were finally closed together, press metal to metal contact and held for 5 minutes before

clamping was done. The flask was transferred to a thermostatically controlled water bath for curing the acrylic denture base resin. The fast technique involves processing the resin at 74C° for 1.5 hours and then increases the temperature of the water bath to boiling for an additional 1 hour⁽¹⁾. Following the completion of polymerization cycles, the flask was removed from the water bath and left on the bench to cool for 30 minutes subsequently; the flask should be immersed in cool tap water for 15 minutes.

Finishing of the acrylic resin specimens:

The acrylic plates were then removed from the flask and trimmed with tungsten bur then finished using progressively finer grades of silicon carbide paper (grades 120 to 40 um), pumice and rouge were used for final polishing. All specimens were stored in water at 50C° for 1 hour to remove the excess of residual monomer and then stored at room temperature until the time of the soaking trials.

Specimens grouping:

Forty five samples were divided into three groups:-

Group one: 15 specimens immersed in distilled water (control)

Group two: 15 specimens immersed in sodium hypochlorite 0.5%

Group three: 15 specimens immersed in vinegar (acetic acid) 6%

Soaking trials

Fifteen specimens of each resin were subjected to the soaking trials⁽¹⁸⁾:-

8-hour intervals for up to a total 240h , changing the solution every 8 hours, to correspond 30 over right soaking periods. The control specimens were stored in distilled water at room temperature, changing the water every 8 hours.

Analysis of treated specimens

The study specimens were analyzed by fourier transform infrared spectrophotometer (FTIR) Shimadzu-Japan. (Figure 1).

Spectrophotometric analysis of color of acrylic denture base material, before and after time of immersion in different denture cleanser was conducted. All specimens were dried, then treated with potassium bromide in a percentage of 1:100 then grinded as a powder and converted to a disk like by press. Each disk was fixed on the flat plate to become ready for scanning. The mode of action of this device is by reading the chemical composition of each specimen at specific area and the solution in which it was immersed. the reading appears as a diagram and each number in diagram was represented by peak.

Visual inspection:-

The control specimens stored in distilled water and specimens immersed in two denture cleansers, using daily soaking times 8 hours for a period of 30 days were put side by side and photographed camera (SONY DCR-SR 46E, 40GB, 40optical zoom, Tokyo-Japan)

Film was processed and visual inspection of photographs of the specimens was carried out independently by three examiners blinded to the resins, denture cleansers and immersion to assess the occurrence of alteration in the resins. Each examiner received an initial photograph of the non-treated resin specimens (used as control and compared to the photograph of the treated specimens.

Yes or no answers were given depending on the presence or absence of color change. (Figure 2, 3)



Figure 1: Spectrophotometer testing device

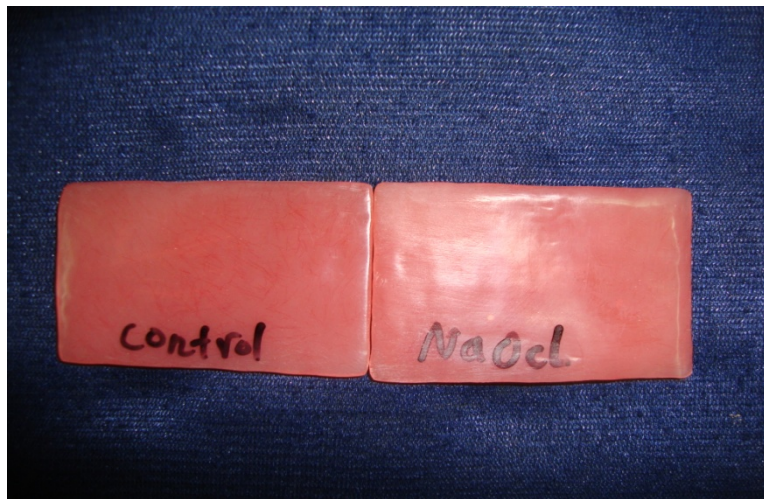

Figure 2: Photographs of specimens Immersed in distilled water and NaOCl

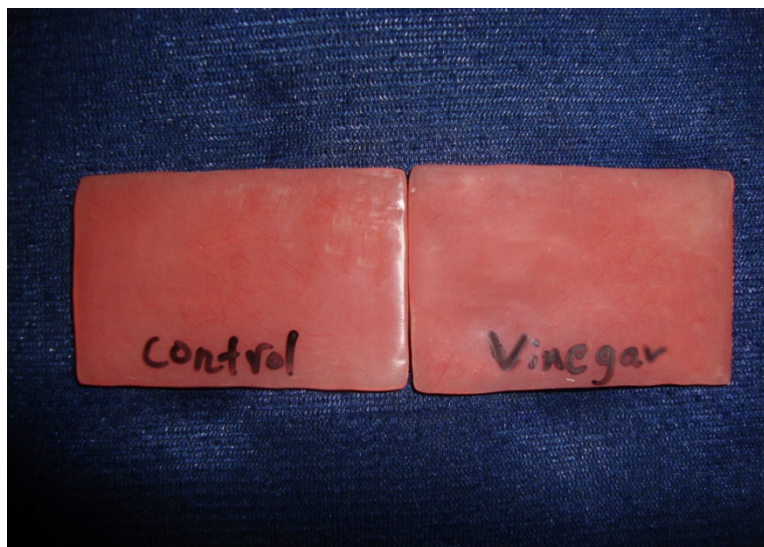

Figure 3: Photographs of specimens Immersed in distilled water and Vinegar

Results

The results of this study are qualitative which depends on the reading of each diagram. Spectrophotometer device did not show any differences between each diagram after matching with each other.

There were no changes between e readings of Figure (4) (specimens

before time of immersion) and Figure (5) (specimens immersed in distilled water). Also there is no differences between Figure (5) with Figure (6) (specimens immersed in NaOCl) and Figure (7) (specimens immersed in vinegar).

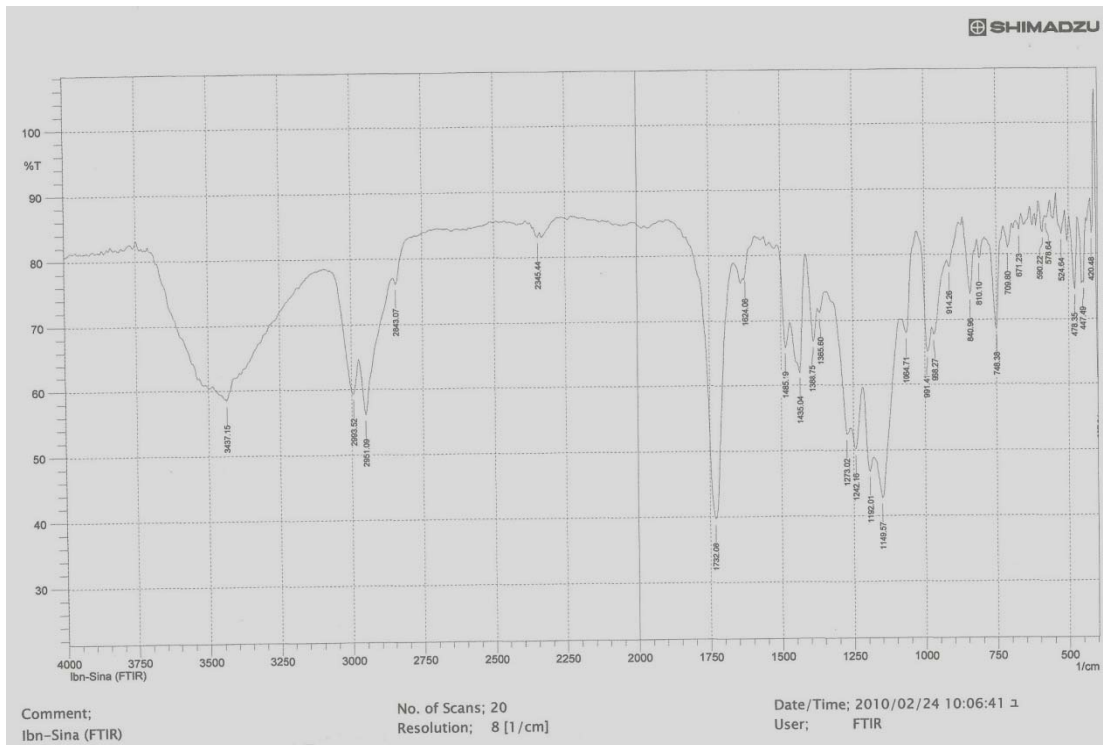


Figure 4: Diagram of specimen before time of immersion

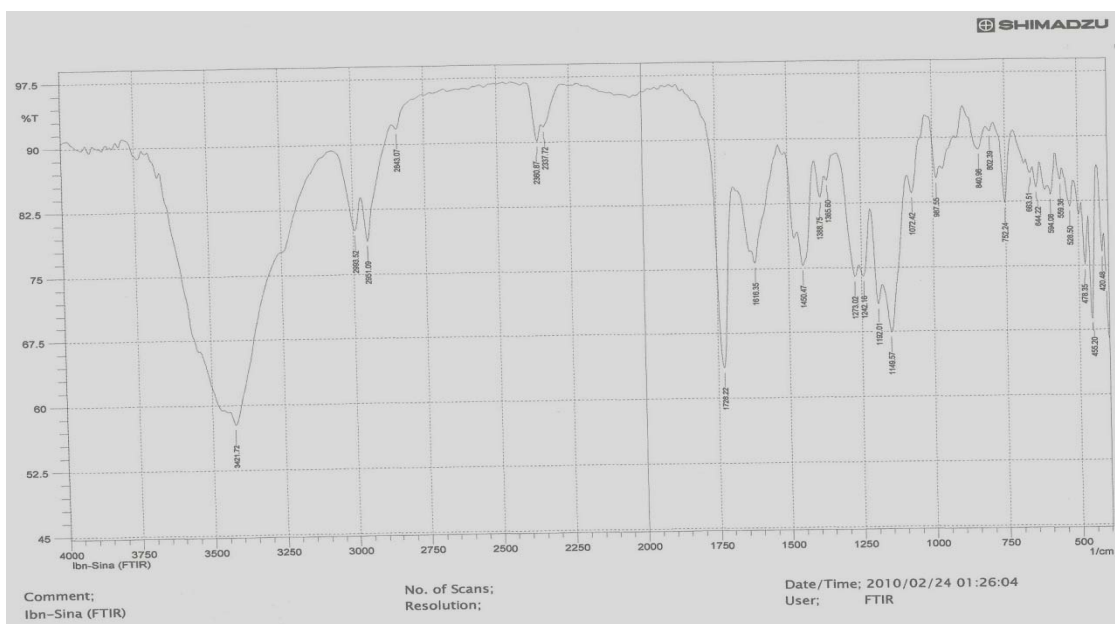


Figure 5: Diagram of specimen immersed in distilled water

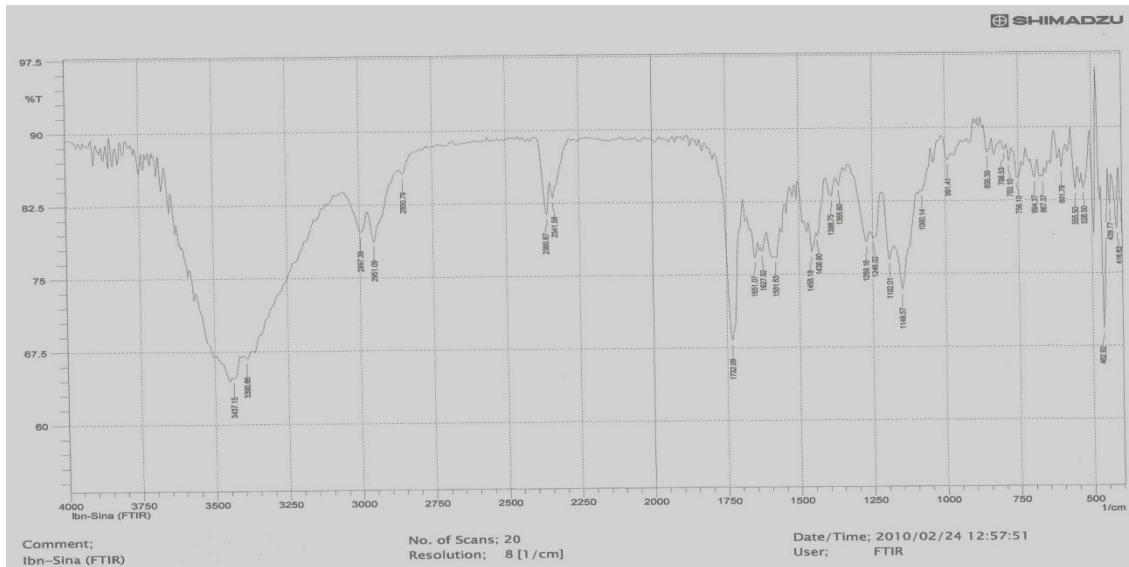


Figure 6: Diagram of specimen immersed in NaOCl

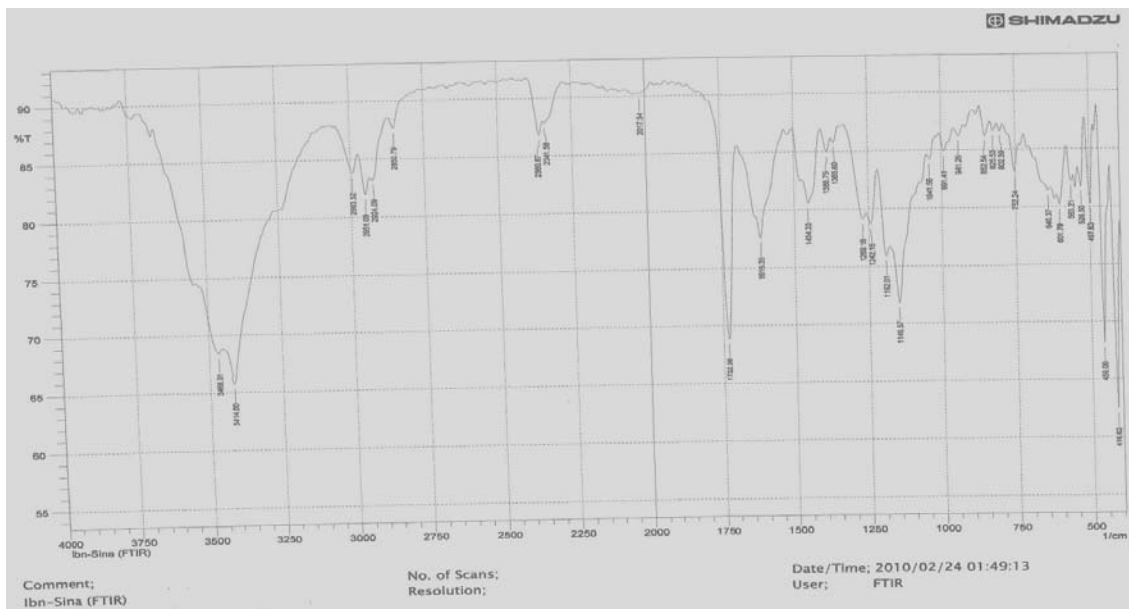


Figure 7: Diagram of specimen immersed in vinegar

The vertical line of diagram represents the transmission (T%) and the horizontal line represents the range (cm^{-1}) Comparison between diagrams in figs. 5,6,and 7shows that there was no differences in the readings , means no interaction between chemical solution and acrylic in specimen as shown in a diagram: (each reading susceptible to ± 10 degree) .

No clinically significant color alterations were observed on examination of the photographs.

Discussion

It has been shown that brushing alone is not sufficient for good denture biofilm control and hence chemical cleaning is usually associated to mechanical cleansing to complement denture hygiene, moreover denture immersion in chemical products aims to provide cleaning and decontamination. It is important to analyze the efficacy of the cleaning product and how it acts on the denture materials⁽¹⁹⁾.

The daily immersion of the removable prostheses in commercial

bleaching agents is indicated for domestic use because it is an inexpensive and simple hygiene method⁽²⁰⁾ combining NaOCl solutions with a water softener solution is recommended for daily hygiene of complete dentures^(21,22).

The rationale for adding a water softener is the improvement in the removal of heavier deposits or stains by means of chelating action⁽²¹⁾.

Factors that may contribute to the change in color of materials include stain accumulation, dehydration and oxidation of the reacted carbon-carbon double bonds that produces colored peroxide compounds and continuing formation of the colored degradation products⁽²³⁾.

Previous investigations have emphasized that the correct use of chemical cleansers is not associated to alteration in the mechanical and chemical properties of the materials for denture bases.^(11,12,13) However, another factor to be taken into account is the immersion time, as extended immersion can damage certain materials used to manufacture the prostheses⁽²⁴⁾. 8 hour periods (extended or overnight immersion-during sleep period) were established to simulate the orientations patients received for the daily cleaning of total prostheses. The results showed that, even within an 8 hour period, no alteration occurred in the analyzed characteristics.

In this study color alteration can be measured by two methods spectrophotometer and visual inspection. The results of spectrophotometer showed that no color changes of that polymerized specimens immersed in sodium hypochlorite. This may be weak concentration solution 0.5% so that the liberated oxygen did not cause oxidation of tertiary amine accelerator. This result is in agreement with

McNeme et al and Polyzois et al⁽⁴⁾. Both studies did not find color changes in the acrylic resin after the use of NaOCl but disagreed with Kazangi and Ahmad⁽²⁵⁾.

Acidic denture clearers (vinegar) did not show color changes of heat cure acrylic denture base resin. This finding was disagreeing with the results of Kazangi and Ahmed⁽²⁵⁾.

The results of visual examination did not show any noticeable color change with the use of NaOCl and vinegar after a soaking of 30 days. The denture cleanser tested in this study were used according to the manufactures instruction did not cause the whitening effect observed in some dentures soaked in chemical solution. These findings are in consistent with the previous investigations which attributed the whitening effect on chemically cleansed acrylic resin denture bases to the excessively high temperature of the water rather than to the denture cleanser itself^(17,18).

It may be concluded that, when used according manufactures specification, denture cleansers did not cause alteration or color changes in heat polymerized acrylic resin after 30 days of simulated use.

References

- 1- Craig RG, Powers JM, Wataha JC. Dental materials properties. Properties and manipulation 8th mosby year book inc 2004.
- 2- Panzeri H, Lara EH, Paranhos H de F, Lovato da Silva CH, de Souza RF, de Souza Gugelmin Mc. In vitro clinical evaluation of specific dentifrice for complete denture hygiene. Gerodontology 2009; Mar 26(1):26-33.
- 3- Paranhos HFO, Silva-lovato CH, Souza RF, Cruz PC, Freitas KM, Peracini A. Effects of mechanical and chemical methods on denture biofilm accumulation. J Oral Rehabil. 2007; 34: 606-612.
- 4- Haywood J, Wood DJ, Gilchrist A, Basker RM, Watson CJ. Changes in color of denture relined materials following immersion in three commonly used denture cleansers. Eur J Prosthodont Restor Dent 2003; Dec 11 (4):156-9.
- 5- Barnabe W, Mendonca Neto T, Pimento FC, Pegoraro LF, Scolaro JM. Efficacy of

sodium hypochlorite and coconut soap used as disinfecting agents in the reduction of denture stomatitis, *strepto coccus mutans* and *condida albicans*-J Oral Rehabil 2004; 31:453-59.

6- Hong G, Murata H, LiY Sadamori S, Hamada T. Influence of denture cleanser on color stability of three types of denture base acrylic resin. J Prosthet Dent 2004; Mar 101(3):205-13.

7- Pararina AC, Machado AL, Giampaolo ET, Yergani CE. Effects of chemical disinfectants on the transverse strength of denture base acrylic resins. J Oral Rehabil 2003; 30:1085-1089.

8- Azevedo A, Mochado LA, Yergani CE, Giampaolo ET, Pararina AC, Magnani R. Effect of disinfectants on the hardness and roughness of relined acrylic resins. J Prosthodont 2006; 15: 235-242.

9- Bassoon NJ, Quick AN, Thomas CJ. Household products as sanitizing agents in denture cleansing. J Dent Assoc. S. Africa. 1992; 47:437.

10- Shay K. Dental Hygiene: A review and update J Contemp Dent Pract. 2000; Feb 1 (2), 28-41.

11- Pinto TM, Neves AC, Leao MV, Jorge AO. Vinegar as antimicrobial agents for control of *Candida spp* in complete denture wearer J Appl Oral Sci 2008; Nov-Dec 16(6):385-90.

12- Dinkal Yanikoglu N, Yesil Duymus Z. Comparative study of water sorption and solubility of soft lining materials in different solutions. Dent Mat J 2004; Jun 23(2):233-9

13- Lun CY, Dravell BW. Minimization of inevitable residual monomer in denture base acrylic. Dent Mat. 2005; Dec 21(12):1119-28

14- Jagger D, Harrison A, Jagger R, Milward P. The effect of addition of PMMA fiber on some properties of high strength heat cure denture base material. J Oral Rehabil 2003; Mar 30(3):231-5.

15- Memon MS, Yunus N, Razak AA. Some mechanical properties of highly cross-linked microwave polymerized denture base polymer. Int J Prosthodont 2001; May-Jun 14(3):214-8

16- Orsi IA, Andrade VG. Effect of chemical disinfectants on the transverse strength of heat polymerized acrylic resins submitted to mechanical and chemical polishing. J Prosthet Dent. 2004; 1992:382-388.

17- Satos, Cavaleante MRS, Orsi IA, Paranhos HFO, Zaniquelli O, Assessment of flexural strength and color alteration of heat polymerized acrylic resin after simulated use of denture cleansers. Braz. Dent J. 2005; 16:124-128.

18- Paranhos HFO, Orsi IA, Zaniquelli O, Candelas MC, Magalhaes E. Effect of chemical denture cleansers on flexural resistance and color changes of micro wave – polymerized acrylic resins. Braz J Oral Sci 2008; 7 (26): 1580-1584.

19- Garcia RCMR, Souza JR JA, Reched Mn, Del Bel Cury A.A. Effect of denture cleansers on the surface roughness and hardness of micro wave – cured acrylic resin and dental alloys. J Prosthodont 2004; 13: 173-178.

20- Key PF, Gungor T. Comparison of effects of bleach and tablet on reflectance and surface changes of dental alloy used for removable partial dentures J Biomater Appl. 2003; 18:5-14.

21- Ribeiro DG, Pavarina AC, Dovigo LN, Polomari Spolidorio DM, Giam Paolo ET. Denture disinfection by microwave irradiation Dent 2009; Sep 37(9):666-72.

22- Pavarina AC, Pizzolitto AC. Effectiveness of immersion solution to reduce microbial growth on dental prosthesis, J Oral Rehabil 2003; May 30(5):532-6.

23- Jir C, Nikawa S, Makihira S, Hamada T, Furukawa M, Murata H. Changes in the surface roughness and color stability of soft denture lining materials caused by denture cleansers. J Oral Rehabil. 2003; 30:125-130.

24- Jagger DC, Al-Akhhazami L, Harrison A, Rees JS. The effectiveness of seven denture cleansers on tea stains removal from PMMA acrylic resin. Int J Prosthodont. 2002; 15:549-552.

25- Kazanji MN, Ahmad ZM. Evaluation of the effect of some denture cleansers on the color of acrylic resin denture base materials Al-Raffidain Dent. J. 2004; 4 (2):79-85.

Clinical evaluation of low level laser therapy in skin wound healing in maxillofacial surgery.

Ammar Salih Al-Alawi MSc, Hussain A. Jawad PhD, Ayad M. Ismael FDSRCS.

Abstract

Background: Wound healing is a complicated, interactive, integrative process involving cellular and chemotactic activity, the release of chemical mediators and associated vascular response which includes number of phases: inflammatory phase, proliferative phase and remodeling phase. Low level laser therapy can be more effective in the three overlapping phases of wound healing. Biostimulation appears to have an effect on the cellular level, by increasing cellular function and stimulating various cells.

Objective: To evaluate the efficacy of low level diode laser on wound healing of human skin clinically.

Patients and Methods: This study was performed on 20 patients (10 male, 10 female) age range between 5-75 years with oral and maxillofacial lesions underwent maxillofacial surgery with low level laser therapy. After the surgical intervention, the wounds were divided into two parts, one part was irradiated by 1.25 W/cm²

power density, 50 sec. exposure time low level diode laser and other part was left as a control. The postoperative course was evaluated based on subjective scale of edema, redness at 2nd -5th day postoperatively.

Results: Clinical evaluation of edema and redness were recorded at 2nd -5th day. Edema was obviously reduced in laser treated wounds in 14 patients. Redness was slightly increased in laser treated wounds in 15 patients. Finer scar in laser treated wound appeared as compared with wide scar in control wound.

Conclusion: Low level laser therapy causes edema-reducing effects and a little effect on a neovascularization at 2nd day after surgical intervention and minimal or fine scar formation.

Key words: Wound healing, Biostimulation, Low level laser therapy.

IRAQI J MED SCI, 2010; VOL. (4):65-70

Introduction

Wound healing is a complicated, interactive, integrative process involving cellular and chemotactic activity, the release of chemical mediators and associated vascular response⁽¹⁾.

In any elective surgical intervention, there is a wound to gain access to treat or remove the underlying pathology while in the surgery of trauma; the wound is the

primary pathology⁽²⁾.

Laser light has an important properties not found in light from any other source. These unique properties of laser light that make it useful in medicine are monochromaticity, coherence and directionality⁽³⁾.

In beginning of 1970, open wound had been treated with laser especially chronic ulcers which had proved unresponsive to other treatment regimens and this work had been demonstrated considerable success depending on the type of lesion⁽⁴⁾.

Biostimulation appears to have an effect on the cellular level, by increasing cellular function and stimulating various cells⁽⁵⁾.

Low level laser irradiation from red and infrared range of spectrum can be more effective in the three

¹Dept. Oral surgery, Al-Kadhemia Teaching Hospital, Ministry of Health, ² Institute of laser for postgraduate studies, university of Baghdad, ³Specialized Surgeries Hospital, Medical city.

Address Correspondence to: Dr. Ammar Salih Al-Alawi,

E- mail: ammarsalih2003@yahoo.com.uk

Received: 18th January 2010, Accepted: 15th August 2010.

overlapping phases of wound healing. By low level laser therapy (LLLT), the acute injuries and lesions had been healed rapidly and this healing can be induced in chronic lesions such as venous ulcers, pressure sores and diabetic ulcers.

LLLT has many different effects on biological tissue like anti-inflammatory, analgesic, anti-edematous effect; higher rates of ATP, RNA & DNA synthesis, and thus better tissue oxygenation and nutrition and increase in the absorption of interstitial fluid ⁽⁶⁾. The clinical effects of LLLT have been demonstrated by acceleration of wound healing, improvement of blood microcirculation and tissue regeneration ⁽⁷⁾.

Patients and Methods

This clinical trial comprised a total of 20 patients attending consultation clinic of the Oral and Maxillofacial Surgery Department in the Specialized Surgeries Hospital, Medical City, Teaching Hospital and requiring surgical intervention for different oral and maxillofacial lesions. This study included 20 patients 10 males and 10 females, the age ranged between 5-75 years.

Laser system

The characteristics of the laser device which was used in this study were class IV laser, infrared (Ga Al As) diode laser, its wavelength is 790-805 nm, mode of operation is modulated (chopped) cw and maximum cw power is 4 W.

Surgical procedure

The surgical operations were done by qualified surgeons under general anaesthesia in theatre hall of maxillofacial surgery department. Surgical operations irradiated by diode laser varied from prognathism of upper and lower jaws, hypertrophic scar in left side of neck, adenoid cystic carcinoma of submandibular gland and pleomorphic adenoma of parotid gland.

The incision and flap were designed according to site of the lesion. After removal of lesion, the site of surgery was irrigated, drains were put in some cases and flaps were repositioned and sutured.

Irradiation method

After suturing, each skin wound was divided into two parts, one part was irradiated by low level diode laser and the other part was left without irradiation as a control. The fiber optic of the laser device was located perpendicular to the wound. The operation mode of diode laser was cw mode, power density (power/spot size) was 1.25 W/cm², and exposure time was 50 sec. Figures (1, 2).

Assessment of wound healing

The edema and redness of wound were considered to evaluate the effect of low level diode laser on mucosal and skin wounds. The edema and redness were evaluated subjectively by reduced or present.

Results

The current clinical trial had been performed on 20 patients (10 males and 10 females) who required surgical intervention in oral and maxillofacial region. Clinical data was collected from the patients at the 2nd -5th day postoperatively.

The edema and redness had been evaluated subjectively by clinical inspection from 2nd day postoperatively.

In the laser treated wounds, the edema was reduced in 14 wounds and present in 6 wounds while the redness was present in 15 wounds and reduced in 5 wounds. Table no.(1)

In control wounds the edema was present in 13 wounds and reduced in 7 wounds while the redness was present in 13 wounds and reduced in 7 wounds. Figure (3)

In some cases scar was evaluated subjectively by fine or wide line of scar, there were 3 cases; in each case

the scar in laser treated site was fine line scar while in control site there was wide line scar. These observations

were seen 3 -4 weeks postoperatively. Figures (4, 5)

Table 1: show subjective evaluation of the laser treated and control wounds.

	Laser		Control	
	Present	Reduced	Present	Reduced
Edema	6	14	13	7
Redness	15	5	12	8

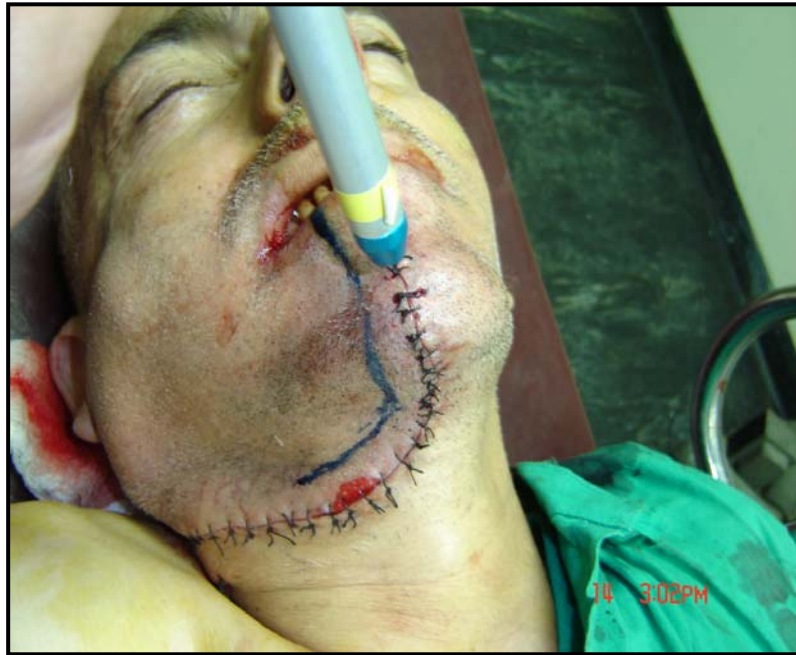

Figure 1: Irradiation of the wound after removal of the Squamous cell carcinoma of floor of the mouth

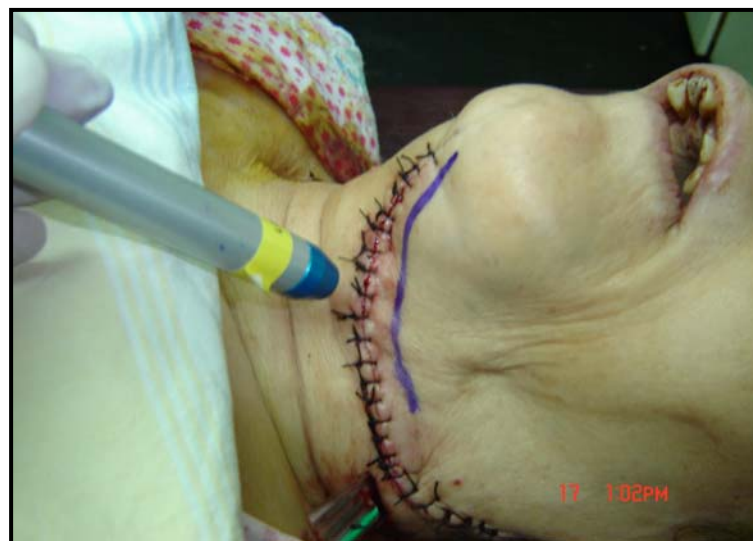

Figure 2: Irradiation of the wound after removal of the Squamous cell carcinoma of alveolus of mandible.

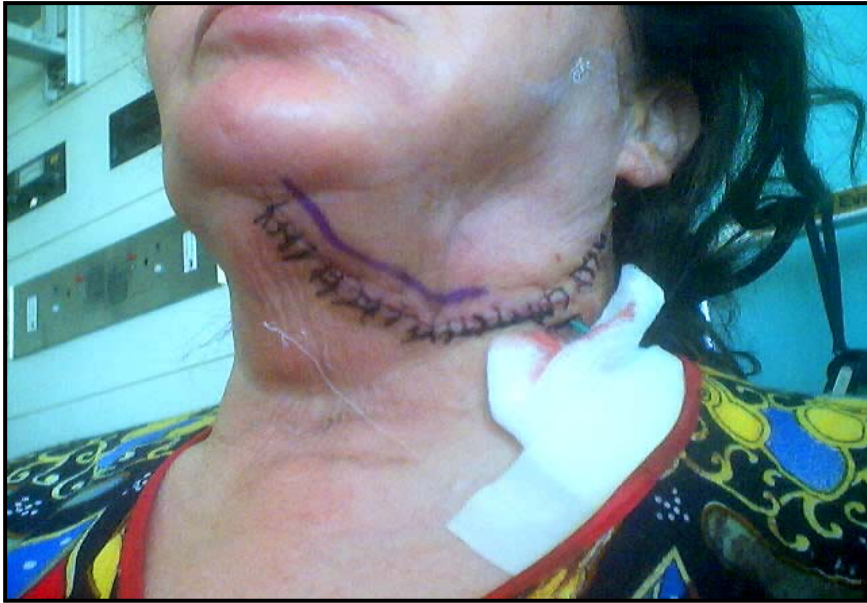
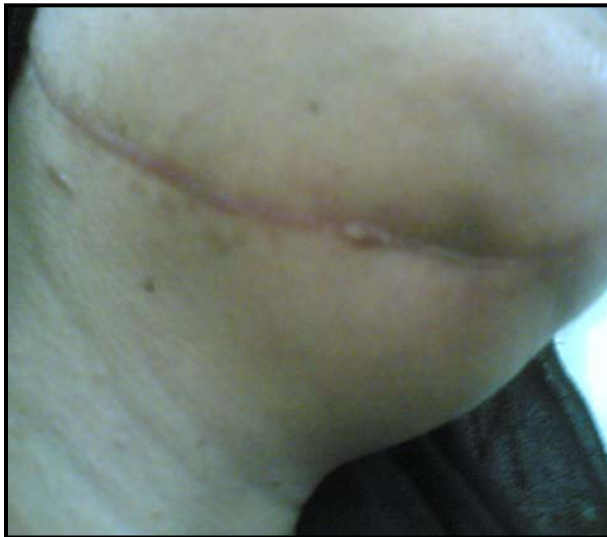
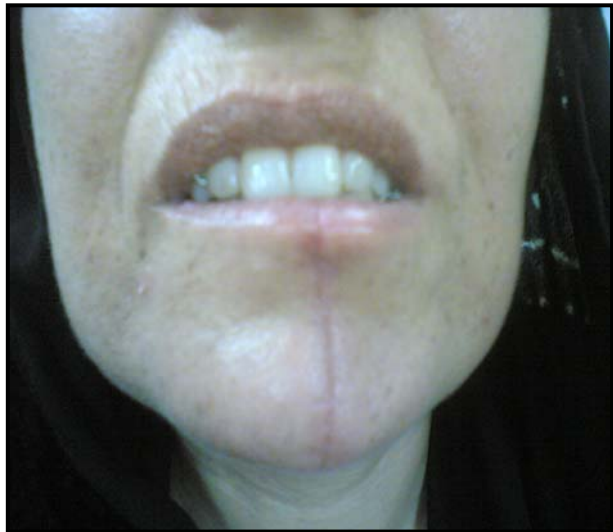Figure 3: Two days postoperatively show reduced edema and more redness in laser site.



A. Control site



B. Laser site

Figure 4: Four weeks postoperatively show fine scar in laser site and wide scar in control site

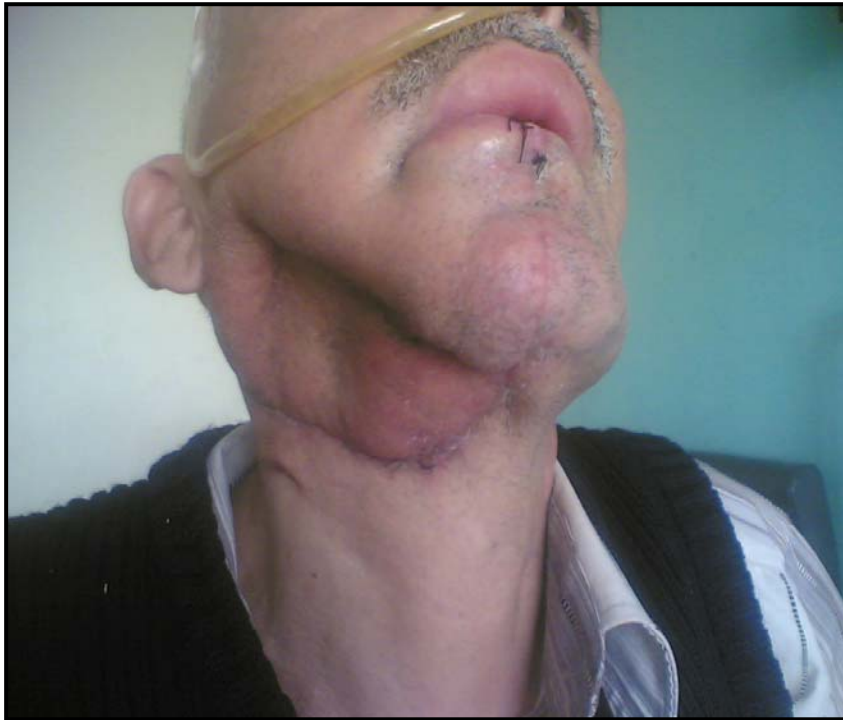

Figure (5): Four weeks postoperatively show fine scar in laser site and wide scar in control site.

Discussion

Wound healing is a complex, physiological multisteps process including number of phases which follow injury including inflammatory, proliferative and remodeling phases; it relies on the integration and coordination of many cellular and humeral elements ⁽⁸⁾.

Biostimulation is the application of a narrow spectral width of red and near infrared radiation over injuries or lesion to stimulate healing within those tissues and relive pain ⁽⁹⁾.

When the cells have absorbed the photons, a cascade of biochemical events occurs whose ultimate result is accelerated wound healing like increased collagen synthesis, increased fibroblast proliferation, increased cell function / activity, modulation of the production of growth factors (including transforming growth factor and platelet derived growth factors) and development of new blood vessels ⁽⁵⁾.

One possible mechanism by which LLLT may enhance wound healing in

vivo is via stimulation of epithelial cells ⁽¹⁰⁾.

Clinical observation of the wound in maxillofacial region had shown the edema in the laser treated wound was less compared with that in control wound which showed more edema 2nd day post operatively. These results agree with Fiszerman R, ND Rozenbom CY, 1995 and Amano A. 1994 who had shown the edema-reducing effects of the low level laser results from vasodilatation and increased microvascularization accelerated lymphatic flow and enhanced tissue oxygen uptake. In LLLT, immune modulation and mitigation of inflammatory response occurred because the mononuclear phagocytes cells, mast cells and leukocytes were stabilized preventing the release of harmful inflammatory chemical mediators ^(11, 12). Clinical observation of wounds show that the redness of wound is slightly more in laser treated wound compared with

control wound. This result is in agreement with Hickman, Dyson, 1988, Kubota, 2004 and Hawkins, Abrahamse, 2007 who had shown that the angiogenesis had been increased following laser irradiation of wounds. The low level laser irradiation has been shown to increase the blood flow rate and volume and to accelerate the wound healing process⁽¹³⁻¹⁵⁾.

Clinical observations revealed fine scar formation in laser treated wound after 3-4 weeks compared with that in control wounds. This result is in agreement with Hopkins et al., 2004, and Nicoleta Herascu et al., 2005 who had shown LLLT enhances collagen synthesis characterized by enhanced glycine and proline content in collagen fibrile and this result in more organized tissue, decrease adhesion, minimal keloid formation and lighter colored scars. LLLT is an effective modality to facilitate wound contraction^(16,17).

In the present study, it is concluded that laser dose (1.25 W/cm², 50 sec.) has edema-reducing effects and a little effect on a neovascularization and cause minimal or fine scar.

References

1. Baxter GD. Therapeutic lasers, theory and practice. Churchill livingstone, 1999, p: 90.
2. Coleman DJ. Wounds, tissue repair and scars. In: Russell RG, Williams NS, and Bulstrode C.K. Bailey and loves short practice of surgery. 23rd ed. Vol.1. Arnold: London, 2000, p: 29.
3. Catone GA, Alling CC. Laser application in oral and maxillofacial surgery. 1st ed. W.B. Saunders Company. 1997.
4. Mester E, Mester A F, Mester E. The biomedical aspects of laser application. Laser Surg Med 1985; 5:31-9.
5. Kawalec J S, Pfennigwerth TC, Hetherington VJ. A review of laser in healing diabetics' ulcers. The foot 2004; 14:68-71.
6. Tacac S, Stojanovic S. Diagnostic and biostimulating lasers. Med Pregl May-Jun 1998; 51:245-9.
7. Vladimirov YA, Osipov AN, Klebavov GI. Photobiological principles of therapeutic applications of laser radiation. Biochemistry (Moscow) 2004; 69:1.
8. Brown M T. Wound healing. In: Cummings, Fredrickson, Marker, Krause, Richardson, Schulluller. Otolaryngology, head & neck surgery. 3rd ed. Vol.1. Mosby-year book, Inc. 1998.
9. Jack L. Use of low level laser therapy to treat chronic wounds. Nursing in practice Jul/Aug. Thor international Ltd. 2003.
10. Walsh LJ. The current status of low level laser therapy in dentistry, part 1.soft-tissue applications. Australian dental journal 1997; 42(4): 247-254.
11. Fiszerman R, ND Rozenbom CY. Low energy therapy effect in low extremity transcutaneous oxygen partial pressure. Abstract ASLMS 14 Ann meeting, San Diego, California 1995; 4: 20-25.
12. Amano A. Histological studies on the rheumatoid synovial membrane irradiated with a low energy laser. Laser Surg Med 1994; 15:290.
13. Hickman R A, Dyson M. The effect of laser therapy on angiogenesis during dermal repair. Laser Surg Med 1988; 8:186.
14. Kubota J. Defocused diode laser therapy (830nm) in the treatment of unresponsive skin ulcers: a preliminary trail. Journal of cosmetic and laser therapy 2004; 6:2: 96-102.
15. Hawkins D, Abrahamse H. Influence of Broad-Spectrum and Infrared Light in Combination with Laser Irradiation on the Proliferation of Wounded Skin Fibroblasts. Photomedicine and Laser Surgery. 2007, 25(3): 159-169.
16. Hopkins JT, McLoda TA, Seegmiller JG, David Baxter G. Low level laser therapy facilitates superficial wound healing in humans: A triple-blind, sham-controlled study. J Athl Train. 2004 Sep; 39(3):223-229.
17. Herascu N, Velciu B, Calin M, Savastru D, Talianu C. Low-Level Laser Therapy (LLLT) Efficacy in Post-operative Wounds. Photomedicine and Laser Surgery. February 2005, 23(1): 70-73.

Identification of a Class of Hemopoietic Colony-Forming Cells from Human Umbilical Cord Blood in Culture.

Baydaa H. Mutlak *PhD.*

Abstract

Background: Human umbilical cord blood (UCB) contains hemopoietic stem cells (HSCs) which are regarded as valuable sources for cell transplantation.

Objective: This study is aimed to identify a class of human hemopoietic colony-forming cells and found the suitable concentration for replating experiments.

Methods: Cord blood (CB) was collected from placenta of newly delivered women in Al-Kadhemia Teaching Hospital in Baghdad for normal vaginal delivery. Isolation and culturing of cells took place in Medical Research Unit \ College of Medicine\ Al-Nahrain University.

The present study included two lines:-

A:-Immunocytochemistry analysis of mononucleated cells (MNCs) for CD34.

B:-Culturing MNCs in different concentrations in order to determine the suitable concentration for replating further experiments. Mononucleated cells were isolated by using density gradient centrifugation and the MNCs count and viability were determined by using trypan blue. The MNCs were cultured in RPMI

+10%FCS and the medium conditioned by 1%(v/v) phytohemagglutinin (PHA). The cultures were maintained in an environment of 37C°, 5%CO₂ and fully humidified atmosphere for 14 days.

Results: The results of immunocytochemical staining showed that MNCs were positive for CD34+, the conditioned medium gave rise to hemopoietic colonies containing colony forming unit-granulocyte-macrophage (CFU-GM), burst forming colony-erythroid (BFU-E) and mixed colonies (CFU-GEMM). These colonies could be distinguished from other hemopoietic colonies *in situ* by the complete absence of signs of terminal differentiation.

Conclusions: The results of this study confirmed that UCB provides a great source of hemopoietic stem cells for using in medical applications.

Key words: Hemopoietic Colony-Forming Cells, Human Umbilical Cord Blood, in culture.

IRAQI J MED SCI, 2010; VOL. (4):71-77

Introduction

Adult stem cell sources like hemopoietic stem cells (HSCs) are currently identified and characterized in laboratories all over the world⁽¹⁾.

Umbilical cord blood (UCB) is the blood remaining in the umbilical cord and placenta; it is routinely discarded after delivery. In 1987, a child with Fanconi's anemia received an allogeneic transplant, the successful transplant took place in Paris⁽²⁾. As a result of this report, the potential of UCB as a source of HSCs for transplantation

rapidly become an area of intense clinical and scientific interest⁽³⁾.

It has been shown in early studies that UCB contains a significantly higher number of progenitor cells when compared with adult peripheral blood (PB) and bone marrow (BM). The number of colony-forming unit-granulocyte-macrophage (CFU-GM) is greatly increased in UCB compared with PB. The number of circulating colony-forming unit granulocyte, erythroid, monocyte, megakaryocyte (CFU-GEMM) also appears to be significantly increased in UCB compared with PB and BM^(2, 4). Moreover, *in vitro* studies have suggested that naïve UCB lymphocytes are potentially less immunologically active than those usually found in the PB and BM and may therefore produce

Dept. Biology, College of Education / Ibn AL-Haitham / Baghdad University.

Address Correspondence to: Dr. Baydaa H. Mutlak ,

E- mail: baida1970@yahoo.com

Received: 25th January 2010, Accepted: 2nd September 2010

fewer problems with graft versus host disease (GVHD) than functionally mature lymphocytes harvested from live donors^(5,6).

CD34 antigen has been used as a marker of HSCs. In fact most colony – forming cells are found in the CD34+ cell fraction. CD34+stem cells can be isolated from UCB and BM⁽⁷⁾. Most studies have indicated that UCB contains a significantly large number of colonies –forming cells than BM^(8,9). Fourteen day expansion of CD34+cells isolated from UCB stimulated with stem cell factor (SCF) and granulocyte- colony stimulating factor (G-CSF) was significantly greater than from stimulated CD34+cells isolated from BM⁽⁸⁾. Isolated UCB CD34+cells yield approximately the same number of CFU-GEMM, twice the number CFU-GM and three times of BFU-E as similar cell populations isolated from BM⁽⁹⁾.

Purification and characterization of HSCs are, therefore important not only for studies of the biological properties of HSCs, but also for clinical applications so this study was aimed to identify the class of human hemopoietic colony –forming cells and found the suitable concentration for replating experiments.

Materials and Methods

Umbilical cord blood samples were obtained freshly from discarded placenta of full term normal vaginal deliveries from AL-Kadhimiya Teaching Hospital in Baghdad. The specimens were transferred to Medical Research Unit \ College of Medicine\ Al-Nahrain University. CB was diluted 1:1 with phosphate buffer saline (PBS) then carefully overlaid on Ficoll-paque at a ratio of 3:1 in 10ml sterile conical tubes. The specimens were centrifuged in cooled centrifuge at 2000 rpm for 25 min at 4C°. After density gradient centrifugation, the

mononucleated cells (MNCs) were retrieved from buffy coat layer by pipetting and washing 2-3 times with PBS at 2000 rpm for 10 min at 4C°⁽¹⁰⁾. The final product was used in immunocytochemistry analysis for CD34 and culturing MNCs in different concentration.

The MNCs were resuspended in 1ml of PBS and the suspension was applied to slides by spinning on a cytocentrifuge. The slides were left to dry and fixed with 4% para-formaldehyde in PBS, so the slides were ready for immunocytochemistry staining. The first step was the addition of 4% hydrogen peroxide for 15 min. The second step was the addition of primary antibody (Mouse anti- Human CD34) for 1h., then the addition of secondary antibody (anti-Mouse IgG biotin) for 1h. The streptavidin conjugated to horse radish peroxidase was added to the slides for 1h. The slides in all the above steps were incubated in a humidified chamber at 37C° and the slides were washed extensively with PBS after each step. For visualization the peroxide, liquid Diamino benzidine (DAB) chromogen solution was added to the slides for 15 min then washed with PBS and counter stained in Harris hematoxylin for 2-3 min then washed with distilled water then with PBS. The slides were mounted with glycerol and were inspected by light microscope and photographed⁽¹¹⁾.

For culturing the MNCs, the final product of MNCs was resuspended in 1ml of RPMI 1640 supplemented with 10% fetal calf serum (FCS). The cell number and viability were determined by using trypan blue solution⁽¹⁰⁾.

The cell suspension was cultured in tissue culture plates in five groups at final concentration as follow:-

Group A: -4x10⁵ cell/ml

Group B: -6x10⁵ cell/ml

Group C: - 8x10⁵ cell/ml

Group D:-1X10⁶ cell/ml

Group E:-2X10⁶ cell/ml

The cells were cultured in 1 ml of RPMI 1640 +10%FCS and the medium conditioned by 1% vol /vol phytohemagglutinin (PHA)for each well .The plates were incubated at 37 °C in a humidified atmosphere flushed with 5% Co₂ in air.

The numbers of hemopoietic colonies were determinate by direct cell counting *in situ* by using inverted microscope ⁽²⁾.

The hemopoietic colonies were scored and photographed on day 14 of culture

Results

-Immunocytochemical analysis for CD34

The results of immunocytochemistry staining showed that the UCB –derived MNCs were positive for CD34+. The expression of cell surface marker that appeared on the UCB derived HSCs after purification ,showed that the deep brown color for Diamino benzidine (DAB) stain represents the positive cells while the blue color for the counter stain (hematoxylin)represent the negative cells (Figure.1)

-Culturing the MNCs

After two days of culturing, some of the MNCs were adherent to the culture plates. The adherent cells began to form homogeneous population of small rounded cells with high nucleus to cytoplasm ratio, and the clusters of HSCs began to appear in culture plates 5 days after primary culture plating. As the cells proliferate, some of them detached from the plastic and remained floating in suspension; however, they

stayed viable and gave rise to new clusters (Figure.2).

On the days 12-14 of culture , only three types of HSCs colonies revealed no signs of degeneration ,these colonies showed signs of terminal differentiation for example , the erythroid progenitors large megakaryocytes ,and granulocytes recognizable by their polygonal shape . When the plates were examined with an inverted microscope , three types of HSCs colonies were recognized by their distinct color and morphology *in situ* .The first type is colony forming unit-granulocyte-macrophage (CFU-GM) which were represented with a flat arrangement of non hemoglobinized cells (Figure.3 A). The second type represented by burst forming unit-erythroid (BFU-E) which appeared with densely packed configuration of hemoglobinized cells (Figure.3 B). The third type represented the mixed colonies or colony forming unit –granulocyte, erythroid, monocyte ,megakaryocyte (CFU-GEMM)which appeared as a compact colonies ,usually ,central hemoglobinized small and large cells (Figure.3 C)

The results of culturing in different concentration (Table 1) demonstrated that at low densities the assay efficiency is decreased .Also, at higher plating densities was the problem of colony crowding and the difficultly distinguishing of the overlapping granulocytic and erythroid colonies from true mixed colonies .For this reason, cultures were best plated at cell concentration of 1x10⁶ cell/ml because it is a suitable concentration for re plating experiments.

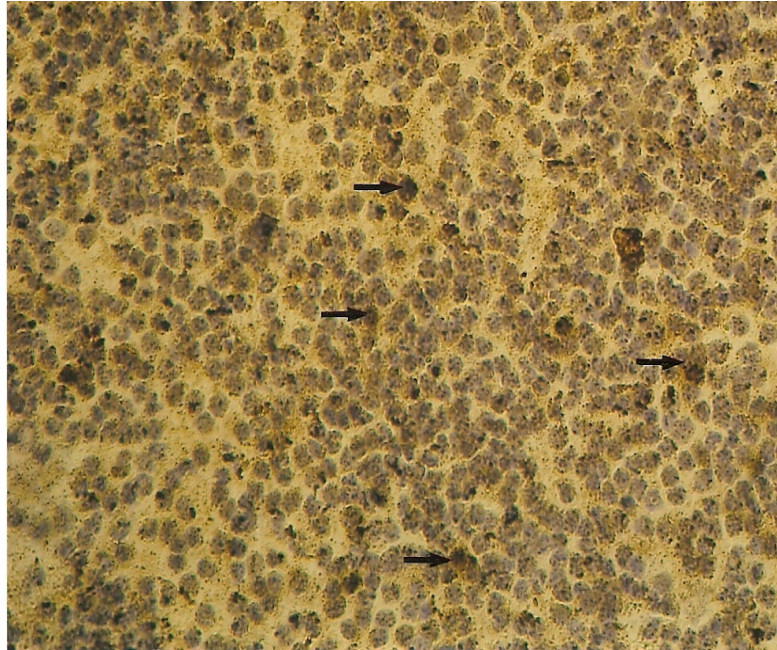


Figure 1: Expression of CD34 marker on HSCs after purification of the cells. The deep brown colors represent the CD34 positive cells (arrows) (X100.8).

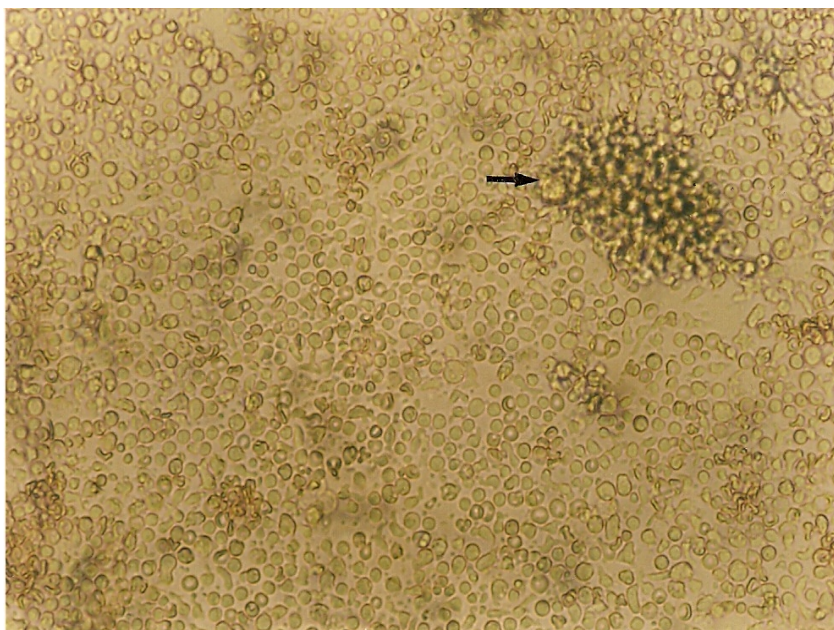


Figure 2: After 5 days in culture the cells began to proliferate and formed clusters of HSCs (arrow) which detached from the plastic surface, and it stayed viable (X160).

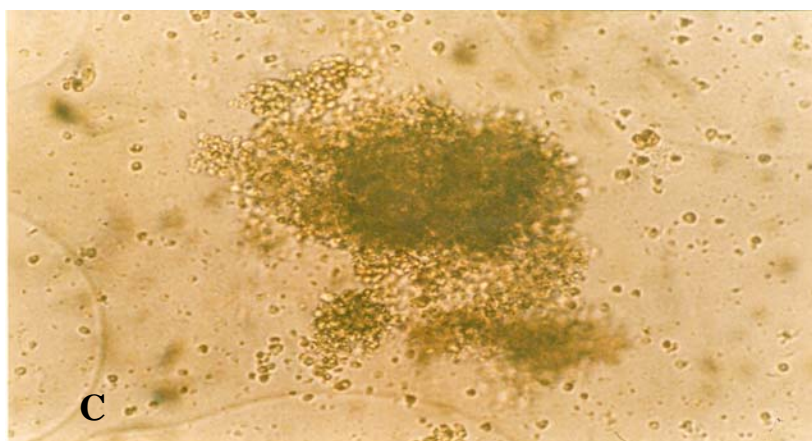
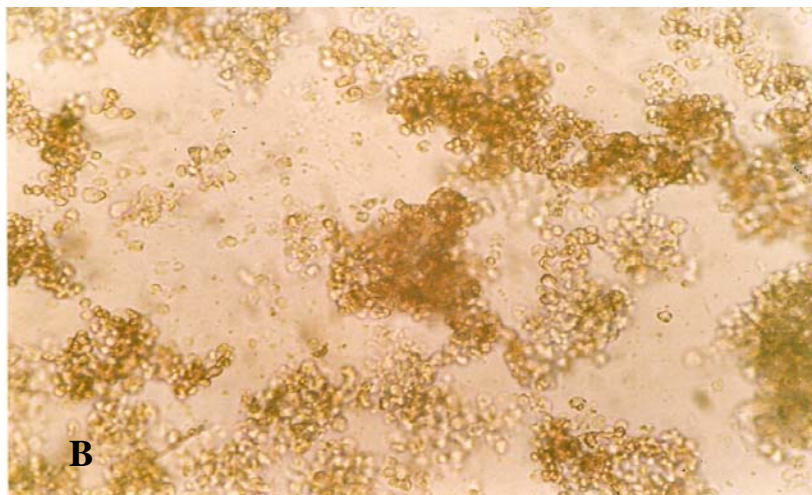
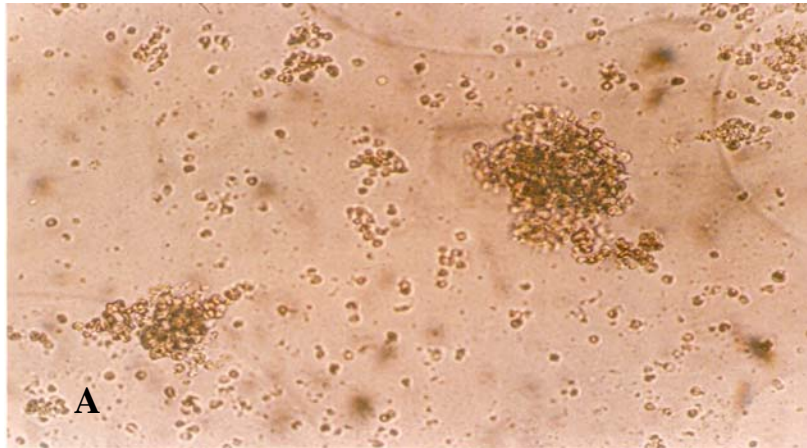


Figure 3: Hemopoietic colony cells types cultured in RPMI media+10%FCS +PHA examined under inverted microscope and photographed *in situ*. A: Colony forming unit-granulocyte-macrophage (CFU -GM), B: Burst forming unit-erythroid (BFU-E), C: colony forming unit -granulocyte, erythroid, monocyte ,megakaryocyte (CFU- GEMM)(X100.8).

Table 1: Cytologic analysis of hemopoietic stem cells colonies cultured in different concentration. Individual colonies were determinate on day 14 by direct cell counting *in situ* by using inverted microscope.

Cell concentration	CFU-GM	BFU-E	CFU-GEMM
4X10 ⁵ cell/ml	20	14	25
6x10 ⁵ cell/ml	37	30	48
8x10 ⁵ cell/ml	48	41	57
1x10 ⁶ cell/ml	55	50	65
2x10 ⁶ cell/ml	59	57	80

Discussion

Until recently, blood that remained in the umbilical cord and placenta after delivery was routinely discarded. Human UCB is now considered a valuable source for stem cells, this blood is known to contain both HSCs and pluripotent mesenchymal stem cells (MSCs). There has been a substantial increase in the clinical use and research investigation of UCB in hemopoietic transplantation and regenerative medicine⁽¹²⁾.

Hemopoietic stem cells colonies in this study were identified as compact colonies of stem cells having a high nucleus to cytoplasmic ratio. These properties are identical to HSCs colonies which previously described by different workers^(2, 13).

The allogenic transplantation was used to treat thousands of patients, who have life threatening hematological diseases. The principal limitations of BM transplantation for majority of patients are the lack of suitable HLA-matched donors and the complication of Graft Versus Host Disease (GVHD) associated with HLA-mismatching. The expected advantages of using CB transplantation are enrichment of immature progenitor HSCs and the immaturity of immune system at birth, which should decrease the incidence and severity of GVHD⁽¹⁴⁾. Cord blood-derived HSCs have distinctive proliferative advantages factors. The small number and the relative immaturity of CB-T lymphocyte could reduce the risk and severity of

GVHD. Also studies of *in vitro* cultures of CD34⁺ cells from UCB suggested that CB may have a greater ability to generate new blood cells than BM; there are nearly ten times as many blood producing cells in CB. This fact suggests that a smaller number of CB cells are needed for successful transplantations than PB and BM transplantation^(15,16).

In the present study, the immunocytochemistry staining showed that UCB-derived MNCs having a good percentage of positive cells for CD34⁺. The isolation method which was used in this study is unable to purify the HSCs at a high level. However, the yield of CD34⁺ cells which were obtained by this isolation method would allow us to proceed to further steps of HSCs culture. Moreover, the cell count and viability which were detected by trypan blue method were satisfying and reflect the success of this isolation method.

In this study, a class of HSCs that had extensive self-renewal capacities and very high incidences for early hemopoietic progenitors have been described. These human HSCs exhibit at least some features similar to those characterizing the pluripotent stem cell of murine⁽⁴⁾.

The conditioned medium may contain agents capable of supporting the growth of hemopoietic progenitors. The dependence of HSCs on the presence of PHA may be indicative of the presence of a distinct hemopoietic

factor in PHA whose activity is permissive for the growth of HSCs colonies. The role of PHA is probably in the stimulation of a population of cells among PB leukocytes, which are capable during preincubation of producing various stimulatory factors (2,8).

The results of this study confirmed that UCB provides a great source of hemopoietic stem cells for cellular therapy and using in medical applications and as an alternative source to BM.

References

- 1.** Prentice DA. Adult stem cells. The published record, prepared for the president's council on bioethics. (2004) Appendix K (Downloaded from [http:// bioethics.gov](http://bioethics.gov) on April 29, 2007).
- 2.** Broxmeyer H, Douglas G, Hangoc G, Cooper S, Bard J, English D, et al.. Human umbilical cord blood as a potential source of transplantable hematopoietic stem/progenitor cells. Proc. Natl. Acad. Sci. USA, 1989; 86: 3828-3832.
- 3.** Hows JM. Status of umbilical cord transplantation in the year 2001. J. Clin. Pathol. 2001; 54: 428-434.
- 4.** Nakahata T and Ogawa M. Identification in culture of a class of hemopoietic colony-forming units with extensive capability to self-renew and generate multipotential hemopoietic colonies. Proc. Natl. Acad. Sci. USA. 1982; 79: 3843-3847.
- 5.** Rabian-Herzog C, Lesage S, Gluckman E and Charron D. Characterization of lymphocyte sub population in cord blood. J.Hematol. 1993; 2:255-257.
- 6.** Will A M. Umbilical cord blood transplantation. Arch. Dis. Child. 1999; 80: 3-6.
- 7.** Berenson RR, Anderews G and Bensiger B. Antigen CD34+ marrow cells engraft lethally irradiated baboons. J.Clin.Inves. 1988; 81:951-955.
- 8.** Ash RC, Detrick RA and Zanjani ED. Studies of human pluripotential hemopoietic stem cells (CFU-GEMM) in vitro. Blood. 1980; 58(2):309-316.
- 9.** Kim DK, Fujiki Y, Fukushima T, Ema H, Shibuya A and Nakauchi H. Comparison of hematopoietic activities of human bone and UCB CD34 positive and negative cells. Stem Cells. 1999; 17 (5): 286-294.

- 10.** Cardoso AA, Batard P, Hatzfeld A, Brown EL and Hatzfeld J. Release from quiescence of CD34 CD38 human UCB cells reveal their potentiality to engraft adults. Proc. Nat. Acad. Sci. USA. 1993; 90:8707-8710.
- 11.** Lorette C. Immunocytochemistry methods and protocols. 2nd edition. Human press, Totowa, New Jersey. 1999.
- 12.** Moise KJ .Umbilical cord stem cells. Obst. Gyne. 2005; 106 (6): 1393-1407.
- 13.** Smith C. Hematopoietic stem cells and hematopoiesis. Can. Con. 2003; 10 (1): 9-16.
- 14.** Gluckman E, Rocha V and Chastong C. Use of cord blood cells for banking and transplant. Oncol. 1997; 2(5):340-343.
- 15.** Gluckman E. Ex vivo expansion of cord blood cells. Exp. Hematol. 2004; 32: 410-412. [Abstract].
- 16.** Rienberg S. Umbilical cord blood stem cell transplantation. Report for federal standards for cord blood banks. 2001 (Downloaded from <http://discover.bio-rad.com> on September 5, 2007).

المجلة العراقية للعلوم الطبية
قائمة المحتويات

المقالات

❖ دراسة مقارنة بين المعالجه بوضع الجبيرة الكاملة الى ما فوق المرفق و المعالجه باستخدام الـ K-Wire بالاضافه للجبيرة الكاملة الى ما فوق المفصل لعلاج كسر اسفل عظم الكعبرة المزاح تماما عن مكانه في الاطفال والمراهقين.

عبد علي محسن.....١

❖ عزل وتنقية الكلوكوسيل ترانسفيريز من العزلة المحلية من بكتريا
Streptococcus sobrinus (Serotype G)

ندى هشام المدلل ، عصام فاضل الجميلي ، نضال عبد المهيمن ،عبد الواحد باقر.....٣

❖ تقييم المرضى المصابين بالسرطان الكلوي قبل الجراحة- مشاهدات المفراس
الحلزوني مقارنة بنتائج الفحص النسيجي.

محمد عبد كاظم ، علا محمد رضا الكواز ، حيدر عبد الحسين.....٤

❖ دراسة طبية عدلية عن وفيات الولدان في بغداد

فائق أمين بكر، حسين محمود غازي ، نبيل غازي هاشم الخطيب.....٦

❖ حث التمايز العضلي القلبي للخلايا الجذعية البالغة لنقي العظم في الجرذان البيض
باستخدام 5-azacytidine

إنتظار محمد مناتي.....٧

❖ نسبة حدوث حالات الهذيان بين المرضى الراقدين في ردهات الطب الباطني في
مستشفى تعليمي في بغداد

عدي خالد عبد الجبار.....٨

❖ تقييم ومقارنة تأثير الحديد الوريدي مع الفموي على فقر الدم في المرضى
المصابين بقصور الكلية المزمن

عارف سامي مالك.....٩

❖ تعدد الحلمات: مضامين تشريحيه وسرييه

محمد عودة سلمان.....١٠

❖ تقييم تغيير لون الأكريل الراتينجي الحراري بواسطة الفحص البصري ومقياس طيف الأشعة تحت الحمراء بعد عملية الغمر في غسول أطقم الأسنان الكيمياوية.
إسراء محمد حمودي ، الاء عزت عبد المجيد..... ١١.....

❖ التقييم السريري للعلاج الليزر ذو المستوى الواطئ في شفاء جروح الجلد في جراحة الوجه والفكين
عمار صالح رضا العلوي، حسين علي جواد، اياد محمد اسماعيل..... ١٢.....

❖ تشخيص أنواع مستعمرات الخلايا المكونة للدم المشتقة من دم الحبل السري للأنسان في المزرعة
بيداء حسين مطلق..... ١٣.....

المجلة العراقية للعلوم الطبية

رئيس هيئة التحرير

الأستاذ الدكتور عدنان عبد خشان عنوز

هيئة التحرير التنفيذية

رئيس التحرير	أ.د. فاخر سلمان شفيق
محرر	أ.د. غسان عبد الامير الشماع
محرر	أ.د. علاء غني حسيين
محررة	أ.د. نضال عبد المهيمن
محرر	أ.م.د. سمير محمود جاسم
محرر	أ.م.د. معتز عبد المجيد القزاز
محرر	أ.م.د. حسام عبد الكريم أحمد
محررة	أ.م.د. ايناس طالب عبد الكريم
محررة	أ.م.د. أثير جواد عبد الأمير
محرر	أ.م.د. حسن عزيز الحمداني
محررة	أ.م.د. هالة سامح عارف
محرر	أ.م.د. وسيم فاضل محمد
محرر	أ.م.د. حيدر جواد كاظم
محررة	أ.م.د. سهاد محمد صالح
محرر	م.د. علي فؤاد هادي

سكرتارية المجلة

إسراء سامي ناجي

المحرر الفني

علياء نوري حاتم

الهيئة الاستشارية

عمداء كليات الطب العراقية الحاليين

كلية الطب/ النهرين	أ.د. عدنان عبد خشان عنوز
كلية الطب/بغداد	أ.د. فاضل عباس الخفاجي
كلية الطب/الكندي	أ.د. فارس عبد الكريم خزعل
كلية الطب/المستنصرية	أ.د. محمد حسن علوان
كلية الطب/الموصل	أ.د. مزاحم قاسم الخياط
كلية الطب/نينوى	أ.د. فارس بكر الصواف
كلية الطب/بابل	أ.م.د. علي خيرالله الشاعلي
كلية الطب/ ذي قار	أ.م.د. مؤيد ناجي مجيد
كلية الطب/ الأنبار	أ.د. عبد الله صالح حسن
كلية الطب/ تكريت	أ.د. عبد أحمد سلمان
كلية الطب/ ديالى	أ.د. خضير خلف إبراهيم
كلية الطب/ كربلاء	أ.د. زهير عمران عيسى
كلية الطب/ الكوفة	أ.د. محمد سعد عبد الزهرة
كلية الطب/ البصرة	أ.د. ثامر أحمد حمدان
كلية الطب/ القادسية	أ.د. راهي كلف الياسري
كلية الطب/ كركوك	أ.د. فخر الدين نجم ناصر
كلية الطب / دهوك	أ.م.د. فرهاد سوليفان
كلية الطب/ واسط	م.د. عطا كطي علاوي
كلية الطب/ العمارة	م.د. علي عبد العزيز الشاوي
كلية الطب/ المثنى	م.د. مساعد الدهان

السادة أعضاء مجلس كلية الطب/ جامعة النهريين

- أ.د.عدنان عبد خشان عنوز / عميد الكلية
أ.د. حسام حسون علي / معاون العميد للشؤون الإدارية
أ.م.د. عبد الرزاق حردان أحمد/ معاون العميد للشؤون العلمية والطلبة
أ.د. نضال عبد المهيمن/ رئيسة فرع الحياء المجهرية
أ.د. هاشم مهدي هاشم / رئيس فرع الباطنية
أ.د. مها البياتي / رئيسة فرع النسائية والتوليد
أ.د. علاء غني حسين/ رئيس فرع الباثولوجي والطب العدلي /وكالة
أ.م.د. سمير محمود جاسم / رئيس فرع الكيمياء والكيمياء الحياتية
أ.م.د. حسن أحمد حسن/ رئيس فرع الجراحة
أ.م.د. فرقد بدر حمدان / رئيس فرع الفلسفة
أ.م.د. حيدر جواد كاظم / رئيس فرع التشريح البشري
أ.م.د. لمياء عبد الكريم حمودي/ رئيسة فرع طب الأطفال
أ.م.د.أثير جواد عبد الأمير/ رئيسة فرع طب المجتمع والأسرة وكالة
م. عبد الكريم حميد عبد / رئيس فرع الفارماكولوجي وكالة
أ.م.د. محمد عبد كاظم الجبوري / ممثل عن أعضاء مجلس الكلية في الجامعة

الإستشاريين المعتمدين للمجلة العراقية للعلوم الطبية

- أ.د. محمود حياوي حماش (الأردن/ متقاعد)
- أ.د. رافع الراوي (الإمارات العربية المتحدة/ متقاعد)
- أ.د. أنعم رشيد الصالحي (معهد الأجنة والعقم /النهرين)
- أ.د. أمجد داود نيازي (المجلس العراقي للأختصاصات الطبية/ متقاعد)
- أ.د. نزار الحسنني (المجلس العراقي للأختصاصات الطبية/ متقاعد)
- أ.د. أسامة نهاد رفعت (الإمارات العربية المتحدة/ متقاعد)
- أ.د. أسامة الناصري (النهرين)
- أ.د. أكرم جعفر عبود (الإمارات العربية المتحدة)
- أ.د.سرمد خونددة (جامعة بغداد/ متقاعد)
- أ.د. حكمت عبد الرسول حاتم (جامعة النهرين)
- أ.د. رياض عبد الستار (الإمارات العربية المتحدة/ متقاعد)
- أ.د. فاروق حسن الجواد (جامعة النهرين / متقاعد)
- أ.د. سامي إسطنبولان مطلوب (جامعة النهرين / متقاعد)
- أ.د. سوسن ساطع عباس (جامعة النهرين)
- أ.د. يعرب إدريس عبد القادر (جامعة النهرين)

دراسة مقارنة بين المعالجة بوضع الجبيرة الكاملة الى ما فوق المرفق و المعالجة باستخدام K-Wire بالاضافة للجبيرة الكاملة الى ما فوق المرفق لعلاج كسر اسفل عظم الكعبرة المزاح تماما عن مكانه في الاطفال والمراهقين.

محمد علي محسن

الخلاصة

خلفية الدراسة: كسر أسفل عظم الكعبرة في الأطفال والذي يسمى أحياناً بكسر Colle's للمراهقين يعتبر من ضمن أكثر الكسور شيوعاً في الأطفال . تم جمع حالات مرضية لكسور أسفل عظم الكعبرة المزاحة تماماً بالأطفال والمراهقين قُيِّمت وعولجت بواسطة الطريقة المغلقة والجبيرة وطريقة تثبيت الكسر وطريقة تثبيت الكسر بواسطة الـ K-wire دون شق جراحي.

هدف الدراسة: لتقييم الفائدة المتوخاة من استخدام K-Wire بالاضافة إلى الجبيرة الكاملة فوق المرفق في معالجة كسر أسفل عظم الكعبرة في الأطفال والمراهقين.

طريقة العمل: اشتملت الدراسة على أربعة و ثلاثين مريضاً من الأطفال ، يعاني جميعهم من كسر أسفل عظم الكعبرة المزاح تماماً و قد تم تقسيمهم إلى مجموعتين:-

المجموعة (أ) و تشمل على 16 طفل معدل أعمارهم يبلغ 7,9 سنة ، بواقع 10 ذكور و 6 إناث. المجموعة (ب) و تشمل على 18 طفل معدل أعمارهم يبلغ 8,6 سنة ، بواقع 11 ذكور و 7 إناث. في كلتا المجموعتين تم تعديل الكسر بواسطة الطريقة المغلقة تحت التخدير العام بنسبة 70% من قطر العظم عند موقع الكسر.

المجموعة (أ) تم تثبيت الكسر باستخدام جبيرة كاملة إلى ما فوق المرفق ، إما المجموعة (ب) فقد تم تثبيت الكسر بواسطة الـ K-Wire مع وضع جبيرة إلى ما فوق المرفق تم إخراج المرضى من كلتا المجموعتين من المستشفى في اليوم التالي مع كارت متابعة. المجموعة (أ) تمت متابعتهم أسبوعياً لمدة ثلاثة إلى أربعة أسابيع مع عمل صور بالأشعة السينية مره أسبوعياً. أربعة مرضى من هذه المجموعة (25%) عانوا من أعاده تحرك الكسر ، ثلاث منهم احتاجوا إلى أعاده تعديل الكسر بينما المجموعة (ب) تم متابعتهم كل ثلاثة أسابيع و تم اخذ صور أشعة سينية مره كل ثلاثة أسابيع و كان معدل المضاعفات في هذه الحالة اقل في ما يخص أعاده تحرك الكسر مع الحاجة إلى إعادة تعديله.

النتائج: خطورة إعادة تحرك الكسر كان بنسبة أكبر في المجموعة (أ) (25%) مقارنة بعدم إعادة تحرك الكسر في المجموعة (ب) . التهاب موقع دخول الـ K-wire في المجموعة (ب) بحالة مرضية واحدة فقط (5.6%) فيما يخص تحدد الحركة الدورانية وإنبساط الساعد والرسغ مقارنة بالساعد الآخر غير المتضرر في المجموعتين كان كالآتي :

المجموعة (أ) إنبساط الرسغ 35 درجة (58.3% من المعدل الطبيعي) بينما الحركة الدورانية للساعد كانت 40 درجة (44.4% من المعدل الطبيعي) بالنسبة لمجموعة (ب) إنبساط الرسغ كان 40 درجة (66.7% من المعدل الطبيعي) والحركة الدورانية كانت 55 درجة (61.1% من المعدل الطبيعي) .

الاستنتاج: استعمال K-wire إضافة للجبيرة يعطينا بقاء أفضل لموقع كسر أسفل عظم الكعبرة بعد إرجاعه ويقل الحاجة للمتابعة بواسطة الأشعة السينية والحاجة إلى طرق إعادة إرجاع الكسر مرات أخرى .

مفتاح الكلمات : كسر أسفل عظم الكعبره المزاح تماماً ,جيسونة , K- واير.

فرع الجراحة [كلية الطب - جامعة النهرين]

المجلة العراقية للعلوم الطبية 2010 م المجلد 8 العدد 4 ص 3- 9

عزل وتنقية الكلوكوسيل ترانسفيريز من العزلة المحلية من بكتريا *Streptococcus sobrinus (Serotype G)*

ندى همام المدلل¹ , عصام فاخر الجميلي² , نضال عبد المهيمن³ , عبد الواحد باقر¹

الخلاصة

خلفية الدراسة: يعد انزيم الكلوكوسيل ترانسفيريز من الانزيمات المفرز خارج الخلية والمنتج من بكتريا المكورات الفموية والذي يعمل على بلمرة السكريات وتحولها الى الكلايكون .
هدف الدراسة: عزل وتنقية انزيم الكلوكوسيل ترانسفيريز من العزلة المحلية من بكتريا *streptococcus sobrinus (Serotype G)*

طريقة العمل: تم تنقية الانزيم من بكتريا Streptococcus sobrinus باستخدام الترشيح الفائق وكروموتوغرافيا الادمصاص و كروماتوغرافيا التبادل الايوني (DEAE) والترشيح الهلامي Sephacryl S-200 .

النتائج: تم الانتاج المعيارى الواسع والتركيز والتنقية للكلوكوسيل ترانسفيريز لبكتريا المكورات الفموية من النوع S. sobrinus(serotype G) العزلة N10 بواسطة الترشيح الفائق باستخدام مرشح (Amicon –P50) وكروموتوغرافيا الادمصاص (حبيبات هيدروكسي البيتايت) وكروموتوغرافيا التبادل الايوني (DEAE-Cellulose) وكروموتوغرافيا الترشيح الهلامي باستخدام هلام Sephacryl S-200 . تم تنقية ثلاث انزيمات من الكلوكوسيل ترانسفيريز بروتين على التوالي وعدد مرات تنقية (27.59 و 27.92 و 58.75 مرة على التوالي و بحصلية انزيمية 14 و 10.94 و 17.11 % على التوالي .

الاستنتاج: الانزيم المنقى مع حاصلية انزيمية مقبولة ممكن ان تفتح طريقا نحو دراسات مستقبلية لاستخدامه في استحداث الاستجابة المناعية ضد تسوس الاسنان في تجارب الحيوانية بواسطة استخدام الاجسام المضادة للصفار البيض المتخصص للخلايا المتفاعلة مع الانزيمات الكلوكوسيل ترانسفيريز GTF من المكورات الفموية .

مفتاح الكلمات: الكلوكوسيل ترانسفيريز ، المكورات الفموية Streptococcus sobrinus ، التنقية ، كروموتوغرافيا الادمصاص .

¹ قسم التقنية الاحيائية [كلية العلوم – جامعة النهرين]

² معهد الهندسة الوراثية والتقنية الاحيائية – جامعة بغداد

³ فرع الاحياء المجهرية [كلية الطب – جامعة النهرين]

المجلة العراقية للعلوم الطبية 2010 م المجلد 8 العدد 4 ص 10 – 18

تقييم المرضى المصابين بالسرطان الكلوي قبل الجراحة- مهامدات المفراس الحزوني
مقارنة بنتائج الفحص النسيجي.

محمد محمد كاظم , علا محمد رضا الكوازي , حيدر محمد الحسين

الخلاصة

خلفية الدراسة: يعتبر سرطان الكلية هو اكثر الاورام الخبيثة حدوثا في الكلية، يمثل 85-90 % من كل الأورام الكلوية الخبيثة ويُمثل 3 % من الاورام الخبيثة عند البالغين. مصير سرطان الكلية يعتمد على الحجم، مرحلة السرطان، ودرجة الورم الخبيث. أثبتت الدراسات بان المفراس هو التقنية الأكثر أهمية لتقييم الافات الكلوية وتقييم مرحلة السرطان الكلوي ما قبل الجراحة. **هدف الدراسة:** كانت لدراسة الدقة التشخيصية للمفراس الحزوني في تقييم المرضى المصابين بالسرطان الكلوي قبل الجراحة.

المرضى و طرق البحث: ما بين شباط 2008 وأيلول 2009, تضمنت هذه الدراسة المستقبلية 40 مريضاً (مدى العمر، 36-66 سنة؛ 28 رجل، 12 امرأة) مصاباً بأورام كلوية صلبة. اظهر

المفراس وجود سرطان الكلية، اجريت عملية رفع الكلية و اثبت سرطان الكلية بوساطة الفحص النسيجي للعينات المستنصلة. اجري فحص المفراس الاولي لجميع المرضى بدون استخدام مادة ملونة، تم استخدام 100 مليلتر من المادة الملونة عن طريق الحقن الوريدي وتم اعادة فحص المفراس بعد 120 ثانية بعد حقن المادة الملونة، الفحص الاول و الثاني يجب ان يغطي كامل اجزاء البطن. تم حساب النسبة المئوية للعناصر المستخدمة في الدراسة. تم حساب الدقة التشخيصية لتقييم مرحلة السرطان الكلوي بوساطة المفراس.

النتائج: حجم الورم تراوح من 1,7 إلى 6,5 سنتيمتر (بمعدل 3,1 سنتيمتر). جميع المرضى اظهروا دليل افراز الورم للصبغة بحوالي 47 وحدة. سبعة وثلاثون مريض (92,5%) اظهروا افراز متباين للصبغة بينما فقط 3 مرضى (7,5%) اظهروا افراز متجانس. لوحظ وجود التكلس في 10 مرضى (25%). الكبولة الكاذبة حوم الورم كانت موجودة في 16 من المرضى. تآثر العقد المفاوية مع قطر أكبر من سنتيمتر واحد وجد في 7 مرضى (17,5%)، فقط مريض واحد (2,5%) اظهر تشخيصا خاطئا سلبيا بالنسبة لتآثر العقد المفاوية. الدقة التشخيصية لكشف العقد المفاوية كانت 83%. تخثر الوريد الكلوي و الوريد الاجوف الاسفل اكتشف في 8 مرضى (20%)، الدقة التشخيصية كانت 87,5%. الدقة التشخيصية العامة للمفراس في حالات السرطان الكلوي كانت 90%.

الاستنتاجات: المفراس هو تقنية ممتازة لتقييم الافات الكلية الصلبة وتقييم مرحلة السرطان الكلوي ما قبل الجراحة. كانت هناك بعض الصعوبة في تمييز المرحلة 3 و 2 لسرطان الكلية بوساطة المفراس. المفراس ذو قدرة محددة لتمييز تآثر العقد المفاوية بالورم الخبيث لأنه ما زال يستند على معايير الحجم فقط، باعتبار 10 مليمتر كحجم للعقد الطبيعية.

مفتاح الكلمات: المفراس الحلزوني, تقييم مرحلة السرطان ما قبل الجراحة, السرطان الكلوي.

المجلة العراقية للعلوم الطبية 2010 م المجلد 8 العدد 4 ص 19- 27

دراسة طبية عدلية عن وفيات الولدان في بغداد

فائق أمين بكر¹, حسين محمود غازي², نبيل غازي هاشم الخطيب³

الخلاصة

خلفية الدراسة: أجريت دراسة ميدانية في معهد الطب العدلي في بغداد عن وفيات الولدان. **هدف الدراسة:** تمييز الولادات الميتة عن الحية في الولدان المشمولين بالبحث، ومعرفة أسباب الوفاة بالنسبة للولادات الحية.

طرق العمل: تم اجراء التشريح الطبي العدلي الاصولي على كافة جنث الولدان المحالة الى معهد الطب العدلي في بغداد لمدة ستة أشهر من 1996/10/1 الى 1997/3/31 والبالغة (17) جنثة، مع اجراء الفحوص المختبرية اللازمة، وتنظيم النتائج في جداول واشكال البحث.

النتائج: بلغت نسبة وفيات الولدان (6.37%) من مجموع وفيات الاطفال الطبية العدلية الى عمر (12) سنة أثناء مدة اجراء البحث، وكانت أعلى نسبة لتلك الوفيات في شهر شباط من العام (1997)، وكان عدد الولادات الحية أكثر قليلا من الميتة وبدون فارق احصائي أو معنوي مهم. وشكل ذات الرئة القصبية أكثر أسباب وفيات المولودين أحياء. اضافة الى النتائج الاخرى للدراسة.

الاستنتاجات: قلة نسبة وفيات الولدان في بغداد (أثناء مدة اجراء البحث) وخاصة الجنائية منها، وما لذلك من أهمية طبية عدلية وتحقيقية واجتماعية.

مفتاح الكلمات: طبية عدلية، وفيات، الولدان.

¹ طبيب عدلي استشاري

² فرع علم الامراض والطب العدلي [كلية الطب - الجامعة المستنصرية]

³ فرع علم الامراض والطب العدلي [كلية الطب - جامعة بغداد]

المجلة العراقية للعلوم الطبية 2010 م المجلد 8 العدد 4 ص 28-33

حفظ التمايز العضلي القلبي للخلايا الجذعية البالغة لنقي العظم في الجرذان البيض باستخدام 5-azacytidine

إنتظار محمد مناتي

الخلاصة

خلفية الدراسة: للخلايا الجذعية اللحمية القابلية على التكاثر والتجديد والتمايز الى انواع مختلفة من الخلايا خارج الجسم الحي ومن ثم امكانية استعمال هذه الخلايا طبيا لاغراض العلاج والاستبدال النسجي.

هدف الدراسة: اجريت هذه الدراسة لغرض عزل وزراعة الخلايا الجذعية البالغة من نقي عظم الجرذان البيض *Rattus rattus norvegicus albinus* وبشكل خاص الخلايا الجذعية اللحمية وانماؤها وتكثيرها خارج الجسم الحي والحفاظ عليها بحالة فعالة لعدة أسابيع.

طريقة الدراسة: عرضت المزارع الثانوية الناجحة في اليوم الثاني من الزراعة الى الوسط الزراعي من نوع الوسط الزراعي الاساس الادنى MEM مضاف اليه 5-azacytidine بتركيز 10مايكرومول/ لتر.

النتائج: اظهرت نتائج الدراسة التي اجريت خارج الجسم الحي ان الخلايا الجذعية اللحمية تبدو بشكل شبيه بالارومة الليفية قبل المعاملة بـ 5-azacytidine ولكن يبدأ شكلها بالتغاير بعد المعاملة بـ 5-azacytidine وبنسبة 50% من أعداد الخلايا الملتصقة تقريبا، حيث ترتبط هذه الخلايا مع الخلايا المجاورة لها بعد اسبوع واحد من المعاملة وتبدأ بتكوين تراكيب شبيهة بالانبوب العضلي في نهاية الاسبوع الثاني. اظهرت نتائج الدراسات الكيميائية النسجية المناعية تمايز الخلايا الجذعية اللحمية الى خلايا عضلية شبيهة بالخلايا القلبية والتي تم الكشف عنها باستعمال واسم خاص anti-cardiotin وقد اعطت نتائج التصبيغ الكيميائي الخلوي المناعي للخلايا الناتجة من التمايز استجابة موجبة لهذا النوع من الواسم.

الاستنتاج: للخلايا الجذعية اللحمية للجرذان القابلية على التكاثر بشكل واسع خارج الجسم الحي ويمكن حثها للتمايز كيميائيا الى خلايا عضلية قلبية باستخدام 5-azacytidine .

مفتاح الكلمات: خلايا السدى لنقي العظم، التكاثر، التمايز، 5-azacytidine، زراعة الخلايا .

فرع علوم الحياة [كلية التربية - ابن السني - جامعة بغداد]

المجلة العراقية للعلوم الطبية 2010 م المجلد 8 العدد 4 ص 34 – 40

نسبة حدوث حالات الهذيان بين المرضى الراقدين في ردهات الطب الباطني في

مستشفى تعليمي في بغداد

مدي خالد محمد الجبار

الخلاصة

خلفية الدراسة: الهذيان هو متلازمة تمتاز بتطور سريع لتغيرات متباينة ومتحولة في وظيفة الانتباه مما يؤدي التشوش مستوى الوعي وحالات من الاوهام البصرية عادة وتحصل بالنتيجة اضطرابات سلوكية ويكون السبب في كل هذه الاضطرابات هو تغيرات فسلجية في الدماغ ناجمة عن حالة مرضية داخلية. تقدر نسبة حصول الهذيان ب 15-20% بين مرضى ردهات الطب الباطني في الدراسات السابقة.

هدف الدراسة: تهدف الدراسة الى قياس نسبة حدوث حالات الهذيان بين المرضى الراقدين في ردهات الطب الباطني في مستشفى تعليمي في بغداد ومن ثم دراسة علامات واعراض الهذيان لدى هؤلاء المرضى.

طرق الدراسة: تمت دراسة مقطعية لكافة المرضى الراقدين في ردهات الطب الباطني في مستشفى الكاظمية التعليمي في بغداد للفترة من 21 مارس 2008 الى 21 نيسان 2008 وتم استثناء المرضى الذين يعانون من مرض نفسي مسبقا واولئك من هم دون عمر 18 سنة. تم اعتماد المراجعة الرابعة للكراس التشخيصي الاحصائي في تشخيص حالات الهذيان بعد احالتهم من قبل الطبيب المقيم المسؤول عن المرضى وتم استحصاال موافقة ذوي المريض على اجراء المقابلة التشخيصية.

النتائج: عدد المرضى الراقدين خلال فترة الدراسة كان 510 مريضا وكانت نسبة حدوث الهذيان بينهم حوالي 3%.

الاستنتاج: تعتبر نسبة حدوث الهذيان في هذه الدراسة واطئة وهذا ناتج عن طبيعة الطرق المستخدمة والعينة المدروسة مقارنة بالدراسات الاخرى.

مفتاح الكلمات : الهذيان, المرضى الراقدين, الطب الباطني

فرع الطب الباطني [كلية الطب – جامعة النهرين]

المجلة العراقية للعلوم الطبية 2010 م المجلد 8 العدد 4 ص 41 - 46

تقييم ومقارنة تأثير الحديد الوريدي مع الفموي على فقر الدم في المرضى المصابين بقصور الكلية المزمن

مارف سامي مالك

الخلاصة

خلفية الدراسة: يُحسَّنُ تصحيحُ فقر الدم عند المرضى المصابين بالفشل الكلوي الوظيفية القلبية الوعائية ويزوّدُ منافع إدراكية وعاطفية هامة أيضاً. الطريق الأكثر ملائمة للعلاج بالحديد متباين ومختلف عليه للمرضى المصابين بالفشل الكلوي المزمن الذين لم تجرى لهم عملية الديليز. **هدف الدراسة:** تهدف هذه الدراسة تقييم ومقارنة تأثير الحديد عن طريق الفم والحديد دكستران الوريدي على فقر الدم عند المرضى المصابين بقصور الكلى المزمن.

طرق الدراسة: خمسة وأربعون مريضاً مصاباً بفقر الدم نتيجة إصابتهم بعجز الكلية المزمنٍ مستقبلياً يتلقوا (كبريت حديدوز 200 مللي غرام فموي ثلاث مرات يومياً، أو وريدي (دكستران الحديد 300 مللي غرام/ شهرياً)، مدة المعالجة كانت ستة شهور.. (ارثروبويتين rHuEpo) شرع بشكل آني والجرعة عدلت طبقاً للنظام المؤسّس.

النتائج: لا توجد هناك اختلافات هامة في خصائص مرضى الخط الأساس بين المجموعتين. أربعة مرضى عانوا رد الفعل الحساس المحتمل للحديد دكستران. نتيجة الهيموغلوبين في النهاية من الدراسة كانت متماثلة في المجموعتين، لكن فرتين المصل أعلى في المجموعة الوريديّة. أوقفت الجرعة البادئة لـ rHuEpo بشكل مؤقت في المرضى على الحديد الفموي أما الذين يأخذون دكستران الحديد الوريدي فإن عقار الأرتروبويتين زيد بعد 3 شهور، أو كانت (33.5) و(41.6) وحدات / كيلو غرام / أسبوع على التوالي في المجموعة الفموية والوريديّة. بالرغم من أن الأعراض المعوية كانت مخبرة عنها عموماً أكثر في المرضى التي تأخذ حديداً عن طريق الفم.

الاستنتاج: في المرضى المصابين بالقصور الكلوي قَبْلَ غسل الكلية؛ 300 مللي غرام حديد دكستران بشكل وريدي ليست متفوقة فيما يتعلق بالاستجابة في زيادة الهيموغلوبين واحتياج جرعة الأرتروبويتين أو كما هو مُقارن بالجرعة اليومية الفموية 300 مللي غرام من كبريت الحديدوز أو المكافئ.

مفتاح الكلمات: قصور الكلى المزمن، الأرترو بويتين، الأنفاذ، فرتين، دكستران الحديد

فرع الطب الباطني [كلية الطب - جامعة النهرين]

المجلة العراقية للعلوم الطبية 2010 م المجلد 8 العدد 4 ص 47-52

تعدد الجملات: مضامين تشريحية وسريية

محمد عودة سلمان

الخلاصة

خلفية الدراسة: ظاهرة تعدد الحلمات تشمل حلما إضافية عند اللبائن , وتظهر هذه الحلمات الإضافية في طور الجنيني من الحياة , وكجزء من النمو غير الطبيعي للغدة اللبنية .
هدف الدراسة: لشرح حالة تعدد الحلمات والاحتماليه الاكثر لمواقعها لاعطاء ذلك بعمل تحري استباقي لهذه الحالات في سلسله من الملاحظات. واذا ما وجدت اي وراثه جينيه لحاله.
طريقة الدراسة: تم جمع 43 حاله من تعدد الحلمات .وقد جمعت من رواد عياده طبيه خاصه لممارس عام في بغداد. وقد لوحظت حالات تعدد الحلمات اثناء الفحص الفيزياوي الروتيني المتضمن فحص الصدر والبطن.

النتائج: من 43 حاله من تعدد الحلمات, الرجال يشكلون 23 (53.5%) من الحالات. فيما يتصل بالموقع التشريحي لتعدد الحلمات, و2 (4.65%) حاله تقع على الطيه الابطييه الاماميه, 28 (65.1%) حاله تقع على الجدار الصدري الامامي . 12 (27.9%) حاله تقع على الجدار البطني الامامي, وحاله واحده (2.3%) تقع في النطقه المغبنيه. هناك فقط 5 حالات (11.6%) تملك تاريخ عائلي من الحالات المشابهه السابقه.

الاستنتاج: تعدد الحلمات شذوذ مألوف بشكل واضح . الرجال والنساء ربما لديهم حلمات اضافيه ولكن لم يُكتشف فرق ذواهميه يعود الى الاختلاف الجنسي. بالرغم من ان وجود تعدد الحلمات في بعض الاحيان يربط الى امراض في القلب لكن لم تلاحظ هذه العلاقه. كل الحالات في هذه الدراسه لتعدد الحلمات وقعت على طول خط الطيب. بالرغم من ان وجود حلمات اضافيه قد سجلت في القدم .
مفتاح الكلمات: تعدد الحلمات, الغده الثدييه.

فرع التهرج البهري [كلية الطب – جامعة النهرين]

المجلة العراقية للعلوم الطبية 2010 م المجلد 8 العدد 4 ص 53- 56

تقييم تغيير لون الأكريل الراتنجي الحراري بواسطة الفحص البصري ومقياس طيف الأشعة تحت الحمراء بعد عملية الغمر في غسول أطقم الأسنان الكيماوية.

إسراء محمد حمودي , الاء عزيز محمد المجيد

الخلاصة

خلفية الدراسة : تستخدم مواد غسول اطقم الاسنان لازالة ومنع تكوين الصفيحة الجرثومية. ان فائدة هذه المواد الكيماوية هي انها تصل الى كافة اجزاء الطقم وبصورة متساوية. واحدة من اهم المشاكل المصاحبة لمادة الغسول هي تغير لون قاعدة اطقم الاسنان الراتنج اكريلية.

هدف الدراسة: الهدف من هذه الدراسة هي تقييم تأثير مختلف غسول اطقم الاسنان على لون مواد قاعدة طقم الاسنان الراتنج اكريلية.

طريقة الدراسة: تم تحضير 45 عينة من مادة الاكريل الراتنجي (50×3.5×3 ملم) (طول×عرض×سمك) وبعد عملية التكيف في الماء المقطر غمرت هذه النماذج في ثلاثة انواع من غسول اطقم الاسنان وهي مادة القاصر 0.5% ومادة الخل الابيض (حامض الخليك 6%) بالاضافة الى الماء المقطر خلال شهر مع استمرار تبديل الغسول ثلاث مرات يومياً وبمعدل 8 ساعات.

تم تقييم تغير اللون باستخدام مقياس طيف الاشعة تحت الحمراء المبرمج كما تم الاختبار البصري بواسطة ثلاثة باحثين مستقلين.

النتائج: لقد اظهرت النتائج انه ليس هناك فرق في تغير اللون على مادة قاعدة اطقم الاسنان الاكريل راتنجي بواسطة الفحص المرئي كما اظهرت انه ليس هناك أي تفاعل بين الغسول المستخدمة ومادة الاكريل راتنجي بواسطة مقياس طيف الاشعة تحت الحمراء المبرمج.

الاستنتاج: استنتج بان غسول اطقم الاسنان لا تسبب أي تغيير في لون مواد قاعدة اطقم الاسنان الراتنج اكريلية اذا استخدمت حسب التعليمات والارشادات.

مفتاح الكلمات: الاكريل الراتنجي – غسول طقم الأسنان – تغير اللون .

خاتمة التنبؤات الصحية والطبية

التقييم السريري للعلاج الليزر ذو المستوى الواطئ في شفاء جروح الجلد في جراحة الوجه والفكين

عمار صالح رضا العلوي¹ , حسين علي جواد² , اياد محمد اسماعيل³

الخلاصة

خلفية الدراسة: إلتئام الجروح هي عملية معقدة متفاعلة متكاملة تتضمن فعالية خلوية وانجذاب كيميائي واطلاق وسائط كيميائية واستجابة وعائية دموية بحيث تتكون من عدة اطوار, الطور الالتهابي, الطور التكاثري والطور البنائي. العلاج بالليزر ذو المستوى الواطئ اكثر فاعلية وتأثير في الاطوار المتداخلة الثلاثة لعملية الالتئام يظهر التحفيز الاحيائي ليمتلك تأثيرا على المستوى الخلوى بزيادة الوظائف الخلوية وتحفيز انقسام الخلايا.

هدف الدراسة: هدف الدراسة هو تقييم فعالية الليزر الثنائي الصمام ذو المستوى الواطئ في شفاء جروح جلد الانسان سريريا.

طريقة الدراسة: انجزت الدراسة على 20 مريضاً (10 ذكور و 10 اناث) وكانت اعمار المرضى تتراوح من (5-75) وكان المرضى يعانون من اضرار في منطقة الفم والوجه والفكين. بعد اكتمال التداخل الجراحي, قسمت الجروح الى جزئين, الجزء الاول شعع بالليزر الثنائي الصمام بكثافة قدرة 1,25 واط/سم 2 ووقت تعرض للتشعيع 50 ثانية والجزء الثاني تركت بدون تشعيع كجروح ضابطة. قيمت النتائج على اساس وجود الوذمة والاحمرار خلال يومين بعد العملية سريريا.

النتائج: كشفت الملاحظات السريرية نقصاناً واضحاً في الوذمة وزيادة في الاحمرار على سطح الجلد واثر الجرح (الندب) كان نحيفا جدا في الجروح المعالجة بالليزر مقارنة بالجروح الضابطة. **الاستنتاج:** العلاج بالليزر ذو المستوى الواطئ له تأثير وتسريع عملية التئام جروح الجلد للانسان.

مفتاح الكلمات: التئام الجرح , التحضير الاحيائي , علاج الليزر ذو المستوى الواطئ

¹ مستشفى الطائفة التعليمية . هبة جراحة الوجه والفكين

² معهد الليزر للدراسات العليا . جامعة بغداد

³ مستشفى الجراحات التخصصية . مدينة الطب

تشخيص أنواع مستعمرات الخلايا المكونة للدم المتهتمة من دم الحبل السري للإنسان في المزرعة

بهداء حسين مطلق

الخلاصة

خلفية الدراسة: يحوي دم الحبل السري على الخلايا الجذعية المكونة للدم والتي تعد مصدراً متوفراً لزراعة الخلايا .

هدف الدراسة : هدفت الدراسة الحالية الى تشخيص أنواع المستعمرات الخلوية المكونة للدم في الإنسان وإيجاد التركيز المناسب في تجارب إعادة الزرع .

طريقة الدراسة: جمعت عينات دم الحبل السري من مشيمة الولادات الحديثة للأمهات اللواتي ولدن طبيعياً في مستشفى الكاظمية في بغداد. وتم عزل الخلايا وزراعتها في مركز البحوث الطبية/كلية الطب /جامعة النهرين للفترة من شباط الى نيسان 2007.

تم عزل الخلايا الأحادية الأنوية باستخدام الطرد المتدرج الكثافي وحددت أعداد وحيوية الخلايا الأحادية الأنوية باستخدام المثيل الأزرق. تضمنت الدراسة الحالية خطين:-

- 1- التحليل الكيميائي الخلوي المناعي للخلايا الأحادية الأنوية للواسم CD34.
- 2- زراعة الخلايا الأحادية الأنوية في تراكيز مختلفة لغرض تحديد التركيز المناسب في تجارب إعادة الزرع. زرعت الخلايا الأحادية الأنوية في الوسط الزراعي (RPMI+10%FCS) وعدل الوسط الزراعي بأضافة PHA. حفظت المزارع في ظروف 37 هم و 5% Co2 وبيئة رطبة لمدة 14 يوماً.

النتائج: أظهرت نتائج التصيبغ الكيميائي الخلوي المناعي إن الخلايا الأحادية الأنوية ذات إستجابة موجبة للواسم CD34, وان الوسط الزراعي المعدل له دور في ظهور المستعمرات المكونة للدم .

يمكن تميز المستعمرات المكونة للدم عن باقي أنواع المستعمرات في موقعها الأصلي في المزارع بالغياب الكامل لعلامات التمايز النهائي.

الاستنتاج: اكدت نتائج الدراسة الحالية ان دم الحبل السري يعد مصدراً كبيراً للحصول على الخلايا الجذعية المكونة للدم والتي تستخدم في التطبيقات الطبية .

مفتاح الكلمات: مستعمرات الخلايا المكونة للدم, دم الحبل السري للإنسان, في المزرعة

فرع علوم الحياة [كلية التربية - ابن الهيثم - جامعة بغداد]