

## Radiological and Clinical Results of Pemberton Osteotomy for Delayed Presentation of Iraqi DDH Patients

Zuhair A. Chhaily<sup>1</sup> FIBMS (ORTHO), Ahmed I. Joda<sup>1</sup> FIBMS (ORTHO), Adel A. Hafith<sup>2</sup> DRMR (RHEUM), Wasan H. Abbood<sup>3</sup> (FABHS.CM)

<sup>1</sup>Section of Orthopedic, Dept. of Surgery, Al-Imamein Al-Kadhimein Medical City, Baghdad, Iraq, <sup>2</sup>Section of Rheumatology, Al-Imamein Al-Kadhimein Medical City, Baghdad, Iraq, <sup>3</sup>Section of Public Health, Al Al-Immamain Alkadhumein Medical City, Baghdad, Iraq

### Abstract

- Background** Pelvic osteotomy is a major procedure required for lately presented with developmental dysplasia of hip (DDH) patients; one of the needed osteotomies of the pelvis in such patients is Pemberton osteotomy (P.O.).
- Objective** To evaluate the clinical and radiological results of the P.O. for delayed presentation of Iraqi DDH patients.
- Methods** The study was conducted at Al-Imamein Al-Kadhimein Medical City from 2014-2020. We did the osteotomy for 32 hips of 25 patients (no one of them have neuromuscular disease). Of them 28 hips were Tönnis stage IV, 4 stage III, and 2 stage II.
- Results** The clinical status of all patients has improved according to modified McKay criteria, 26 of them have excellent score, 4 have good score, 2 with fair results, but no one has bad results. Radiologically, we score Severin's classification as 62.5% with excellent, 28.1% with good, 9.4% with fair stage, and zero for bad stage. The average acetabular index corrected from 41.34° into 16.17°. The center edge angle of Wiberg reached 32.34°. The VCA of Lequesne became 29.66°. And the ACM angle became 43.33°. Avascular necrosis was reported as 1 hip was class I and 1 hip as class II according to Kalamchi McOwen classification.
- Conclusion** Although Salter R.B. when published his article about his osteotomy discussed the P.O. as one option for pelvic osteotomies meanwhile Pemberton P.A. still not publishing his article until after 4 years even it was practiced well before that time! We found that P.O. is very useful and dependable for clinical improvement and for correcting the radiological parameters to normal values yet it is simple, safe, practical, and effective osteotomy.
- Keywords** Pemberton osteotomy, delayed DDH, Tönnis classification, Severin's classification, modified McKay classification, Kalamchi McOwen classification
- Citation** Chhaily ZA, Joda AI, Hafith AA, Abbood WH. Radiological and clinical results of Pemberton osteotomy for delayed presentation of Iraqi DDH patients. *Iraqi JMS*. 2021; 19(2): 182-188. doi: 10.22578/IJMS.19.2.7

**List of abbreviations:** ACM = Angle of acetabular depth, AI = Acetabular index, AVN = Avascular necrosis, CEA = Center edge angle, DDH = Developmental dysplasia of hip, VCA = Vertical center anterior acetabulum angle

### Introduction

Management of Developmental dysplasia of hip (DDH) patients impose great challenge to the pediatric orthopedic surgeon at any age group,

but it is more challenging at the walking age and older <sup>(1,2)</sup>. At this age group, the open reduction for dislocated hips is mandatory and it could be so for subluxated ones immediately or after it becoming dislocated completely. After the age of 1.5 years, the growth and development of dysplastic hip becoming slow and may not get deeper and well covering unless pelvic osteotomy is done <sup>(3,4)</sup>. Many surgeons design and others modify a number of osteotomies; Pemberton osteotomy (P.O.) remains one of the older types, yet it still provides very good outcomes <sup>(5)</sup>. Unlike Salter who believed that the deficit in the anterior and lateral hip coverage is caused by excessive acetabular anteversion and hence its osteotomy re-orient the acetabulum into more retroverted position, Pemberton believe that the acetabulum is not retroverted but it is undergrown anteriorly and laterally and need not to re-orient but to augment the anterior and lateral coverage by re shaping the upper part of the acetabulum <sup>(6)</sup>.

This study was made to evaluate the improvement achieved for DDH patients by pericapsular P.O. radiologically and clinically.

## Methods

Thirty-two hips (25 patients) were treated at Al- Al-Imamein Al-Kadhimein Medical City from 2014-2020; of them 12 have bilateral DDH and 8 were unilateral with 3 males and 22 females. There ages ranges from 56 months (4 8/12 years) to 77 months (6 5/12 years) with average of 62 months (5 2/12 years). Of them 2 hips were grade II, 4 hips grade III, and 26 were grade IV according to Tonnis classification <sup>(7)</sup>.

All of patients have had preoperative pelvic anteroposterior (AP) radiograph and validated for tilting and rotation for classification and measuring acetabular index (AI) <sup>(8,9)</sup>. The mean AI preoperatively was 41.34 (ranging from 30-46). All were prepared for general anesthesia with preparation of 1 pint of blood. All have had adductor muscles myotomy except 3 hips. All have had open reduction and P.O. at the same session. Twenty-seven (27) patients have had femoral shortening at the time of open

reduction, and 10 have had derotation with the shortening. The rotation was judged clinically intraoperatively. In the first 6 cases the C-arm fluoroscope was used for performing the P.O.

All patients were put in one and half hip spica for 5-6 weeks after that a Petrie cast under general anesthesia was used for another 5-6 weeks, after that they were freely moving at home for another 2 weeks before starting official physiotherapy.

Postoperatively all patients received parenteral antibiotics for 5 days then oral antibiotic for another 5 days with regular oral analgesia for 5 days and parenteral analgesia on need. Stitches of the adductor myotomy were removed after 2 weeks and the stitches of the remaining wounds were removed with the removal of the hip spica under general anesthesia.

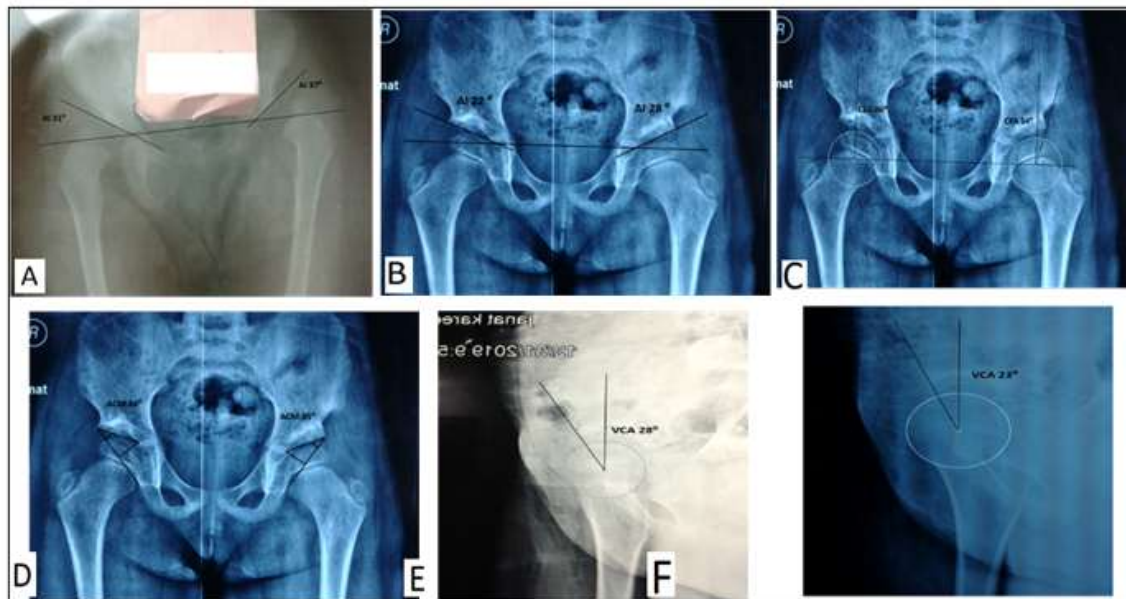
Postoperatively AP X-ray view was taken at the day of surgery, 6 weeks, after removal of Petrie cast (10-12 weeks), and at 16 weeks post operatively unless it is needed for some times to excludes fractures during physiotherapy. Then every 2 months for the first year and then at 1-year interval. A false lateral profile view was taken at the last interview. The average follow-up was 36.66 months (range from 8-68 months).

## Results

All the 32 hips immediately post operatively achieved radiological reduction and the osteotomy seems maintaining its position (i.e., the bone graft not slipped away). The osteotomy is healed by the 2<sup>nd</sup> radiological examination (i.e., at the 6<sup>th</sup> week). Post operatively, the hips were 20 hips class IA, 9 hips class IB and 3 class II of modified Severin's criteria <sup>(10)</sup>. The average AI at the 1<sup>st</sup> X- ray examination was 19.23° (range from 11°-23°), and at the last interview was 16.17° (range from 7°-21°). The angle of acetabular depth (ACM), the center edge angle (CEA) of Wiberg, and vertical center anterior acetabulum angle (VCA) was recorded at the last interview <sup>(11-13)</sup>. The average ACM was 43.33° (range from 40°-52°). The average CEA of Wiberg was 32.34° (range from 25°-37°). The average VCA was 29.66° (range from 22°-34°). According to

## Chhaily et al, *Pemberton Osteotomy for DDH*

modified McKay criteria <sup>(14)</sup>, 26 achieved fair results. No one had bad results (Figures 1 & 2).  
excellent results, 4 had good results, and 2 had

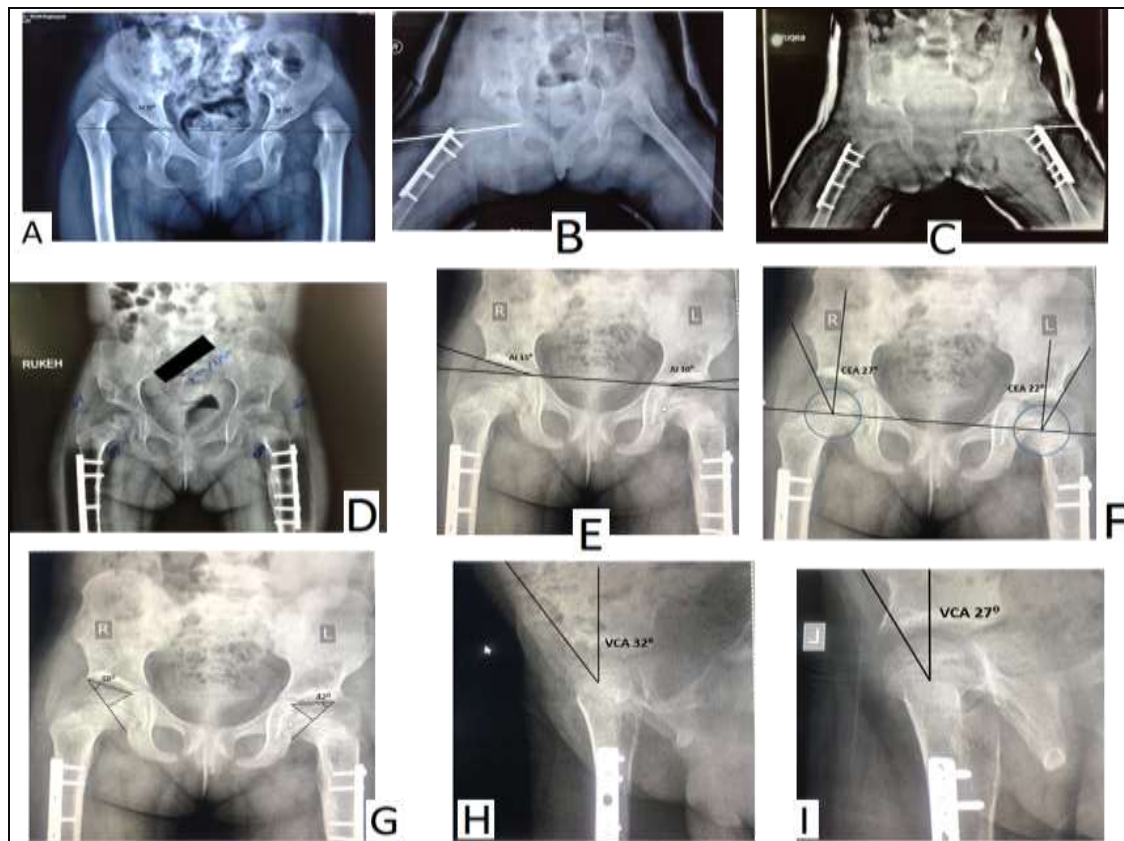


**Figure 1.** Patient of 4 3/12-year age at presentation with bilateral DDH. The left side had open reduction plus Salter osteotomy and the right side had open reduction plus Pemberton osteotomy. A: preoperatively the AI of right side is 31° and of left side is 37°. B: after 29 months post Pemberton osteotomy of the right side the AI is 22°; and on the left side, 36 months post Salter osteotomy, the AI is 28°. C: the right CEA is 26° and the left CEA is 14°. D: the right ACM is 36° and the left ACM is 35°. E: the right VCA is 28°. F: left VCA is 23°

### Complications

No patient has infection of wound. Two patients have supracondylar femoral buckling greenstick fracture in one of their femurs during physiotherapy; one was treated by hip

spica for 2 weeks and the second discovered after healing. Two hips in 2 patients had avascular necrosis (AVN); one was grade I and the other was grade II according to Kalamchi and McOwen classification <sup>(15)</sup>.



**Figure 2.** Patient of 48/12-year age at presentation with severe bilateral grade IV DDH with a well-defined false acetabulae. A: The AI of right and left hips are  $39^{\circ}$  and  $39^{\circ}$  respectively at the presentation. B: immediately post operatively of right hip open reduction + femoral shortening and derotation at the subtrochanteric region + Pemberton osteotomy. The reduction was held by K- wire for 6 weeks. C: the same was done for the left side. D: the patient 1 year after surgeries with concentric reduction, well developed acetabulae, and complete healing of the femoral osteotomies. E: 3 years after surgeries, the AP view of the hips have AI of right and left hips are  $15^{\circ}$  and  $10^{\circ}$  respectively. F: CEA right hip is  $27^{\circ}$  and  $22^{\circ}$  of the left hip. G: the ACM angle of the right hip is  $38^{\circ}$  and  $42^{\circ}$  of left one. H: the right VCA is  $32^{\circ}$ . I: the left VCA is  $27^{\circ}$

## Discussion

Pelvic osteotomy is the key for successful treatment of DDH patients older than 1.5 years (16,17). In our experience, Salter osteotomy seems the most commonly used osteotomy in such patients (6). Yet still other osteotomies like Pemberton, Shelf, and even Dega osteotomy are in use by some pediatric orthopedic surgeons (5). Although Salter introduced his osteotomy (at 1961) 4 years after Pemberton osteotomy (at 1957), it gains more popularity at our pediatric orthopedic surgery society. Pemberton osteotomy needs relatively fewer soft tissues dissection around the sciatic notch

thus, decreasing blood lose and avoiding violation of the structures passing through it, especially if the C-arm device is used to determine the limits of posterior limb of cutting in the outer and inner ilium tables. Also, the omitting of using Gigli saw (which is used in Salter osteotomy) will reduce the time and complications of saw jamming during cutting the innominate bone. In Pemberton osteotomy, we can direct the coverage whether anteriorly or laterally according to patient's acetabulum deficit. This versatility of Pemberton osteotomy in directing the coverage, also present in the magnitude in

reducing AI angle, which may reach to zero or even much which can't be done in Salter osteotomy without jeopardizing posterior hip stability. One of the advantages of Pemberton osteotomy is the stability of it of holding the bone graft without the need of fixation and so omitting the need for another surgery for hardware removal under anesthesia. In Pemberton osteotomy, we are augment the anterior +/- lateral acetabular deficiency thus, increasing the acetabulum retroversion and improving the acetabulum encompassing around femoral head without affecting posterior stability. Although some texts entail a relatively large acetabulum and small femoral head as a prerequisite for Pemberton osteotomy<sup>(18)</sup>, however, Pemberton himself didn't says this as a primary requirement for his pericapsular osteotomy, even more he did it in patient who have hip subluxation without performing open reduction i.e., a primary pelvic osteotomy in hip dysplasia as a sole surgical procedure. Although the Pemberton osteotomy will reduce the circumference of acetabulum margin, actually it increases the acetabulum volume by increasing its depth and by this it makes the hip even more stable.

Many authors evaluate the Pemberton pericapsular osteotomy and compare the results with other osteotomies regarding the clinical and some radiological results especially on anteroposterior views to evaluate the ability of the osteotomy in restoring the normal architecture and appearance of the acetabulum in DDH patients in coronal view<sup>(19-24)</sup>. Kessler et al. have a mean postoperative AI of 18°, versus the preoperative mean of 33° (with 15 gain)<sup>(25)</sup>. Mehmet et al. have 22.42 gain in AI<sup>(26)</sup>. Badrinath et al. found 14.2 gain in AI<sup>(19)</sup>. Gordon et al. in their study estimated the CEA as 28°<sup>(27)</sup>. Aydin et al. found a preoperative mean AI of 40.53 and final AI of 12.04°, (gain of 28.49) and a mean CEA of 35.5°<sup>(28)</sup>.

To our knowledge, only recently Wang et al. study, the anterior coverage of the osteotomy radiologically in some details where he has VCA of 43°<sup>(29)</sup>, (normal value of VCA is more than 25°). The table 1 shows the results of some studies that evaluate the results of Pemberton osteotomy.

It is clear that there are some differences in the methods in evaluating DDH patients preoperatively and postoperatively (like preoperative classification and the postoperative results). Also, because of the great differences in the results of the same issue like AVN, we can see clearly the wide range of differences in the results of these studies or articles<sup>(30,31)</sup>. And because of the wide range of parameters in patients with DDH (like age at surgery, preoperative methods of treatment such as traction or splintage, gender, uni or bilaterally hips, and the need of other procedures such as femoral surgeries, all of these can make the results very variable for these studies and articles. So, we need to unify the patients in very similar criteria and make studies for groups of patients with very similar associated pre and postoperative conditions.

The results in the current study in regard to clinical finding seems to be close to other studies that evaluate Pemberton osteotomy elsewhere. The measured parameters on the AP and false profile of hip in the current study reached the patient with the operated hips to the normal values in the normal population<sup>(32,33)</sup>.

The good radiological parameters approaching the normal figures with good clinical patient performance plus the relative surgical simplicity of Pemberton osteotomy and its many advantages, we are encouraging pediatric orthopedic surgeons to practice it in their work and popularize it. At the same time, it needs much more extensive and longer follow up studies to delineate its validity and its scope in treating DDH patients at different age groups.

**Table 1. Summary of some studies with their results compared with our current one**

		Balioglu et al (26)	Badrinath et al (19)	Aydin et al (28)	Ertürk et al (23)	Current study
Duration		2001 - 2006	2006 -2015		2001 – 2009	2014 – 2020
Number		14	38	91	50	32
Tonnis classification	I	-	-	-	-	0 (0.0%)
	II	5 pt	-	24.2 %	-	2 (6.2%)
	III	-	-	41.8 %	12 pt	4 (12.5%)
	IV	9 pt	-	34.1 %	38 pt	28 (81.2%)
Severin's classification	ex	78.57% Ia	92 %	86.8 %	-	20 (62.5%)
	good	7.14% Ib	5 %	7.7 %	-	9 (28.1%)
	fair	7.14% II	3 %	5.5 %	-	3 (9.4%)
	bad	7.14% III	0 %	0 %	-	0 (0.0%)
AI	Pre	41.92	24.3	40.53	40.21	41.34
	post	19.5	10.1	12.04	20.11	16.17
	Gain	22.42	14.2	28.49	20.1	25.17
CEA		24.24	33.9	35.5	31.01	32.34
VCA		-	-	-	-	29.66
ACM		-	-	-	-	43.33
McKay staging	v.g	92.85%	63 %	89 %	-	26 (81.3%)
	good	7.14%	24 %	2.2 %	-	4 (12.5%)
	fair	-	0 %	8.8 %	-	2 (6.2%)
	poor	-	5 %	0 %	-	0 (0.0%)
Kalamchi-McEwen classification	I	85.71%	5 %	9.9 %	-	1 (3.0%)
	II	14.28%	0 %	7.7 %	-	1 (3.0%)
	III	-	3 %	1.1 %	-	0 (0.0%)
	IV	-	0 %	0 %	-	0 (0.0%)

ACM = Angle of acetabular depth, AI = Acetabular index, CEA = Center edge angle, VCA = Vertical center anterior acetabulum angle, ex = excellent, v.g = very good

## Acknowledgement

The authors are most grateful and would like to express their thanks to the assistants medical staff of operating theater.

## Author contribution

The patients were operated on and followed for their outcome by Dr. Chhaily, Dr. Joda, and Dr. Hafith. Research conduction, statistical analysis done by Dr. Chhaily, Dr. Abbood, and Dr. Joda.

## Conflict of interest

There was no conflict of interest.

## Funding

The authors offer all funding for the research.

## References

- Weinstein SL. Natural history of congenital hip dislocation (CDH) and hip dysplasia. *Clin Orthop Relat Res.* 1987; (225): 62-76.
- Danielsson L. Late-diagnosed DDH: a prospective 11-year follow-up of 71 consecutive patients (75 hips). *Acta Orthop Scand.* 2000; 71(3): 232-42. doi: 10.1080/000164700317411816.
- Akagi S, Tanabe T, Ogawa R. Acetabular development after open reduction for developmental dislocation of the hip. 15-year follow-up of 22 hips without additional surgery. *Acta Orthop Scand.* 1998; 69(1): 17-20. doi: 10.3109/17453679809002348.
- Harris NH. Acetabular growth potential in congenital dislocation of the hip and some factors upon which it may depend. *Clin Orthop Relat Res.* 1976; 119: 99-106.
- Pemberton PA. Pericapsular osteotomy of the ilium for treatment of congenital subluxation and dislocation of the hip. *J Bone Joint Surg Am.* 1965; 47: 65-86.
- Salter RB. Innominate osteotomy in treatment of congenital dislocation of the hip. *J Bone Joint Surg Br.* 1961; 43-B(3): 72. doi: <https://doi.org/10.1302/0301-620X.43B3.518>.
- Tonnis D. *Congenital dysplasia and dislocation of the hip in children and adults.* Berlin: Heidelberg: Springer-Verlag; 1987.

8. Tonnis D. On changes in the acetabular vault angle of the hip joint in rotated and tilted positions of the pelvis in children. [Article in German] *Z Orthop Ihre Grenzgeb.* 1962; 96: 462-78.
9. Ball F, Kommenda K. Sources of error in the roentgen evaluation of the hip in infancy. [Article in Multiple languages] *Ann Radiol (Paris)* 1968; 11(5): 298-303.
10. Severin E. Congenital dislocation of the hip. *J Bone Joint Surg Am.* 1950; 32-A(3):507-18.
11. Idelberger K, Frank A. A new method for determination of the angle of the pelvic acetabulum in child and in adult. [Article in German] *Z Orthop Ihre Grenzgeb.* 1952; 82(4): 571-7.
12. Wiberg G. Studies on dysplastic acetabula and congenital subluxation of the hip joint: with special reference to the complication of osteoarthritis. *Acta Chir Scand.* 1939; 58(Suppl.): 7-38
13. Lequesne M; de Seze S. False profile of the pelvis. A new radiographic incidence for the study of the hip. Its use in dysplasias and different coxopathies. [Article in French] *Rev Rhum Mal Osteoartic.* 1961; 28: 643-52.
14. McKay DW. Comparison of the innominate and pericapsular osteotomy in the treatment of congenital dislocation of the hip. *Clin Orthop.* 1974; 98: 124-32. doi: 10.1097/00003086-197401000-00013.
15. Kalamchi A, MacEwen GD. Avascular necrosis following treatment of congenital dislocation of the hip. *J Bone Joint Surg Am.* 1980; 62(6): 876-88.
16. Böhm P, Brzuske A. Salter innominate osteotomy for the treatment of developmental dysplasia of the hip in children: results of seventy-three consecutive osteotomies after twenty-six to thirty-five years of follow-up. *J Bone Joint Surg Am.* 2002; 84(2): 178-86.
17. Marafioti RL, Westin GW. Factors influencing the results of acetabuloplasty in children. *J Bone Joint Surg Am.* 1980; 62(5): 765-9.
18. Azar FM, Beatty JH. *Campbell's Operative orthopedics.* 14<sup>th</sup> ed. Philadelphia: Elsevier; 2021. p. 1208.
19. Badrinath R, Bomar JD, Wenger DR, et al. Comparing the Pemberton osteotomy and modified San Diego acetabuloplasty in developmental dysplasia of the hip. *J Child Orthop.* 2019; 13(2): 172-9. doi: 10.1302/1863-2548.13.190004.
20. Coleman SS. The incomplete pericapsular (Pemberton) and innominate (Salter) osteotomies; a complete analysis. *Clin Orthop Relat Res.* 1974; (98): 116-23. doi: 10.1097/00003086-197401000-00012.
21. Wade WJ, Alhussainan TS, Al Zayed Z, et al. Contoured iliac crest allograft interposition for pericapsular acetabuloplasty in developmental dislocation of the hip: technique and short-term results. *J Child Orthop.* 2010; 4(5): 429-38. doi: 10.1007/s11832-010-0282-6.
22. Huang SC, Wang TM, Wu KW, et al. Pemberton Osteotomy for Acetabular Dysplasia. *J Bone Joint Surg Tech.* 2011; 1(1): e2. doi: 10.2106/JBJS.ST.K.00003.
23. Ertürk C, Altay MA, Işikan UE. A radiological comparison of Salter and Pemberton osteotomies to improve acetabular deformations in developmental dysplasia of the hip. *J Pediatr Orthop B.* 2013; 22(6): 527-32. doi: 10.1097/BPB.0b013e32836337cd.
24. Bibiana DR, Gregorio CTJ. Comparison results between patients with developmental hip dysplasia treated with either Salter or Pemberton osteotomy. *Ortho Res Online J.* 2017; 1(4): OPROJ.000519. doi: 10.31031/OPROJ.2017.01.000519.
25. Kessler JJ, Stevens PM, Smith JT, et al. Use of allografts in Pemberton osteotomies. *J Pediatr Orthop.* 2001; 21(4): 468-73.
26. Balioğlu MB, Öner A, Aykut ÜS, et al. Mid term results of Pemberton pericapsular osteotomy. *Indian J Orthop.* 2015; 49(4): 418-24. doi: 10.4103/0019-5413.159627.
27. Gordon JE, Capelli AM, Strecker WB, et al. Pemberton pelvic osteotomy and varus rotational osteotomy in the treatment of acetabular dysplasia in patients who have static encephalopathy. *J Bone Joint Surg Am.* 1996; 78(12): 1863-71. doi: 10.2106/00004623-199612000-00010.
28. Aydin A, Kalali F, Yildiz V, et al. The results of Pemberton's pericapsular osteotomy in patients with developmental hip dysplasia. *Acta Orthop Traumatol Turc.* 2012; 46(1): 35-41. doi: 10.3944/aott.2012.2613.
29. Wang CW, Wu KW, Wang TM, et al. Comparison of acetabular anterior coverage after Salter osteotomy and Pemberton acetabuloplasty: a long-term followup. *Clin Orthop Relat Res.* 2014; 472(3): 1001-9. doi: 10.1007/s11999-013-3319-6.
30. Crego CH, Schwartzmann JR: Follow-up study of the early treatment of congenital dislocation of the hip. *J Bone Joint Surg Am.* 1948; 30: 428-42.
31. Kruczynski J. Avascular necrosis of the proximal femur in developmental dislocation of the hip. Incidence, risk factors, sequelae and MR imaging for diagnosis and prognosis. *Acta Orthop Scand Suppl.* 1996; 268: 1-48.
32. Werner CM, Ramseier LE, Ruckstuhl T, et al. Normal values of Wiberg's lateral center-edge angle and Lequesne's acetabular index--a coxometric update. *Skeletal Radiol.* 2012; 41(10): 1273-8. doi: 10.1007/s00256-012-1420-7.
33. Waldt S, MD, Woertler K. *Measurements and classifications in musculoskeletal radiology.* Munich, Germany: Thieme; 2014. p. 23-32.

---

**Correspondence to Dr. Ahmed I. Joda**

**E-mail: [AhmedJoda79@yahoo.com](mailto:AhmedJoda79@yahoo.com)**

**Received Feb. 14<sup>th</sup> 2021**

**Accepted Apr. 11<sup>th</sup> 2021**