

Developmental Changes in the Genital Organs of Young Male Mice Associated with Licorice Extract Consumption by Mothers before and During Gestation.

Basima Mohammed Al –Jiboori MSc, Nisreen Khazal Faliah MSc.

Abstract

Background: Licorice (*Glycyrrhiza glabra*) is one of the most popular plants and widely consumed as a medicinal herb, which is used mainly in treatment of inflammations and improvement of reproductive performance in both females and males.

Objective: To detect the effect of licorice extract consumed by pregnant females on gonadal development of their male offspring.

Materials & Methods: Mature female mice (No:60), were divided into: experimental group (G,30mice), which subdivided into 3 equal subgroups: G1,G2 and G3(10 mice for each), given extract of licorice root(1gm/kg body weight),immersed in distilled water for 3 weeks before mating (G1) or for 6weeks before and during pregnancy (G2) or for 3 weeks during pregnancy time only(G3) . The other main group (C) was considered as control group subdivided as that with the experimental group but they were given distilled water only. Number and weights of male's newborn were recorded. After 40 days, weights of their bodies and testes were recorded; histological sections were prepared for

the testes to detect the presence of mature sperms and to measure the diameters of seminiferous tubules and thickness of their germinal walls.

Results: Highly significant increase ($P<0.01$) in litter size of all experimental groups were recorded. Young males born from treated mothers showed significant increase ($P<0.05$) in weights of both body and testes, and a highly significant increase ($P<0.01$) in the thickness and diameters of their seminiferous tubules in comparison with that born from control mothers. No significant differences were recorded between the three experimental groups.

Conclusions: consuming low dose of licorice root extract by pregnant females causes a significant increase in the numbers and weights of the offspring with clear maturation features in the gonads of young males.

Key words: fetal development, male gonads, pregnancy, licorice, mice.

IRAQI J MED SCI, 2010; VOL.8 (3): 14-19

Introduction

Plants have been used as source for medical treatment and a major resource for health care since ancient times⁽¹⁾. Licorice (*Glycyrrhiza glabra*) is one of the most popular and widely consumed herbs in the world⁽²⁾. The two major chemical constituents of licorice are glycyrrhizin and flavonoid which have anti-inflammatory action and may inhibit the breakdown of cortisol produced

by the body⁽³⁾. Licorice root have mild estrogen-like effect, making the herb potentially useful in certain symptoms of premenopausal tension syndrome, polycystic ovary syndrome and menopause by compensating for the decline in estrogen level^(4,5). In general, licorice root improve reproductive performance and improves sperm count as well as semen viscosity⁽⁶⁾. Additionally it could minimize the inflammation and irritation of the urethra which can be consequence of coitus⁽⁷⁾. Also it was noticed that the consumption of licorice, lead to a significant increase in sperm concentration and motility of oligoasthenozoospermic infertile men⁽⁸⁾.

Institute of Embryo Research & Infertility treatment / Al-Nahrain University.

Address Correspondence to: Dr. Basima Mohammed Al –Jiboori ,

E- mail: bat_aljanabi@yahoo.com

Received: 30th August 2009, Accepted: 28th April 2010.

Materials and Methods

Sixty mature female Swiss Webster mice (45-49 day age) were divided into two main groups: Experimental (G) and control (C) groups. Experimental G (30 animals) were treated with 1 gm/kg of body weight of licorice root extract (Food Industry Company, Iraq) immersed in 1 ml. of distilled water while the control C (30 animals) were given distilled water only. Then the two main groups subdivided into three equal subgroups (G1, G2, G3) where G1 were treated for 3 weeks before mating, G2 were treated for 3 weeks before mating and 3 weeks during pregnancy, and G3 were treated for 3 weeks during pregnancy, while (C1, C2, C3) were given distilled water only by the same volume and periods that used with experimental groups. The licorice extract was prepared by using 1000 gm of licorice in granular powder moistened with boiling water and percolated until the licorice exhausted. Then ammonia solution were added the percolate, filtrate and evaporate until black pillar mass having a characteristic sweet taste powder were prepared⁽⁹⁾. Chief component are glycyrrhetic acid, glycyflavone, salt, flavonoids, volatile oil, acetic acid⁽¹⁰⁾. Litter size for all experimental and control mothers were recorded. The newborn animals (male only) feed on normal diet, without licorice from both treated and control groups (180 mice) were also divided by the same way of division used with the mothers. After 40 days (around the puberty age), the animals were weighted again using an electrical balance (Sartorius, Germany), then sacrificed to get their testes. Each testis was weighted, then fixed in 10% normal saline and histological sections with thickness of 5 micrometer were prepared

using the routine histological technique and stained with Haematoxylin-eosin⁽¹¹⁾. Diameters of seminiferous tubules together with the thickness of their germinal wall were calculated by (ocular micrometer about a total of 25 cross sections of round shape seminiferous tubules randomly selected from each mouse for measuring their diameter a calibrated eye piece (x400) ocular micrometer in order to draw their mean value for individual mice. Data was analyzed using student t-test⁽¹²⁾.

Results

1-Effect of licorice extract on the litter size: highly significant increase ($P < 0.01$) in the numbers of pups born from treated mothers compared to that of control groups were recorded with slight non significant increase in their weights. No differences were revealed between the three experimental groups (Table 1).

2-Effect of licorice extracts on young males offspring:

A-Weights: males born from treated mothers (G1, G2, & G3) showed a significant increase in

Body weights ($P < 0.05$) and highly significant increase ($P < 0.01$) in their testes weights in

Comparison with that born from control groups mothers (C1, C2 & C3). (Table 2).

B-Histological study: A highly significant increase ($P < 0.01$) in the diameters of seminiferous tubules in the testes of all experimental males (G1, G2 & G3), was recorded with a well developed germinal epithelial lining. The measurement of the lining thickness was also showed a significant increase ($P < 0.05$), compared to that of control males C1, C2 & C3 (Table 2). Mature sperms with full formed head and tail appeared clearly free in the lumen of seminiferous tubules of the experimental

animals, while those belong to the control groups showed immature stages of spermiogenesis with pyramidal shape

and attached to the apex of Sertoli cells (Figure 1 and 2) .

Table 1: Effect of licorice extracts administration to pregnant females on the number and weights of their offspring.

	C1	G1	C2	G2	C3	G3
Body weights of Pups (g)	1.21 ± 0.010	1.23 ± 0.097	1.22 ± 0.0127	1.33 ± 0.016	1.03 ± 0.015	1.24 ± 0.012
Number of pups/pregnant	4.06 ±0.1	8.13** ±0.13	3.86 ±0.12	8.76** ±0.13	3.96 ±0.13	8.96** ±0.15

****:** highly significant increase ($P < 0.01$).

Table 2: Effect of licorice extract administration to pregnant mothers on the body weight, testis weight, thickness and diameters of seminiferous tubules of young males.

	C1	G1	C2	G2	C3	G3
Body weight of young male mice(g)	16.21 ± 0.04	19.58** ± 0.08	16.42 ± 0.07	19.75** ± 0.10	16.5 ±0.09	20.1** ± 0.12
Weight of testis (mg)	2.33 ± 0.259	4.0** ± 0.283	2.30 ± 0.209	4.608** ± 0.323	2.262 ± 0.293	3.914** ± 0.364
thickness of seminiferous tubules (µm)	1.7 ± 0.04	2.1* ± 0.01	1.7 ± 0.04	2.1* ± 0.01	1.7 ± 0.04	2.2* ± 0.03
diameters of seminiferous tubules (µm)	13.3 ± 0.16	15.9** ± 0.08	13.6 ± 0.06	16.2** ±0.14	13.8 ± 0.09	15.3** ±0.12

***:** significant changes ($P < 0.05$)

****:** highly significant changes ($P < 0.01$)

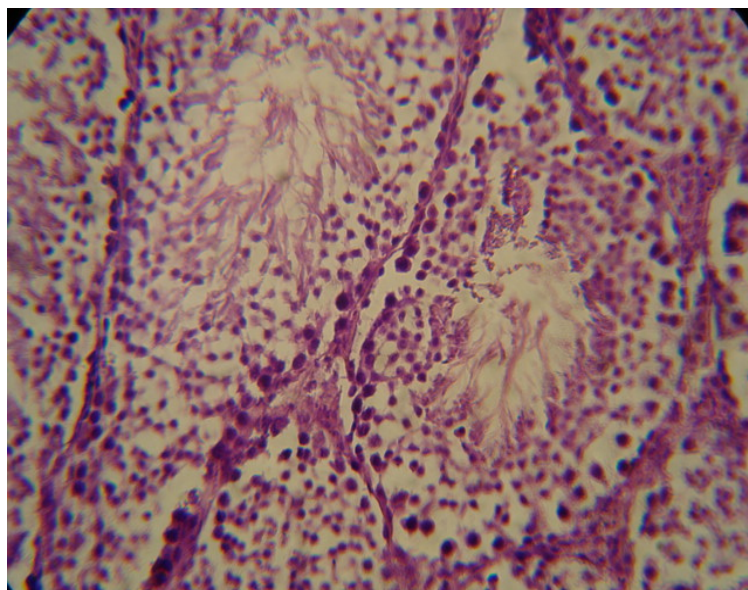


Figure 1 : Cross section in the testis of young male(40 days) mouse born from mother treated with licorice root extract (0.003 mg daily), showing the wide lumen of seminiferous tubules filled with mature sperm (arrows) and complete development of the lining epithelium.400 X

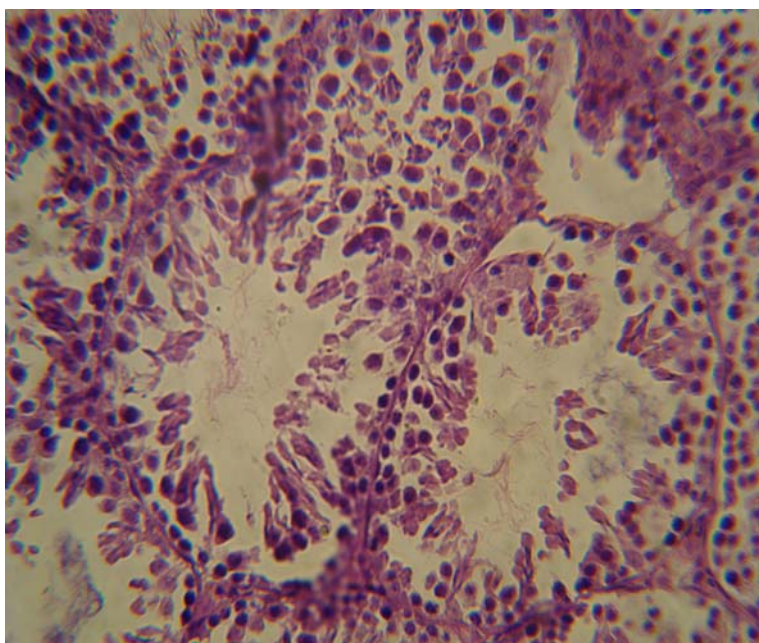


Figure 2: Cross section in the testis of young male mouse born from control group mother. Note the absence of mature sperm in the lumen of the somniferous tubules and the appearance of clumps of immature sperm connected to the germinal epithelium (arrows). 400X (H&E)

Discussion

The significant increase in the litter size of mothers consumed licorice extract recorded in this study, reflects an increase in ovulation rate and successful implantation for the fertilized ova, and this means consequently that a good amount of FSH and LH may be available, since these hormones are responsible for stimulation of follicular development and ovulation⁽¹³⁾. An increment in gonadotropic hormones may be correlated with the consumption of licorice extract, which is previously documented, through several studies, to have this stimulatory effect on these hormones⁽¹⁴⁻¹⁶⁾. On the other hand, the increase in number of births in all experimental groups may be attributed to the increase in implantation rate which depends mainly upon the presence of sufficient amount of estrogen and progesterone⁽¹⁷⁾, and since steroids is one of licorice constituents⁽⁵⁾, so it may provide an estrogenic atmosphere necessary for good implantation^(3, 18). An increment in the body weights of young males born from treated mothers agreed with that recorded in other study⁽¹⁶⁾, which may results from the biochemical properties of licorice in addition to its nutritional constituents such as: sugar, protein, amino acids, vitamins and sterols⁽¹⁹⁾. On the other hand, the significant increase in gonadal weights and the precocious maturation of semineferous tubules may be attributed to the possible activation of gonadotropin releasing hormone (GnRH) secretion by licorice, leading to activation of pituitary-gonadal axis which is temporarily active during the fetal/neonatal development and secondly reactivated at puberty⁽²⁰⁾, and this was reflected clearly by the positive results recorded in the experimental groups. In

addition, the activation of pituitary-gonadal axis during neonatal period, stimulate Sertoli cells proliferation leading consequently to rise their spermatogenic potential at adult period⁽²¹⁾, this was reflected by the thickness and maturation of the germinal epithelium of the semineferous tubules in the experimental groups compared to that of the control groups.

Consuming low dose of licorice root extract by pregnant females causes significant increase in litter size and weights with a precocious maturation of the male gonads.

References

1. Samy J, Sugumaran M and Lee K, Herbs of Malaysia (Ed.) K.M. Wong, Pub. Times Edition – Marshall Cavendish, 2005; Pp. 244.
2. Trease W and Evans C. Pharmacognosy – EIBS with Trindal, U.K. 1992; Pp. 459-498.
3. Soma R, Keda M and Mourisa T. Effect of Glycyrrhizin on cortisol metabolism in human. Endocri. Regulation, 1994; 28: 31-34.
4. Anonymous A. Treatment of menopause associated vasomotor symptoms: position statement of the North American menopause society. Menopause, 2004; 11(1):11-33
5. Zava DT, Dollbom g M. and Blen M. Estrogen and progestin bioactivity of foods herbs and species, Proc. Soc. Exp. Biol. Med., 1998; 217: 368-378.
6. Mahdi A K. Effect of licorice extract on reproductive performance of Awassi rams. M.Sc. thesis. Collage of Agriculture, University of Baghdad, 2000.
7. Kokate CK, et al Pharmacognasy, 2nd. Edition, Nirali Pakistan (Pune, India); 1994 , Pp.625-629,
8. Al-Ani H S. Effect of licorice on reproductive hormones, semen quality and certain biochemical aspects in infertile patients. A high diploma thesis. Institute of Embryo Research and Infertility Treatment, Al-Nahrain University, 2005.
9. PDR, for Herbal medicines Medical Economics' Company, New Jersey, 1998; Pp: 875-879.
10. Oblontseva GV. Pharmacological and

therapeutic properties of licorice preparation. *J. Pharma. Chemis.*33 (8):276

11. Bancroft JD and Steven A. Theory and practice of histological techniques. Churchill, Livingston, London, 2nd.ed.; 1982, Pp. 110-111,

12. Daniel WW. Multiple regression and correlation In: Biostatistics, A Foundation for Analysis in the Health Science, Daniel, W.W (Ed); 1998, Pp 98.

13. Costanzo LS. Reproductive Physiology. In: Text Book of Physiology, W.B. Saunders Company, Philadelphia.; 1998, Pp: 404

14. Luqman J. Al-Zangana. Effect of Glycyrrhiza on reproductive hormones and semen quality in infertile patients. High diploma thesis. Institute of Embryo Research and Infertility Treatment. Baghdad University. 2003

15. Al-Ani, A.A. Effect of licorice on ovulation and hormonal picture of amenorrhic women: High diploma thesis. Institute of Embryo Research and Infertility Treatment, Baghdad University. 2004.

16. Al-Muala I K. Effect of licorice extract (Glycyrrhiza glarra) on ovulation induction in immature female mice. High diploma thesis. Institute of Embryo Research and Infertility Treatment, Baghdad University.2006.

17. Guyton AC. and Hall JE. Text Book of Medical Physiology, Elsevier Saunders, Philadelpha, Pennsylvania.2006; Pp. 1017-1018.

18. Snait TM, Eizenberg D S, Nafto SR, Shelach AK, and Jacab NL. Estrogenic and Antiproliferative properties, 2000.

19. Francis S, Greenspan MD, David G, Gardner MD. Puberty. A Lange medical Book Basic and Clinical Endocrinology. 6th ed., 2001; Pp: 547.

20. Meachem SJ, McLachlan RI, deKroster DM, Robertson DM, and Wreford NG. Neonatal exposure of rats to recombinant follicle stimulating hormone increases adult Sertoli and spermatogenic cell numbers. *Biol. Reprod.* 1996; 54: 36-44.