

Renal and Myopathy Lesions of *Dirofilaria immitis* in Natural Infected Dogs

Enaam B Faleh¹ PhD, Amal H Attya² PhD, Abdul Baqi AA alkawaz³ MSc

¹Dept. of, College of Veterinary Medicine, University of Baghdad, ²Institute of Medical Technology, Baghdad, ³College of Dentistry, Al-Mustansiriya University.

Abstract

Background *Dirofilaria immitis* has been increasingly recognized worldwide as inadvertent human pathogens. The epidemiological survey usual hosts of these nematodes are domestic and wild carnivores. The disease is regarded as one of the most dangerous threat for the dog health. The adult worms take up residence in the heart, lungs and surrounding blood vessels.

Objective This study attempts to shed the light on relationship between glomerular lesions and heart filarial (*Dirofilaria immitis*) infection.

Methods *Dirofilaria immitis* was isolated from 98 dogs out of 457 dogs that were autopsied for the time between April 2008 and May 2010, in Al-Hindya area, Karbala province. Parameters concerning parasitological and pathological changes are used in this study to determine the significance of the results.

Results Grossly many adult heartworms were found in the right ventricle of infected hearts and the cross section revealed body cavity, thick cuticle with coelomyarian and polymyarin muscle type, accompanied by infiltration of inflammatory cells mainly eosinophils and lymphocytes between muscle fibers. The microscopical changes in the kidney were necrotic and sloughing of epithelial cells, cystic dilation of collecting tubules of medulla containing hyaline casts, with glomeruli showing membranous nephropathy.

Conclusions This is the first histological report of canine filariasis in Iraq particularly in Karbala province. It is important to keep in mind that pathologic changes in heartworm disease may be well advanced before the appearance of clinical signs of the disease. In heartworm disease the circulatory system is not the only system affected. The renal, hepatic & pulmonary systems can be secondarily affected. In our work the observations support the previous hypotheses of immature and possibly adult worms, contribute to the glomerulonephropathy.

Key words Canine heartworm, interstitial nephritis, membranous nephropathy.

Introduction

Dirofilaria immitis is a filarial nematode whose primary host is the dog. It is known as canine heartworm, can infect humans and cause a pulmonary lesion (human pulmonary dirofilariasis) that can easily be mistaken for a malignant tumor on imaging studies ⁽¹⁾. The larvae injected by infected mosquito into the

skin migrate through the muscles to the pulmonary blood vessels reaching the pulmonary arteries, where they continue to mature. Adult worms are found primarily in the pulmonary arteries, right side of the heart and in severe infections adult worm was found in the abdominal cavity of the dog during spaying ⁽²⁾.

Chronic dirofilaria disease results from progressive proliferative endarteritis and thromboembolism of the pulmonary artery caused mostly by adult worms and not by juvenile migrating worms⁽³⁾.

Histopathologically studies strongly suggest that filariasis may be of importance in relation with canine interstitial nephritis (IN)⁽⁴⁾. Some severely infected interstitial nephritis cases were shown to have necrosis with hemosiderin deposition and tubular degeneration also might be related with heart filariasis⁽⁵⁾.

The most glomerular and interstitial lesions are usually observed in dogs with high microfilaria counts and long infection periods due to prolonged release of antigenic material into the blood stream by inducing in situ formation or trapping of performed complex⁽⁶⁾. Microscopical evaluation of kidney revealed a diffuse hypercellularity and thickening of glomerular basement membrane. While transmission electron microscopy revealed deposits in the mesangium, subendothelium and sub-epithelium. These lesions are compatible with membranoproliferative glomerulonephritis type III in humans⁽⁸⁾.

Due to concern over the potential public safety and health risk, the present work carried out to describe the nephropathy of dirofilariasis in natural infected dog; also give the general histological description of the parasite. To the author's knowledge this is the first histopathological study of heartworm in dogs in Iraq particularly in Al-Hindya part of Karbala province.

Methods

From April 2008 to May 2010, four hundred and fifty seven stray dogs were shot by an authorized policeman and investigation for the presence of heart worms (*D. immitis*). These dogs were from different village of Al-Hindya area, Karbala province. No attempt was made to select these dogs on the basis of sex, breed, color, or type of

coat. Approximately 5 ml of blood was drawn from the femoral vein and direct from the heart of each dog, were tested by the Knott method⁽⁹⁾ for the presence of microfilaria (larval stage) of the parasite. After shooting of these dogs, they were brought to the veterinary clinic in the province for the purpose of conducting postmortem and further investigations. Each organ like liver, spleen, lung, heart, and kidney were carefully examined. Tissue samples from kidney were fixed in 10% formalin. Paraffin sections were made by a routine procedure and stained with Hematoxylin and Eosin⁽¹⁰⁾. *D. immitis* found in the right ventricle and pulmonary arteries were removed from 98 natural infected dogs (Figure 1).

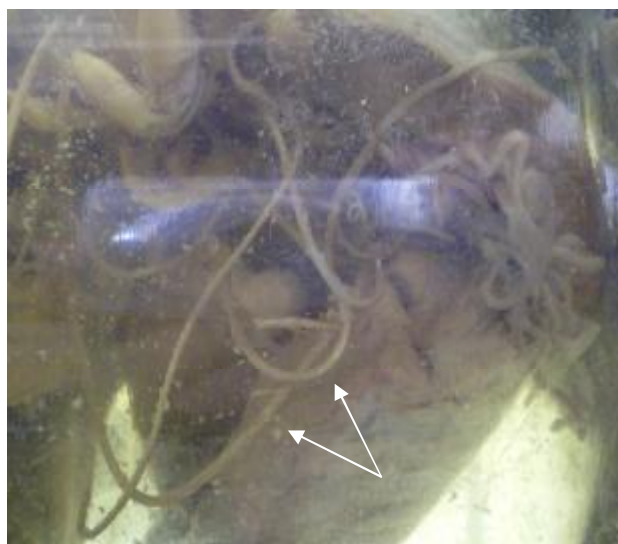

Figure 1. Canine filariasis: Many adult *D. immitis* in the heart of a dog

Result

Light microscopic study of kidney section showed several lesions of varying degrees of severity. The histopathological finding in cross-section of parasite showed presence of body cavity thick cuticle and coelomyarian and polymyarin muscle type with intestine tract (Figure 2). While the myocardial findings revealed infiltration of inflammatory cells mainly eosinophils and

lymphocytes between degenerated muscle fibers (Figures 3 and 4), with fragmentation and separation of some muscle bundle by intramuscular edema (Figure 5) as well as present of PMNCs in the lumen of some blood vessels.

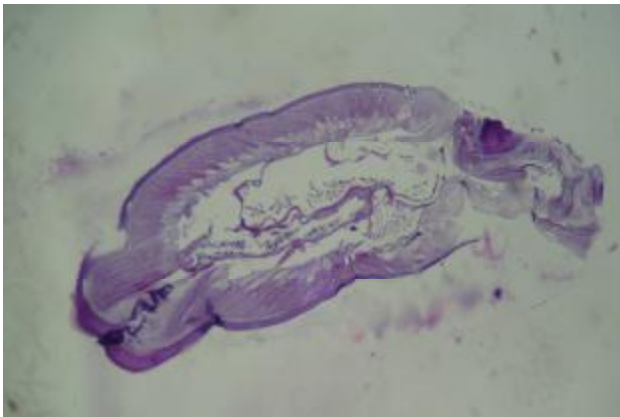

Figure 2. Cross section of *D. immitis* shows thick cuticle, coelomyarian and polymyarian muscle. H & E. (10X)

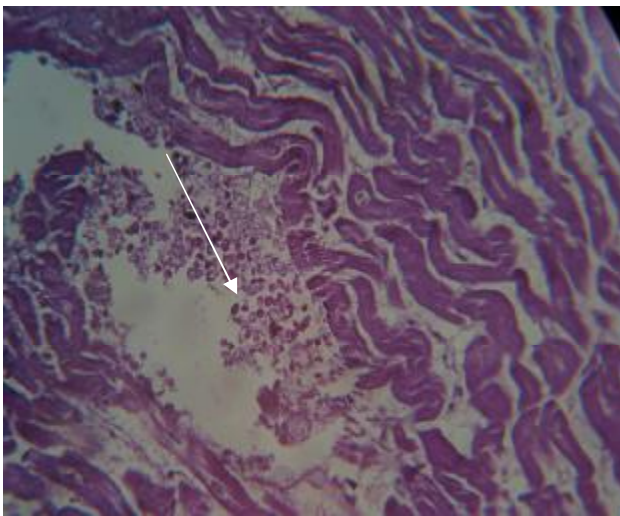


Figure 3. Heart muscle of infected dog shows mild infiltration of eosinophils between muscle fibers. H & E (10x)

Some glomeruli were collapsed associated with atrophy of tuft and dilatation of urinary space (Figure 6) with periglomerular fibrosis. Some glomeruli showed features with membranous nephropathy characterized by diffuse thickening

of the basement membrane; also the change is diffuse affecting all capillaries in glomerular tuft (Figure 7).

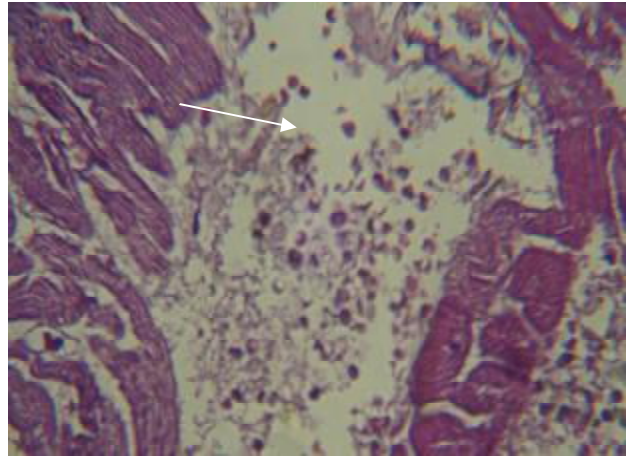


Figure 4. Heart muscle of infected dog shows infiltration of interstitial with MNCs inflammatory edema. H&E 20x

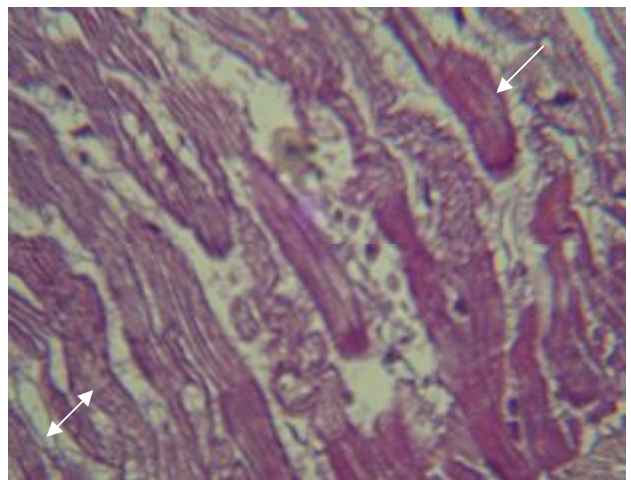


Figure 5. Heart muscle of infected dog shows the hyalinized degenerated muscle fiber (↙) and separated by cellular infiltration and cellular edema (↔). H & E (20X)

The epithelial lining of proximal and distal convoluted tubules showed varies degree degenerative changes range from mild to severe. Some of the tubules were necrotic with sloughing of their epithelial lining cells (Figure 8).

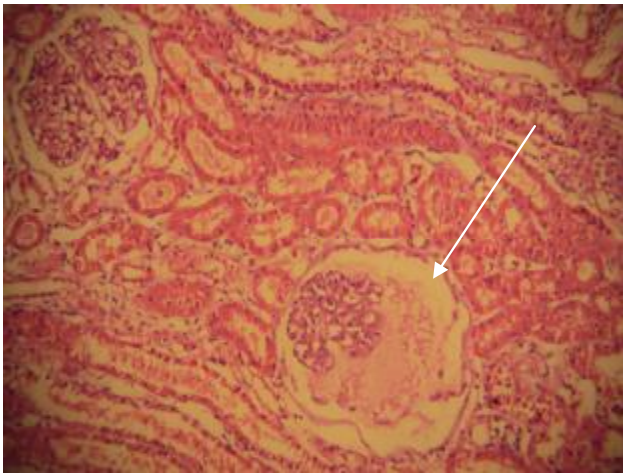


Figure 6. Kidney of infected dog shows one glomerular collapsed with atrophy of tuft, dilatation of urinary space & hyper-cellular of the other one. H&E (10x).

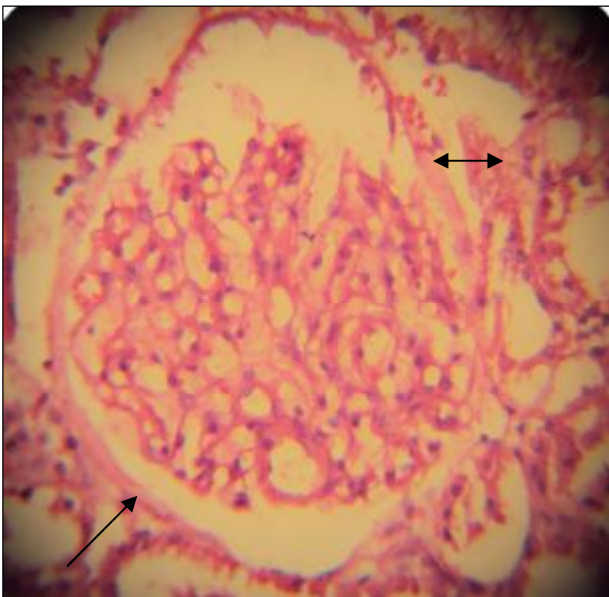


Figure 7. Kidney of infected dog shows diffuse thickening of the basement membrane (\longleftrightarrow) and capillaries of glomerular tuft (\swarrow). H&E (40x).

Cystic dilatation of collecting tubules of medulla containing hyaline casts in the lumen were observed (Figure 9). There was focal infiltration of lymphocyte and plasma cells in the interstitial

tissue (Figures 10a and 10b) accompanied with fibrous thickening of renal capsule (Figure 11).

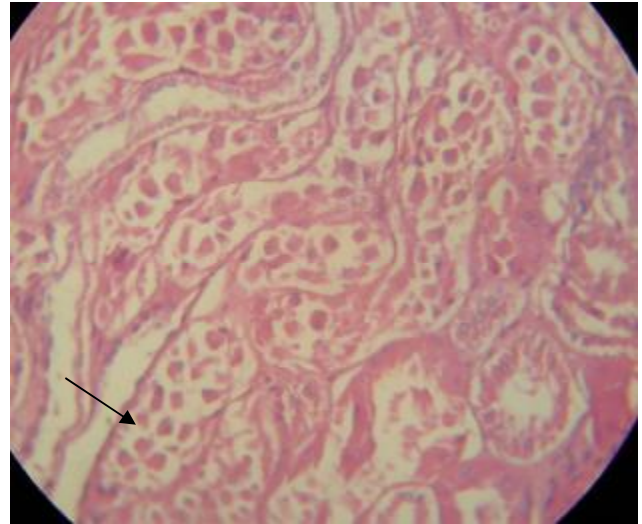


Figure 8. Kidney of infected dog shows most of epithelial lining the tubules has died & sloughed into the lumen. H&E (10x).

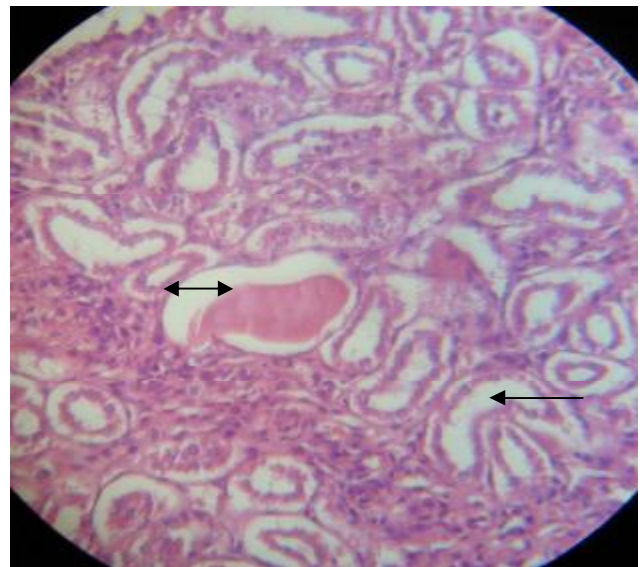


Figure 9. Kidney of infected dog shows cystic dilatation of collecting tubules (\longleftarrow) of medulla containing hyaline casts (\longleftrightarrow). H & E 20x

The blood vessels were congested and thickened (Figures 12 and 13) with perivascular lymphocytic cuffing. In addition, some sections

of interstitial reaction have various degrees of fibrosis.

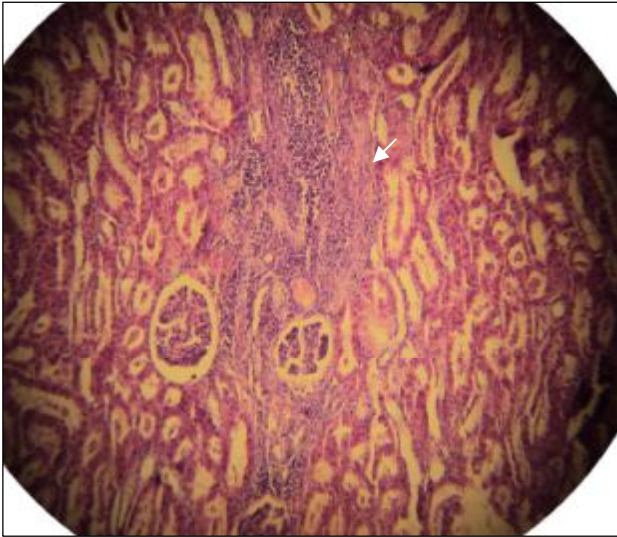


Figure (10a) kidney of infected dog shows focal infiltration of lymphocyte and plasma cells with tubular dilatation. H & E. 10x

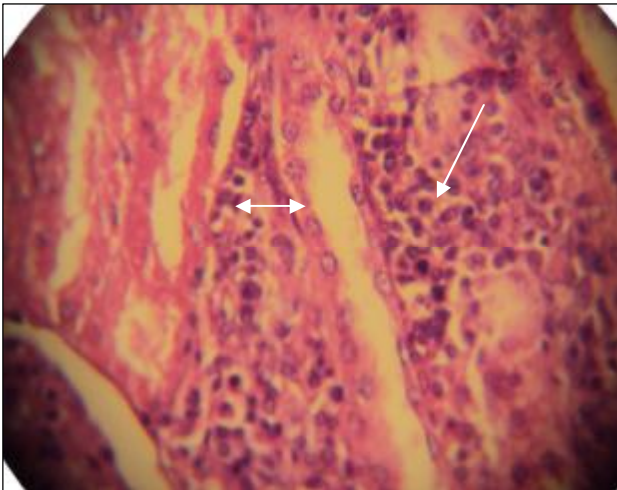


Figure 10b. Kidney of infected dog shows infiltration of lymphocyte and plasma cells in the interstitial tissue (↙) with cystic tubular dilatation (↔). H&E10x

Discussion

In the present study canine filariosis was detected for the first time in Al-Hindya part,

Karbala province, Iraq. Its prevalence and epidemiological aspects of *D. immitis* in dogs were mentioned in previous reported ⁽¹¹⁾.

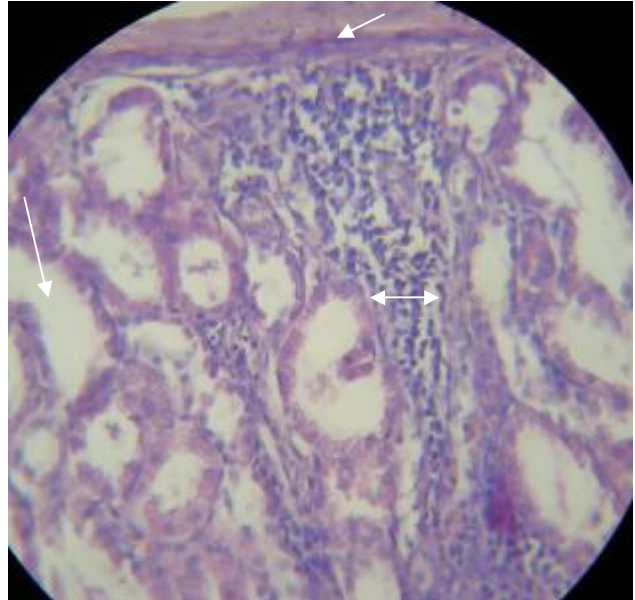


Figure 11. Kidney of infected dog shows fibrous thickening of renal capsule (↙) with focal, sub cortical infiltration of lymphocyte and plasma cells (↔) and cystic tubular dilatation (↘). H & E 20x

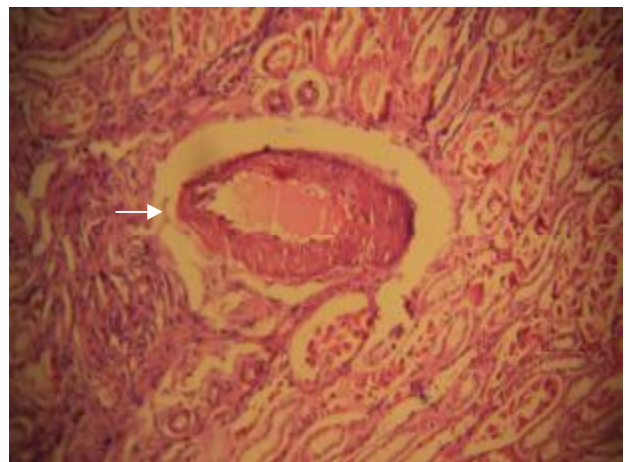


Figure 12. Kidney of infected dog shows thickened blood vessel with congestion. H & E. 10x

The Severity of pathology of heartworm in dogs is determined by worm numbers, duration of

infection, host activity level, and induction of host immune response in the lungs and kidneys (immune complex glomerulonephritis) ⁽¹²⁾.

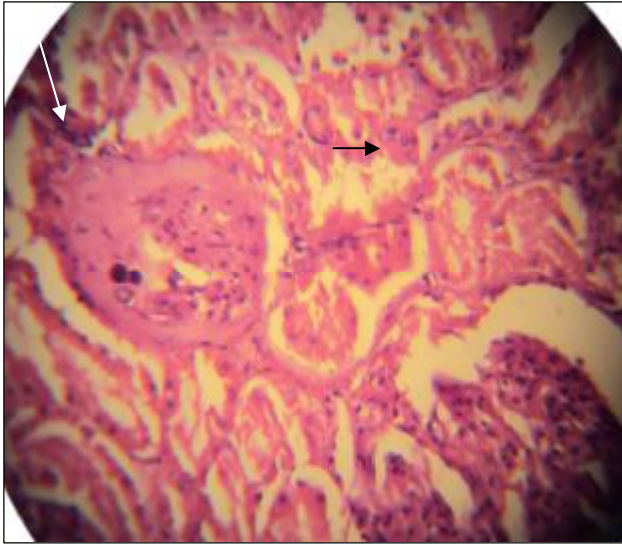


Figure 13. Kidney of infected dog shows severe tubular swelling (→) and the wall of small artery is fibrosed with luminal reduction (↙). H&E 20X

In the present study it was observed that muscle layer of the polymyarian and coelomyarian muscle type was well developed, particularly at the level of the lateral cords as described in ^(13,14).

Our results were in agreement with the results of ⁽¹⁵⁾ who found that some sections of the helminthes were surrounded by a cellular reaction inside the vessel, while others were free in the lumen of the artery.

In this study the histological examination of renal biopsy specimens revealed that the lesions were seemed difficult to consider that glomerular lesions resulted from only the primary interstitial affection in focal lesion type as well as diffusely, these results agree with the results of ⁽¹⁶⁾. Feride et al in 2007 who observed interstitial nephritis in the kidneys and thickening of the glomerular capillaries in the glomerulus, and this observation agreed with our data.

In this study the grades of interstitial mononuclear infiltration and fibrosis varied between individual cases. This is attributable to either stages of the disease at autopsy or difference in pathogenesis ⁽⁴⁾.

Monlux (1953) Described focal mononuclear cell infiltration in the inner medulla of the kidney in filarial- infected dogs. To the present work we found infiltration of inflammatory cells mainly eosinophils and lymphocytes between degenerated muscle fibers, also Grauer (1987) and Naruse (1976) reported a general leukocytosis was seen in dogs with *D. immitis*, and they added that, although eosinophilia and neutrophilia could be seen, the percent of distribution of leukocyte showed individual differences.

Tubular changes in some severely infected cases also might be related with heart filariasis ⁽²⁰⁾. However, the result of the present study revealed that canine interstitial nephritis cases without any glomerular changes were about 22.5% and that most interstitial lesions were associated with glomerular changes as previously described by ^(21,22). Also the thickening of the glomerular basement membrane has occurred independently ⁽¹²⁾ and this observation agreed with our data.

The pathogenesis of glomerulonephritis due to *D. immitis* has been widely discussed and considered to be the most frequent type of membranoproliferative glomerulonephritis in dogs ^(23,24). The most sever lesions are usually observed in dogs with high Mf counts and long infection periods due to prolonged release of antigenic material into the blood stream by inducing in situ formation or trapping of performed complexes ⁽²⁵⁾.

Abramowsky et al (1981) Considered glomerular lesions are another complication of filariasis. Another fact is that the observed lesions in this study may represent a natural form of an immunopathogenic mechanism of glomerular damage in which filarial antigen becomes

uniformly localized in the glomerulus and elicits an autologous antibody response.

References

1. Theis JH. Public health aspects of dirofilariasis in the United States. *Vet Parasitol*, 2005; 133(2-3): 157-180.
2. Oh HW, Jun HK, You MJ, Hayasaki M, Song KH. Ectopic migration of an adult heartworm in a dog with dirofilariasis. *Korean J Parasitol*, 2008; 46(3): 171-173.
3. Ferasin L. Disease risks for the traveling Pet: Heartworm disease. In Practice. 2004; 26: 350-357.
4. Shirota K, Takahashi R F, Jiwarak K, and Hasegawa A. Canine interstitial nephritis with special reference to glomerular lesions and Filariasis. *Jap J Vet Sci*, 1979; 41(2): 119-129.
5. Monlux AW. The histopathology of nephritis of the dog. I. Introduction. II. Inflammatory interstitial disease. *Am J Vet Res*, 1953; 14(52): 425-439.
6. Song KH, Hayasaki M, Choliq C. Immunological responses of dogs experimentally infected with *Dirofilaria immitis*. *J Vet Sci*, 2000; 3(2): 109-114.
7. Kamii J, Shirota K, Yamaki M, Kitagawa H, Wasaki M, and Ooi HK. Abnormal distribution of anionic sites in the glomerular basement membrane in glomerulonephritis of dogs infected with *Dirofilaria immitis*. *J Vet Med Sci*, 2000 Nov; 62(11): 1193-5.
8. Luca A, Federico V, Ezio F, Paola P, Federica U, Alberto T, Renato Z. membranoproliferative glomerulonephritis type III in a simultaneous infection of *Leishmania infantum* and *Dirofilaria immitis* in a dog. *J Vet Diag Invest*, 2007; 19(5): 569-572.
9. Knott J. A method for making microfilaria surveys on day blood. *Tans R Soc Trop Med Hyg*, 1939; 33: 191-196.
10. Bancroft FJ, Stevens A. Theory and Practice of histological techniques. 2nd (eds.), Churchill Livingstone. 1982; p. 338-439.
11. Amall HA. Seroepidemiological study of heartworm *Dirofilaria immitis* in Baghdad and Karbala provinces. PhD Thesis, College of Veterinary Medicine, University of Baghdad, 2010; p. 55-107.
12. Merck veterinary manual. Heartworm disease: Urine sediment. (2008). www.merckvetmanual.com.
13. Paes-de-Almeida EC, Ferreira AM, Labarthe NV, Caldas ML, McCall JW. Kidney ultrastructural lesion in dogs experimentally infected with *Dirofilaria immitis* (Leidy, 1856). *Vet Parasitol*, 2003; 113(2): 157-168.
14. Kim MK, Kim CH, Yeom BW, Park SH, Choi SY, Choi JS. The first human case of hepatic Dirofilariasis. *J Korean Med Sci*, 2002; 17: 686-690.
15. Amid A. Zoonotic subcutaneous Dirofilariasis in Iran. *Arch Iranian Med*, 2003; 6(1): 63-65.
16. Theis JH, Arlette G, Gerald ES, Barton B, and Daniel C. Unusual location of *Dirofilaria immitis* in a 28-year-old man necessitates orchiectomy. *Am J Trop Med Hyg*, 2001; 64(5, 6): 317-322.
17. Feride KS, Esmā K, Aziz B, Fatih MB, Mustafa K, Aler S. *Dirofilaria immitis* infection in dogs: unusually located and unusual findings. *Parasitol Res*, 2007 Nov; 101(6): 1487-94.
18. Grauer GF, Culham CA, Cooley AJ, Poff BC, Oberley TD, Brownfield MS, Greive RB. Clinicopathology and histologic evaluation of *Dirofilaria immitis* induced nephropathy in dogs. *Am J Trop Med Hyg*, 1987 Nov; 37(3): 588-96.
19. Naruse T, Fukasawa T, Hirokawa N, Oike S, Miyakawa Y. The pathogenesis of experimental Membranous glomerulonephritis induced with homologous nephritogenic tubular antigen. *J Exp Med*, 1976 Nov 2; 144(5): 1347-62.
20. Hass M. Incidental healed post infectious glomerulonephritis: a study of 101 renal biopsy specimens examined by electron microscopy. *Hum Pathol*, 2003; 34(1): 3-10.
21. Niwetpathomwat A, Kaewthamasorn M, Tiawsirisup S, Techangamsuwan S, and Suvarnvibhaja S. A retrospective study of the clinical hematology and the serum biochemistry test made on canine Dirofilariasis cases in an animal hospital population in Bangkok, Thailand. *Res Vet Sci*, 2007; 82(3): 364-369.
22. Casey HW, Splitter GA. Membranous glomerulonephritis in dogs infected with *Dirofilaria immitis*. *Vet Path*, 1975; 12(2): 111-117.
23. Lewis RJ. Canine glomerulonephritis: Result from a microscopic evaluation of fifty cases. *Vet J*, 1976; 17(7): 171-176.
24. Muller-Peddinghaus R, Trautwein G. Spontaneous glomerulonephritis in dogs. II. Correlation of glomerulonephritis with age, chronic interstitial nephritis and extrarenal lesions. *Vet Path*, 1977; 14(2): 121-127.
25. Nakagaki K, Hayasaki M, and Ohishi I. Histopathological and immunopathological evaluation of filarial glomerulonephritis. *Jap J Exp Med*, 1990; 60(4): 179-186.
26. Abramowsky CR, Powers KG, Aikawa M, Swinehart G. *Dirofilaria immitis*. immunopathology of filarial nephropathy in dogs. *Am J Pathol*, 1981; 104(1): 1-12.

Correspondence to: Dr. AK alkawaz

E-mail: ak_alkawaz@yahoo.com

Received 30th Jan. 2011; Accepted 14th Jun. 2011