

Early Presentation of Bilateral Morgagni Hernia in an Infant Case Report

Ahmed Z Zain *MBChB FIBMS*

Dept. of Surgery, College of Medicine, Al-Nahrain University

Abstract

In this report, a rare case of bilateral Morgagni hernia is enlightened in a 7-month old infant weighing 6.5 kg, presented with shortness of breath and fever for 5 days duration. There was a history of the same attack at 2 and 5 months of age and treated as a chest infection. He was admitted to pediatrics emergency unit for investigations and treatment. Plain chest radiography revealed retrosternal bowel herniation and Barrium-enema revealed bilateral big Morgagni hernia. Reduction of herniated contents (transverse colon and omentum) done with repairing of bilateral big Morgagni hernia through transabdominal approach. This case is a very rare and interesting one, because of an early bilateral presentation, and the fact that it occurred in a male infant.

Introduction

The majority of congenital diaphragmatic hernias occur through the left posterlateral foramen of Bochdaleck and commonly these patients are symptomatic. Hernia through the foramen of Morgagni, on the other hand, is rare in children, representing 1-6 % of all types of congenital diaphragmatic hernia. It is usually asymptomatic and discovered accidentally, or if symptomatic it produces variable nonspecific symptoms which include respiratory or vague gastrointestinal symptoms, and because of this the diagnosis is usually delayed⁽¹⁻³⁾.

Morgagni hernia is the rarest type of congenital diaphragmatic hernia. Most of the patients are females and 92% of the hernias have a hernial sac. The majority of Morgagni hernias are right-sided with rare only left sided and bilateral occurrence because of the protection provided by the pericardial sac^(4,5). The rarity of Congenital Morgagni hernia as

well as the vagueness, variability and non-specificity of symptoms lead to the delayed diagnosis. In the majority of those with bilateral Congenital Morgagni hernia, the diagnosis of bilaterality is made intraoperatively^(6,7). This report describes the diagnosis and repair of a big, bilateral Morgagni hernia.

Case Report

A seven-month-old male infant weighing 6.5 kg was presented to the emergency room with severe dyspnea, cough and fever for five days duration. There was no history of trauma but previous twice hospital admissions due to chest infection. Physical examination revealed stable vital signs. Auscultation of the chest revealed no audible breath sounds in the bilateral lower sites of the chest. The laboratory results were in normal limits. Electrocardiogram was normal and echocardiogram measured normal cardiac chamber, volumes and ejection fraction. He had no gastrointestinal symptoms.

Posteroanterior chest radiography showed presence of air-filled loops of bowel retrosternally. Barrium (Ba)-enema showed presence of loops of colon on both retrosternal regions (Figure 1-A). The patient was diagnosed as bilateral Morgagni hernia. He was admitted to the pediatric ward for medical treatment of his chest infection and stayed for one week until he became stable and then transferred to the pediatric surgical ward for surgical interference which was done as an emergency through trans-abdominal approach. Two

hernial openings were identified on both sides of sternum and reduction of transverse colon and omentum was done with excision of two hernial sacs (Figure 2). After reduction of the herniated contents into the peritoneal cavity, primary repair of the diaphragmatic defects was performed with nonabsorbable silk mattress sutures. The patient made an uneventful recovery. He was discharged on the 7th day postoperatively, and was well after six month follow-up.

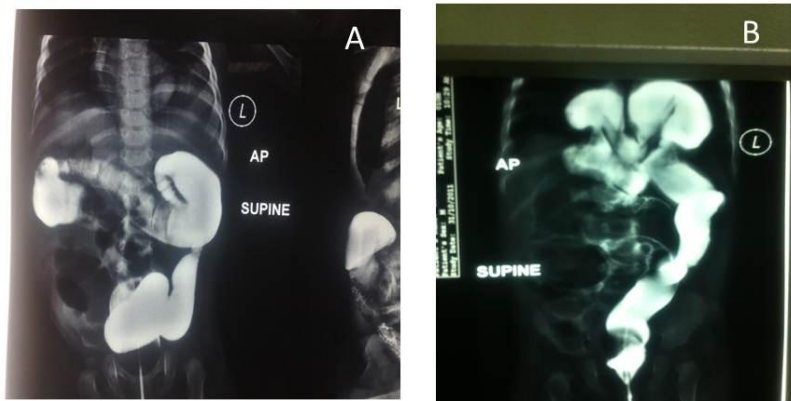


Figure 1. A Ba-enema showing bilateral Morgagni hernia at time of admission. **B** Ba-enema two months postoperatively

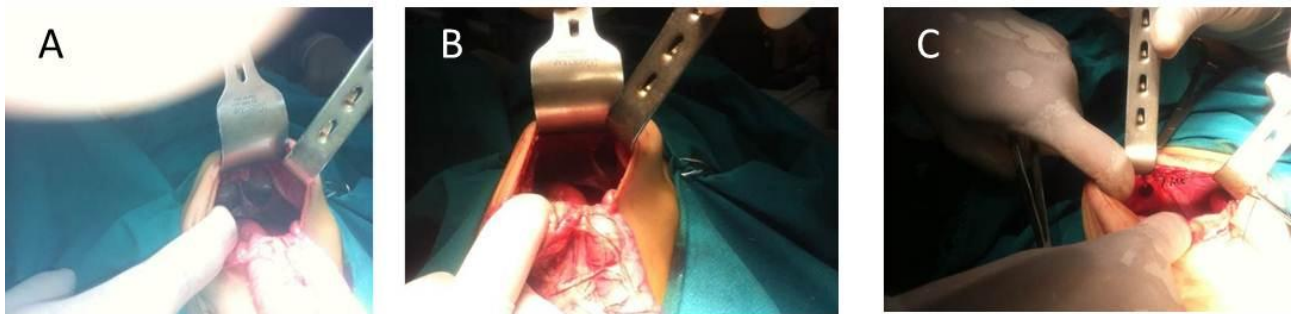

Figure 2. A & B Intraoperative bilateral Morgagni hernia, **C** Repair of Morgagni hernia

Discussion

Anatomically, the foramen of Morgagni is a small anterior retro-sternal defect extending from the sternum medially to the eight costal cartilages laterally. Berman *et al*⁽³⁾ in 1989 had reported only 18 cases of Morgagni hernia over a 40-year period from a large tertiary hospital, but no bilateral Morgagni hernia was reported in this study, and all of

those cases were diagnosed after the age of ten years. However, this reported case was diagnosed in infancy and was bilateral which is very rare. Pokornay *et al*⁽⁸⁾, in a series of 74 patients with congenital diaphragmatic hernia had found only 4 (5.4%) with Morgagni hernia with only one bilateral Morgagni hernia was diagnosed at 15 years of age.

Most of the Morgagni hernia has a hernial sac. Hernial sac frequently contains the omentum, transverse colon and rarely stomach or liver⁽⁵⁾. The present case had hernial sac that contained omentum and transverse colon. Patients with Morgagni hernia are usually asymptomatic. Among symptomatic patients; the complaints included shortness of breath, thoracic pain, nausea, vomiting, abdominal distension, and abdominal pain. The present case presented with shortness of breath, cough and fever (chest infection). The use of computed thoracoabdominal tomography as a diagnostic tool for Morgagni hernia has increased the reliability of preoperative diagnosis. Bilateral, big Morgagni hernia of the present case was diagnosed with chest radiography and Ba-enema without the need for CT scan. The treatment of Morgagni hernia is surgical and is indicated always after diagnosis because of the risk of visceral complications such as obstruction or strangulation.

Both transabdominal and transthoracic approaches are recommended in surgical repair of Morgagni hernia. Transthoracic repair has been used by Kilic *et al*⁽⁹⁾ with favorable results. They recommended transthoracic approach because it provides sufficient exposure, easy repair of the hernial defect and facilitates the release of pericardial adhesions. But, they also reported that transabdominal approach should be favored, particularly in cases with bilateral hernial sac as in our patient. Transabdominal approach via laparotomy is superior in recognition and management of malrotation and for dealing with visceral complications than transthoracic approach. The present case was treated with an elective laparotomy and there were no postoperative complications. In conclusion, Morgagni hernia is a rare surgical problem. Bilateral Morgagni hernia is extremely rare and patient usually asymptomatic and discovered incidentally. Preoperative diagnosis may be aided by chest radiography and Ba-enema as in our current case and in questionable cases by

CT scans. The current treatment of a Morgagni hernia is surgical repair (open or laproscopically) because of the risk of visceral herniation and strangulation. Transabdominal approach is the preferred technique for reduction and dealing with visceral complications. The laparoscopic approach has the advantage that tissue trauma is kept to a minimum compared with the traditional open approach. The laparoscopic techniques have included a direct suture technique where the diaphragm is sutured to the retrosternal tissues using a Keith needle or inclusion of the whole of the upper abdominal wall in the repair with extracorporeal knots⁽¹⁰⁾.

References

1. Simson JNL, Eckstein HB. Congenital diaphragmatic hernia: a 20 year experience. *Br J Surg.* 1995; 72: 733-6.
2. Cullen ML, Klein MD, Philippart AI. Congenital diaphragmatic hernia. *Surg Clin North Am.* 1985; 65: 1135-8.
3. Berman L, Stringer D, Ein SH, et al. The late presenting pediatric Morgagni hernia: a benign condition. *J Pediatr Surg.* 2000; 24: 970-2.
4. Comer TP, Clagett OT. Surgical treatment of hernia of the foramen of Morgagni. *Thoracic Cardiovascular Surg.* 1996; 52: 461-8.
5. Eren S, Crisis F. Diaphragmatic hernia: diagnostic approach with review of literature. *Eur J Radiol.* 2005; 54: 448-59.
6. Al-Salem AH. Congenital hernia of Morgagni in infants and children. *J Pediatr Surg.* 2007; 42: 1539-43.
7. Al-Salem AH, Nawaz A, Matta H, Jacobsz A. Herniation through the foramen of Morgagni: early diagnosis and treatment. *Pediatr Surg Inter.* 2002; 18: 93-7.
8. Pokornay WJ, McGill CW, Heberg FJ. Morgagni hernia during infancy: a presentation and associated anomalies. *J Pediatr Surg.* 1984; 19: 394-7.
9. Kiliç D, Nadir A, Döner E, et al. Transthoracic approach in surgical management of Morgagni hernia. *Eur J Cardiothoracic Surg.* 2001; 20: 1016-19.
10. Van der Zee DC, Bax NM. Laparoscopic repair of congenital diaphragmatic hernia in a 6 month old child. *Surg Endosc.* 1995; 9: 101-3.

E-mail: ahmedzbar@yahoo.com

Mobile: +964 7905234569

Received 13th Dec. 2011: accepted 18th Apr. 2012