

Protective Role of Vitamin E and/or Methionine against Lead-Induce Changes on Hematological Parameters in Rabbits

Majeda AJ Alqayim *PhD*, Sadat A Asis *MSc*

Dept. of Physiology and Pharmacology, College of Veterinary Medicine, Baghdad University

Abstract

- Background** The importance of lead as a toxic metal and environmental pollutant has long been recognized to human and animal health. In Iraq, lead pollution was documented in Baghdad and in Sulaimaniya city.
- Objective** To explore the protective role of vitamin E alone or in combination with the amino acid methionine against lead acetate side effects on hematological parameters of adult male rabbits.
- Methods** Thirty male adult rabbits were divided equally into five groups four of them administered lead acetate for 90 days, as sub-chronic exposure, and the fifth was considered as control. Three of these groups were treated with Vitamin E and/or methionine for 90 days. At the end of experiment, blood and liver samples were collected for either hematological analysis or histopathological examination.
- Results** Lead caused a significant decrease in lymphocytes and erythrocyte indices; and a significant increase in reticulocytes and neutrophils. At the same time, Vit. E, alone or mixed with methionine, corrected these values to semi normal values.
- Conclusion** Decreased erythrocyte indices and reticulocytosis that is found in the present study, demonstrates regenerative anemia in rabbits that had administered lead acetate. Vitamin E, alone or mixed with methionine, was efficient in reducing the side effects of Lead on hematological parameters; while, methionine had little or no effect when administered alone against lead which may be attributed to the dose or duration of the treatment.
- Keywords** Lead; vitamin E; methionine; hematological changes

Introduction

The importance of lead as a toxic metal and environmental pollutant has long been recognized to human and animal health^(1,2) in Iraq as well as other parts of the world. Lead pollution was documented, particularly in Baghdad⁽³⁾.

The mechanism by which lead affects the human body is extremely complex. On an atomic level, lead can induce a wide range of adverse effects in humans depending on the dose and duration of exposure^(4,5). Lead induces the production of reactive oxygen species (ROS) that result in lipid

peroxidation, DNA damage, and depletion of cell antioxidant defense systems⁽⁶⁾. The toxic lead effects on the hematologic system^(5,7), thus, cause a slowly developing hypochromic normocytic or microcytic anemia⁽⁸⁾.

Vitamin E is naturally occurring antioxidants that play important roles in health by inactivating harmful free radicals produced through normal cellular activity and from various stressors⁽⁹⁾. The protective mechanism of vitamin E against lead toxicity could be attributed to its antioxidant property or its location in the cell membrane and its ability to stabilize membrane

by interacting with unsaturated fatty acid chain (10-13).

The essential amino acid methionine shows antioxidant properties in various models of oxidative stress (14). The mechanisms responsible for the observed methionine-induced cytoprotection are not yet fully understood. The free radical scavenging activities of methionine can only partially be explained by the chelating function of its sulfur moiety (15). There has been increased interest among researchers to use antioxidant nutrients and medicinal plants with antioxidant activity for protection against lead toxicity (16).

In an effort to decrease the severity of lead exposure side effects on hematological parameters, the present study was designed to explore the protective role of vitamin E alone or in combination with the amino acid methionine against lead acetate side effects on hematological parameters of adult male rabbit for 90 days, as sub chronic exposure.

Methods

Experimental design:

Thirty adult male rabbits of local breed were divided randomly into equal five groups, each group of six animals treated as follow: **Group 1:** Control group that were orally administered with tap water daily. **Group 2:** Orally administered with 2.5 mg/Kg B.W. lead acetate (250 mg/100 ml) dissolved in tap water daily. **Group 3:** Orally administered with 2.5 mg/Kg B.W. lead acetate (250 mg/100 ml) dissolved in tap water + 100 mg/Kg B.W. methionine dissolved in 2 ml of tap water daily. **Group 4:** Orally administered with 2.5 mg/Kg B.W. lead acetate (250 mg/100 ml) dissolved in tap water + 100 IU/Kg B.W. vitamin E daily. **Group 5:** Orally administered with 2.5 mg/Kg B.W. lead acetate (250 mg/100 ml) dissolved in tap water + 100 IU/Kg B.W. vitamin E + 100 mg/Kg B.W. methionine dissolved in 2 ml of tap water daily. The experiment lasts for 90 days, meanwhile, animals were observed daily for their behavior and health performance. At the end of the experiment all the experimental animals were

sacrificed and 6-8 ml of blood samples was collected into EDTA tube for immediate hematological measurements and reticulocytes count.

Hematological and biochemical changes:

Total red blood cells (RBC) count, hemoglobin (Hb) concentration, packed cell volume % (PCV), mean corpuscular volume (MCV), mean corpuscular hemoglobin (MCH), mean corpuscular hemoglobin content (MCHC), Platelet count, total and differential WBC as well as lymphocyte and neutrophil count were accomplished by using hematological analyzer (Hycel Hematology analyzer, version B, ver2.5x.) at Damawand general laboratory for processing in both hematology and biochemistry/ Sulaimaniya city. Reticulocytes were counted in 1000 cells of the total RBCs and expressed as percentage.

Serum iron: Serum iron concentration was enzymatically measured using enzymatic assay kit (Biolabo SA, Maizy-France).

Serum Ferritin: was measured by Ferritin enzyme immunoassay test Kit (Linear chemicals, Barcelona-Spain) using DANA 3200 ELISA Reader.

Histopathological changes:

Liver tissues preserved in 10% neutral formalin buffer solution. After fixation, the tissue was trimmed and the specimens were washed with saline for (1-2 hrs) and transferred to following steps: **1. Dehydration:** specimens were passed through ascending grades of ethanol alcohol (70%, 80%, 90%, 100%) for 1 hour in each concentration. **2. Clearing:** two solutions of xylol commonly used for clearing. The specimens rested 1 hour in each step. **3. Impregnation with Paraffin wax, 4. Blocking, 5. Sectioning and 6. Staining with Prussian blue stain** for hemosidrine.

Statistical analysis

Data are shown as the mean \pm stander error (SE). When a significant interaction between major factors was identified by ANOVA. SPSS version 11.5, Duncan's new multiple range test was used post-ANOVA to identify significant differences between mean values at probability level of ($P < 0.05$) taken as significant.

Results

Observations of the experimental animals during the present study revealed that rabbits treated with lead acetate suffered from mild anorexia, easy hair shading especially during handling and dullness. Also these signs were observed in group 3, 4 and 5 especially at the end of the experiment in comparison with the control group. The 90 days duration of the experiment indicates the sub-chronic exposure for experimental animals to lead acetate.

Hematological and Biochemical changes:

The protective role of the oral administration of vitamin E and/or methionine against side effects of lead on the hematological parameters of experimental animals, i.e., levels of RBCs, Hb, PCV%, MCV, MCH, MCHC and reticulocyte % in adult male rabbits for 90 days, were shown in table 1.

Results revealed that Lead exposure led to non-significant reduction of Hb concentration, PCV%, and RBCs ($\times 10^6/\mu\text{l}$) count; significant reductions of MCH, MCV, MCHC in comparison with control

group (69.130 ± 0.85 pg, 21.05 ± 0.25 fl, 30.48 ± 0.27 g/dl; versus 12.05 ± 0.51 pg, 36.61 ± 1.13 fl and 5.02 ± 0.09 g/dl; respectively) ($P < 0.05$); and significant elevation of reticulocyte % ($1.60 \pm 0.25\%$). The same results were observed from rabbits administered methionine against lead.

Administration of vitamin E alone against lead for 90 days has led to non-significant reduction of Hb, PCV and total RBCs (11.06 ± 0.46 g/dl, 34.34 ± 1.6 %, $4.85 \pm 0.25 \times 10^6$ RBCs/ μl ; respectively); significant elevation of MCV, MCH and MCHC (71.11 ± 1.4 pg, 22.90 ± 0.54 fl and 32.25 ± 0.27 g/dl); and significant decrease in reticulocyte % ($3.61 \pm 0.31\%$) in comparison with group administered lead.

On the other hand administration of methionine mixed with vit. E against Lead had succeeded to return back Hb, PCV, RBCs, MCHC, and reticulocyte % to the semi normal values, (12.16 ± 0.50 g/dl, $37.71 \pm 1.75\%$, $5.54 \pm 0.27 \times 10^6$ RBCs/ μl , 32.30 ± 0.36 g/dl, 3.45 ± 0.25 %; respectively (Table 1).

Table 1. Lead Induced Changes on Hb, PCV, RBC Count and Indices and Reticulocytes Count

Parameter	Rabbit Groups				
	G1 (N = 6)	G2 (N = 6)	G3 (N = 6)	G4 (N = 6)	G5 (N = 6)
Hb (g/dl)	12.050±0.517 ^a	11.017±0.485 ^a	11.450±0.287 ^a	11.067±0.467 ^a	12.167±0.508 ^a
PCV (%)	36.617±1.138 ^a	36.167±1.427 ^a	36.833±0.610 ^a	34.433±1.631 ^a	37.717±1.751 ^a
RBCs ($\times 10^6/\mu\text{l}$)	5.025±0.099 ^{ab}	5.252±0.251 ^{ab}	5.350±0.127 ^{ab}	4.850±0.250 ^b	5.548±0.270 ^a
MCV (fl)	72.850±1.058 ^a	69.133±0.852 ^b	69.767±0.426 ^b	71.117±1.455 ^{ab}	68.083±0.812 ^b
MCH (pg)	23.967±0.775 ^a	21.050±0.275 ^c	21.550±0.148 ^{bc}	22.900±0.542 ^{ab}	22.000±0.284 ^{bc}
MCHC (g/dl)	32.867±0.656 ^a	30.483±0.387 ^b	30.833±0.275 ^b	32.250±0.279 ^a	32.300±0.361 ^a
Reticulocytes (%)	1.602±0.252 ^d	7.793±0.351 ^a	5.337±0.292 ^b	3.617±0.315 ^c	3.458±0.250 ^c

Different small letters horizontally denotes significant Differences between groups at $P < 0.05$

Table 2 illustrated analysis of the data obtained from the present study, showing the non significant changes of total WBC count between different groups. On the other hand, after administration of lead there was a significant elevation of Neutrophils which correlated with a significant reduction of Lymphocytes ($P < 0.05$). These abnormal changes were corrected in groups treated with Vit. E and/or methionine. After 90 days of lead administration, serum iron

increased significantly in the four studied groups (G2, G3, G4 and G5): (299.45 ± 6.56 , 211.5 ± 7.36 , 226.90 ± 10.66 and 270 ± 8.69 $\mu\text{g/dl}$; respectively) in comparison with control group (193.25 ± 6.56 $\mu\text{g/dl}$). Marginal reduction of Ferritin concentration after lead administration was observed in group 1 (0.15 ± 0.03 $\mu\text{g/dl}$) in comparison with control (2.200 ± 0.15 $\mu\text{g/dl}$); however, this reduction was corrected by the

administration of vit.E and/or methionine as shown in the other groups (Table 3).

Table 2. Lead-Induced Change on WBC, Lymphocyte, neutrophil, and Platelets and control group

Groups	WBC ($\times 10^3/\mu\text{l}$)	Lymphocyte ($\times 10^3/\mu\text{l}$)	Neutrophil ($\times 10^3/\mu\text{l}$)	Platelets ($\times 10^3/\mu\text{l}$)
G1	6.550 \pm 0.161 ^a	3.500 \pm 0.141 ^a	1.833 \pm 0.276 ^a	188.667 \pm 1.745 ^b
G2	6.083 \pm 0.156 ^a	2.417 \pm 0.098 ^b	1.867 \pm 0.161 ^a	225.333 \pm 12.478 ^a
G3	6.467 \pm 0.338 ^a	3.833 \pm 0.343 ^a	1.367 \pm 0.042 ^{ab}	190.833 \pm 4.045 ^b
G4	6.383 \pm 0.421 ^a	4.100 \pm 0.545 ^a	1.117 \pm 0.172 ^b	202.000 \pm 10.132 ^b
G5	6.367 \pm 0.288 ^a	3.800 \pm 0.363 ^a	1.133 \pm 0.126 ^b	181.833 \pm 5.558 ^b

Different small letters horizontally denotes significant Differences between groups at P < 0.05

Table 3. Lead Induced Changes on Iron and Ferritin and in the control group

Groups	Iron ($\mu\text{g}/\text{dl}$)	Ferritin ($\mu\text{g}/\text{dl}$)
G1	193.250 \pm 6.564 ^b	2.200 \pm 0.157 ^a
G2	299.450 \pm 15.178 ^a	0.150 \pm 0.034 ^c
G3	211.050 \pm 7.362 ^{ab}	1.367 \pm 0.076 ^b
G4	226.900 \pm 10.662 ^{ab}	1.567 \pm 0.143 ^b
G5	270.333 \pm 8.693 ^a	1.667 \pm 0.115 ^b

Different small letters horizontally denotes significant Differences between groups at P < 0.05

Histopathological changes:

Examination of liver histopathological sections from rabbits received lead revealed a heavy deposition of iron blue-stained hemosidrine in periportal hepatocellular kupffer cells and portal tracts macrophages; while iron deposition was clear in the middle and periportal zone (Figure 1), when compare this picture with liver section of control rabbits (Figure 2).

This heavy deposition of iron was reduced into mild one in pan lobular hepatocyte, kupffer cells and portal tract macrophages in rabbits administering vit.E and/or methionine along with lead after 90 days of the experiment (Figures 3, 4 and 5).

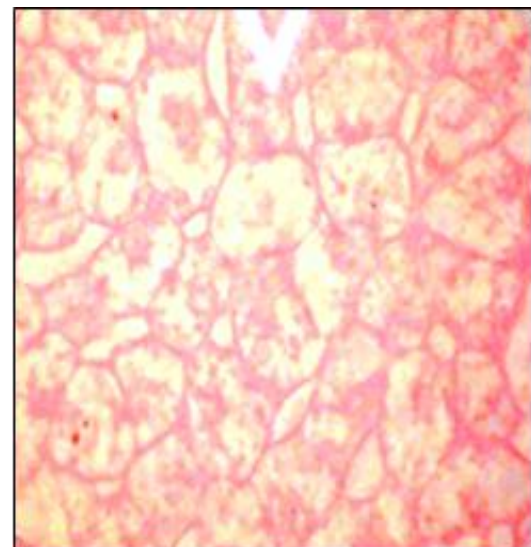


Fig. 1. Liver section form control rabbits, stained with Prussian blue showing no iron deposition (400 \times).

Discussion

In the present study, the role of vitamin E and/or methionine on hematological changes in lead-administered male rabbits for 90 days was investigated. The dose and the sub-chronic exposure of adult male rabbits to lead acetate were designed to produce cumulative effects on hematological system. The main findings of the present study regarding the changes in RBCs

count, Hb concentration and Erythrocytes indices are showed in table 1.

The results referred to the type of anemia induced by lead, the most common form was microcytic-hypochromic. The significant reduction of MCH and MCHC caused by lead for

90 days might be due to reduced Hb production. Lead inhibits ferrochelatase, the enzyme that catalyzes the incorporation of iron into the porphyrin ring leading to reduced iron incorporation in Hb^(10,17), and might result in reduced oxygen transfer by RBCs. This was compensated for by increased number of these cells with smaller volume⁽¹⁸⁾, and was confirmed by the significant reduction of MCH and MCHC. This is in agreement with observations in this study regarding RBC and reticulocyte count and MCV, suggesting that bone marrow could overcome lead toxicity because of sub-chronic exposure which was not at high dose, but suppressed the production of Hb⁽¹⁹⁾ unless it would indicate impaired marrow function or lack of erythropoietin stimulus^(20,21).

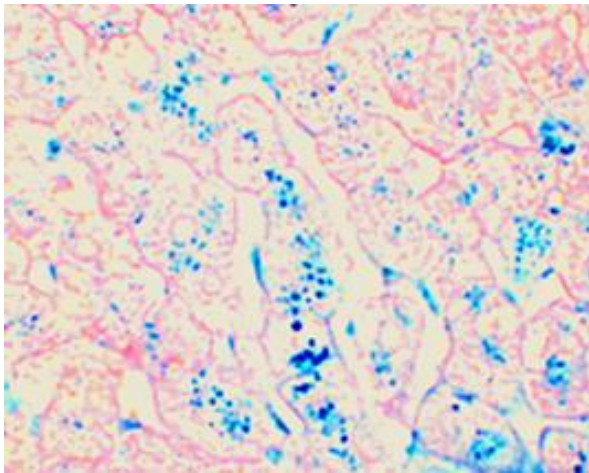


Fig. 2. Liver section from rabbits administered lead was stained with Prussian blue, showing heavy deposition of iron in periportal hepatocellular, kupffer cells and portal tracts macrophages in middle and periportal zone (400×)

On the other hand, results of this study demonstrated that vitamin E and methionine played an important role in improvement of Hb biosynthesis, RBCs production, which was confirmed by the significant elevation of total RBCs count, Hb, and MCHC. This protective mechanism of vitamin E and methionine against lead adverse effects could be explained by the direct effect of vitamin E on improving the morphology of RBCs by its ability to stabilize

their membrane⁽²²⁾, and the free radical scavenger activities of methionine residues as powerful sulfur-containing endogenous antioxidant V⁽¹⁷⁾. In addition, methionine is a very important nutrient during the Hb biosynthesis and RBC production in bone marrow.

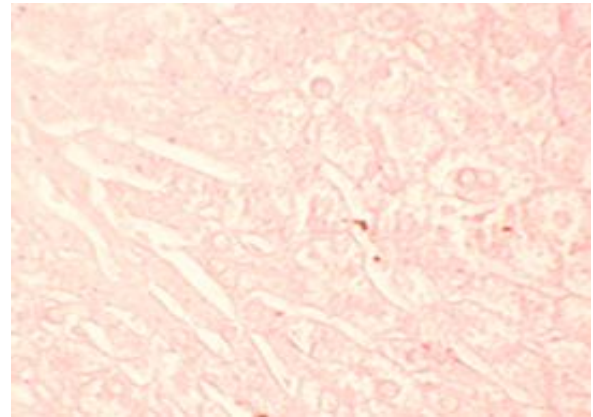


Fig. 3. Liver section from rabbits received lead+methionine stained with Prussian blue, showing a heavy deposition of iron in periportal hepatocellular, kupffer cells and portal tracts macrophages (400×).

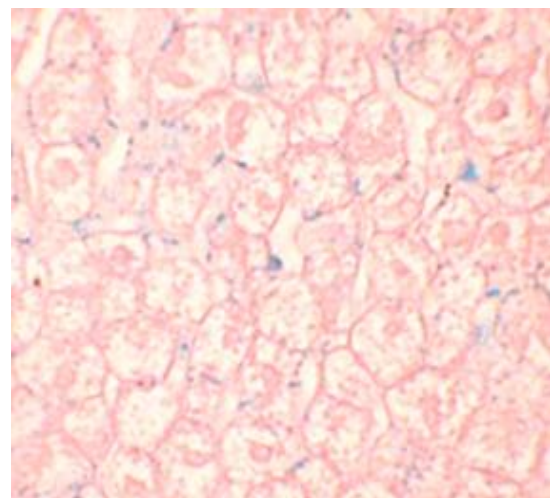


Fig. 4. Liver section from rabbits received lead+vit.E stained with Prussian blue, showing mild panlobular hepatocyte and kupffer cell iron deposition, iron present in portal tract macrophage (400×).

The increased platelet count found in the present study (Table 2), refer to other

hematological disturbances induced by lead administration, which could be attributed to either hyper stimulation of thrombopoiesis in the bone marrow as a response to peripheral loss of platelets caused by increased platelet aggregation and adhesion^(4,10), or as response to decreased Hb concentration caused by lead acetate administration. This result is in agreement with the results of other researchers who found that accelerated platelet aggregation when there is lowered Hb concentration⁽²³⁾. On the other hand, results of the present study reflected the protective role of methionine and vitamin E against changes induced by lead administration. There were no changes in platelet count in rabbits received vit.E and methionine (Table 2). This protective effect could be explained by the direct action of vit.E and methionine on reducing the aggregation and adhesion of platelets in peripheral blood vessels, keeping normal blood level of thrombocytes in rabbits. Further, Vit.E supplementation also proved to be effective in significantly decreasing the already raised values of platelets⁽²⁴⁾.

Although results in table 2 indicated a significant decrease in lymphocyte count, which was correlated with a significant increase in neutrophil count; however, the mean total WBC count was relatively unchanged. Despite that, not all researchers agree on the effects of lead on total and differential WBCs^(18,25). The damaging effects of the reactive oxygen species on living systems as a result of lead intoxication required more phagocytic functions faced by increase of neutrophils. These damaging effects were prevented by the protective action of vitamin E, thus, neutrophil count returned back to semi normal values in rabbits administered vit. E alone or mixed with methionine reflecting either the antioxidant property and/or the protective role of vit. E on bone marrow^(12,22,24,25).

After 90 days of the experiment, results revealed a significant increase in serum iron faced by the significant decrease in serum ferritin in rabbits administering lead acetate as compared with the control and other groups (table-3). Lead inhibits

ferrochelatase enzyme that catalyzes the incorporation of iron into the porphyrin ring causing reduced iron incorporation in Hb and elevation of serum iron^(10,27). Moreover, competition between lead and iron, since lead is similar to some other ions, enables lead to take the place of iron in heme molecule of Hb, leading to increased serum iron⁽²⁸⁾. The decreased serum ferritin may be due to the accumulation of the ferritin in the form of the hemosiderin, resulting in hemosiderosis and hemochromatosis, both of which are associated with excessive levels of serum iron and % saturation of the transferrin with iron and decreased serum ferritin levels⁽²⁹⁾. The hemosiderosis observed in the liver of rats administering lead acetate (Figure 2) may be due to increased serum iron released from the heme liberated from the premature hemolysed RBCs. This excess iron cannot be utilized for Hb synthesis, because of the toxic effects of lead. Increased intracellular iron, increased ferritin expression, deposited as hemosiderin in liver^(5,20,30). The severity of these findings were decreased in groups administered vit. E alone or mixed with methionine (Figures 3, 4 and 5), reflecting again the protective role of vit. E against lead toxic effects. These finding could be explained that prevention of the preliminary RBCs elimination decreases phagocytosis and consequently decreases iron deposition, as well as the antioxidant effect of vit. E in reducing liver parenchymal damage and ferritin release to the circulation. L-methionine produces an increase in ferritin protein expression, thus activation of endogenous iron sequestration could be an important mechanism by which methionine increases the cellular defense against oxidative injury^(11,17).

In conclusion, decreased MCV, MCH, and MCHC and reticulocytosis demonstrate regenerative anemia in rabbits administering lead acetate; since reticulocytes are still synthesizing Hb and bone marrow tries to compensate these changes by an increase in the reticulocytes release while lead causes increased iron in circulation and intra cellular deposition, vit. E alone or mixed

with methionine, prevent the occurrence of these changes. Results of this study, also, provide direct evidence that combined treatment of Pb-exposed animals with vit.E, whether alone or mixed with methionine has a protective role represented by the significant improvement of MCV, MCH and MCHC; with reticulocyte production within normal values.

References

- Gambrell J. Lead poisoning outbreak causes emergency In Nigeria. Huffpost Social News. The Internet Newspaper—Personalized New York, NY. huffingtonpost.com. 2011 Febr, 22.
- Birgit P, Poppenga RH. Lead and zinc intoxication in companion birds. Compendiumvet.com. 2009 Jan; 31(1): E1-E12.
- Al-Bassam A. Survey of lead pollution In Baghdad: Water, air and soil pollution, 1983; 19(1): 3-14.
- Mugahi MN, Heidari Z, Sagheb AHM, et al. effects of chronic lead acetate intoxication on blood indices of male adult rat. DARU. 2003; 11(4): 147-51.
- Klaassen CD. Casarett and Doulls Toxicology, the basic science of poisons. 7th ed. New York: Mcgraw-Hill Medical Publishing Division; 2008. p. 137-138, 146-150, 464, 944-945, 1158,
- Çaylak E, Haldfeoglu D, Aydin S, et al. The effects of sulfur-containing compounds on total antioxidant capacity levels of liver, kidney and brain in lead-exposed rats. *Turkiye Klinikleri J Med Sci.* 2007; 27: 823-8.
- Moussa SA, Bashandy SA. Biophysical and biochemical changes in the blood of rats exposed to lead toxicity. *Romani J Biophys.* 2008; 18(2): 123-33.
- Kosnett MJ. Lead. In: Ford MD, Delaney KA, Ling LJ, et al. (eds.) *Clinical toxicology.* 1st ed. Philadelphia: W. B. Saunders Company; 2007. Chapter 89.
- Hassan NS, Awad SM. Reverse effect of vitamin e on oxidative stress, derivatives and conductivity changes of hemoglobin induced by exposure to cadmium. *J Appl Sci Res.* 2007; 3(6): 437-43.
- Casas JS, Sordo J. Lead chemistry, analytical aspects, environmental impact and health effects. 1st ed. London: Elsevier BV; 2006. p. 17, 32, 169, 174-80, 185, 200, 214.
- Gaurav D, Preet S, Dua KK. chronic cadmium toxicity in rats: treatment with combined administration of vitamins, amino acids, antioxidants and essential metals. *J Food Drug Anal.* 2010; 18,(6): 464-70.
- Flora SJ, Mittal M, Mehta A. Heavy metal induced oxidative stress and its possible reversal by chelation therapy. *Indian J Med Res.* 2008; 128(4): 501-23.
- Xiang HL, Dadin F, Nabil HL, et al. δ -tocotrienol protects mouse and human hematopoietic progenitors from γ -irradiation through extracellular signal-regulated kinase/mammalian target of rapamycin signaling *Haematologica.* 2010; 95: 3324-32.
- Erdmann K, Grosser N, Schröder Hl. Methionine reduces oxidant stress in endothelial cells: role of heme oxygenase-1, ferritin, and nitric oxide. *AAPS J.* 2005; 7(1): 195-200.
- Carson FL. *Histotechnology.* American Society for Clinical Pathology, Chicago; 1997.
- El-Nekeety AA, El-Kady AA, Soliman MS, et al. Protective effects of *aquilegia vulgaris* (l) against lead acetate – induced oxidative stress in rats. *Food Chem Toxicol.* 2009; 47: 2209-15.
- Ozsoy SY, Ozsoy B, Ozyildiz Z, et al. Protective effect of l-carnitine on experimental lead toxicity in rats: a clinical, histopathological and immunohistochemical study. *Biotech Histochem.* 2011; 86(6): 436-43.
- Patil AJ, Bhagwat VR, Patil JA, et al. Effect of lead (pb) exposure on the activity of superoxide dismutase and catalase in battery manufacturing workers (bmw) of western maharashtra (india) with reference to heme biosynthesis. *Internat J Environ Res Public Health.* 2006; 3(4): 329-37.
- Golalipour MJ, Roshandel D, Roshandel G, et al. Effect of lead intoxication and d-penicillamine treatment on hematological indices in rats. *Int J Morphol.* 2007; 25(4): 717-22.
- Nagaraja H, Tan J, Srikumar C, et al. Protective effects of alpha-polic acid against lead acetate – induced oxidative stress in the bone marrow of rats. *Internat J Pharmacol.* 2011; 7(2): 217-27.
- Hoffbrand AV, Catovsky D, Tuddenham EGD. *Postgraduate haematology.* 5th ed. Massachusetts: Blackwell Publishing Ltd; 2005. p. 27, 34-35, 40.
- Kalia K, Flora SJS. Strategies for safe and effective therapeutic measures for chronic arsenic and lead poisoning. *J Occup Health.* 2005; 47(1): 1-21.
- Scharbert G, Wetzel L, Berlinger L, et al. Effect of anemia on coagulation and platelet function: a whole blood in vitro study. *Crit Care.* 2011; 15(Suppl 1): P445.
- Garg DP, Bansal AK, Malhotra A, et al. Methomyl induced hematological and biochemical alterations – protection by vitamin E. *Pesticide Biochem Physiol.* 2009 Mar; 93(3): 127-32.
- Bravo Y, Quiroz Y, Ferrebuz A, et al. Mycophenolate mofetil administration reduces renal inflammation, oxidative stress, and arterial pressure in rats with lead-

- induced hypertension. *Am J Physiol Renal Physiol.* 2007; 293(2): 616-23.
26. Sajitha GR, Jose R, Andrews A, et al. Garlic oil and vitamin E prevent the adverse effects of lead acetate and ethanol separately as well as in combination in the drinking water of rats. *Indian J Clin Biochem Jul.* 2010; 25(3): 280-8.
27. Harvey JW. The Erythrocyte: Physiology, Metabolism, and Biochemical Disorders. Chapter Seventh. In: Kaneko JJ, Harvey JW, Bruss ML (eds.): *Clinical biochemistry of domestic animals.* 5th ed. Academic Press; 1997. p. 157-233.
28. Blake S. *Vitamins and minerals demystified.* New York: McGraw-Hill Companies, Inc.; 2008. p. 111-121, 275.
29. Arneson W, Brickell J. *Clinical Chemistry: A laboratory perspective.* Philadelphia: FA Davis Company; 2007. p. 183-8.
30. Nordberg GF, Fowler BA, Nordberg M, et al. *The Handbook on the toxicology of metals.* 3rd ed. Copenhagen: Academic Press, Inc.; 2005. p.119, 269, 600-43.

Corresponded to Majida AJ Alqayim

E-mail: jaafer59@yahoo.com

Received 15th Apr. 2012: Accepted 10th Mar. 2013.