

A Giant Solitary Primary Retroperitoneal Hydatid Cyst in 5-Year Old Child: Case Report.

Ahmed Z. Zain *FICMS*

Dept. of Surgery, College of Medicine, Al-Nahrain University, Baghdad, Iraq

Abstract

Hydatid disease is one of the commonest zoonotic diseases. It is caused by the larval cyst of *Echinococcus granulosus* and result in the most severe form of cestodiasis in man. The hydatid disease is endemic in some Mediterranean countries, the Middle East, the South America, and South Africa and Oceania. The combination of imaging and serology usually enables diagnosis. We report a case of single and giant hydatid cyst in an unusual site (retroperitoneal region) which is very rare and also in a five-year old child which is unlikely to happen at such age with this big size.

Keywords: Hydatid disease, retroperitoneal region.

List of abbreviations: HD = hydatid disease, HC = hydatid cyst, CT = computed tomography, MRI = magnetic resonance imaging study

Introduction

Hydatid disease (HD) is prevalent in most sheep-raising Mediterranean countries. It is often manifested by a slowly growing cystic mass.

In 85%-95% of the cases, the liver and / or lung are involved and only 5%-15% of the cyst occurs in other sites. Retroperitoneal HD is usually the result of spontaneous, traumatic, or surgical rupture of hepatic cyst.

Primary retroperitoneal HD without any other organ involvement is very rare^(1,2).

Retroperitoneal location of hydatid cyst (HC) is encountered rarely and only occasional cases were reported since Lackart and Spinza in 1958⁽³⁾.

HD is seen more frequently at ages 20 to 40 years. Infestation usually occurs in childhood. The HC grow slowly (about 1-3 cm per year) that is to say the organism may take up to 20 years to reach considerable size.

The cyst grows and increases by means of daughter cysts that they produce. The natural course of infection varies; some cysts spontaneously collapse or calcify.

The clinical manifestation is related to compression of the involved organ. Routine blood tests are generally normal but eosinophilia occurs in 25% of the cases. Ultrasound, computed tomography (CT) scan, magnetic resonance imaging study (MRI) and Casoni skin test or complement fixation and hemagglutination inhibition serological test may help in the diagnosis⁽⁴⁾.

Total cystectomy is the best technique to get rid of the parasite, but when the cyst can't be removed completely, partial cystectomy is recommended.

Laprosopic approach also described and encouraging results have been achieved in some series. Spillage of the cysts must be avoided and scolicidal agents must be used (such as hydrogen peroxide and 10% povidone-iodone).

Zain AZ, Solitary Primary Hydatid Cyst

Medical treatment with albendazole or praziquantel is indicated for inoperable or disseminated cases. Percutaneous aspiration, injection and re-aspiration (PIAR technique) is also another non-surgical option^(5,6).

Case report

A five-year old girl was admitted to Al-Imamian Al-Kadhymian Medical City with a swelling in the right hypochondrium which grew very rapidly. Abdominal examination revealed a big mass of 15 cm in diameter in right hypochondriac region; the mass was immobile and not tender.

Her vital signs were within normal limits. Laboratory findings included: hemoglobin 10.5 gm/dl, white blood cell count 10.000/mm³, blood urea = 15 mg/dl and serum creatinine = 0.8 mg/dl. Other biochemical results were within normal limits.

Chest x-ray revealed no pathological signs and abdominal plain x-ray showed increased soft tissue density in right hypochondriac region. Intravenous urography has shown that both kidneys were functioning normally.

Abdominal ultrasound and CT scan showed a 11 cm x 16 cm retroperitoneal HC causing a downward displacement of right kidney as illustrated in fig. 1.

The patient was started to take 15 mg/kg/day albendazole for 2 weeks before doing surgery.

Surgical procedures included abdominal exploration through right upper transverse incision to explore the retroperitoneal cyst⁽⁵⁾.

The cyst was identified grossly as HC and was subjected to aspiration of its fluid contents, whereby 10cc of the fluid was aspirated using a 10 ml syringe with a 22 gauge needle. The fluid was found to be clear and did not contain pus or bile colored.

A scolicidal agent (10% povidone iodine) was injected in a volume of 15 ml^(5,6). The germinative membrane and cystic contents were evacuated through a cystotomy and partial cystectomy was done as illustrated in fig. 2 A and B. Two tube drains were inserted one in

cystic cavity which was removed at the third day postoperatively and the other one within the pelvic cavity which was removed at seventh day post operatively.

The child was kept on albendazole treatment in dose of 15 mg/kg/day in two divided doses for three months with monitoring of liver function^(5,6).

The cyst contents were sent for histopathology which proved the diagnosis with presence of laminated membrane and germinal membrane in the examined section.

Discussion

Primary retroperitoneal HC is extremely rare even in endemic areas. The majority of abdominal and pelvic HC are considered to be secondary to prior hepatic involvement following spontaneous rupture or surgical inoculation⁽⁶⁾.

HC in children is rare because the cyst needs several years to reach considerable size (1-3 cm/year), This patient was five-year old and had a large primary HC (11 cm x 16 cm) in an unusual site (retroperitoneal region).

Angulo *et al*⁽⁷⁾ reviewed cases of this condition in endemic areas of central Spain and estimated that 1.1% of newly diagnosed cases were isolated retroperitoneal cysts.

Turkyilmaz *et al*⁽⁸⁾ reported a case of nine year old female child with primary retroperitoneal HC of 8cm in diameter in turkey.

Hydatid disease in extrahepatic locations usually remains asymptomatic unless the cyst grows and produces pressure symptoms, rupture to pleural or peritoneal cavity, secondary infection, or an allergic reaction, this patient presented with abdominal distension, which was increasing over the last few months.

In conclusion, Hydatid disease should be kept in mind in the differential diagnosis of retroperitoneal masses in patient living in endemic areas; also we should expect HC even in large size and in unusual site in pediatric age group.

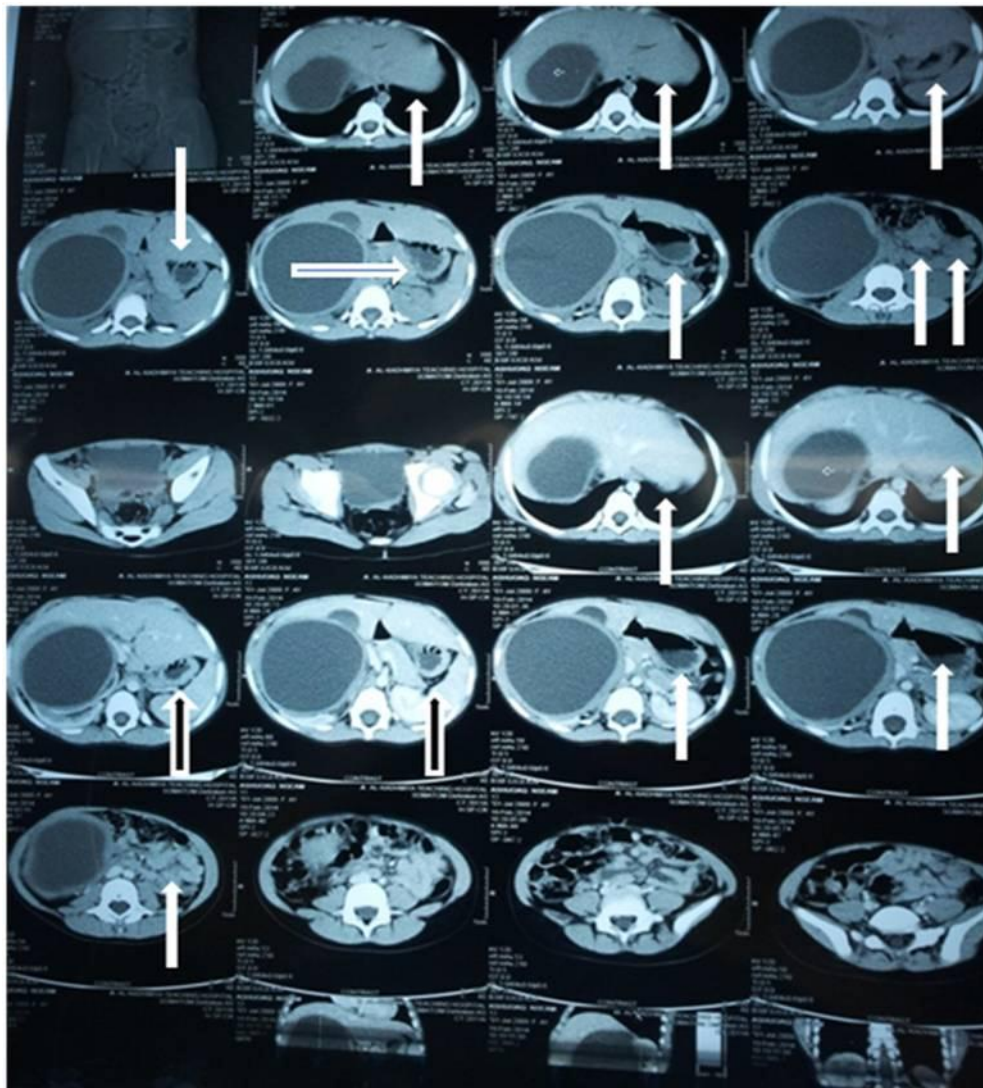


Fig. 1. CT-scan of abdomen showing a big retroperitoneal Hydatid cyst (arrows showing a huge Hydatid cyst)

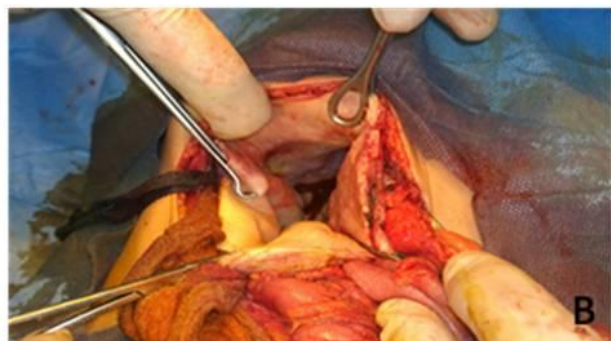
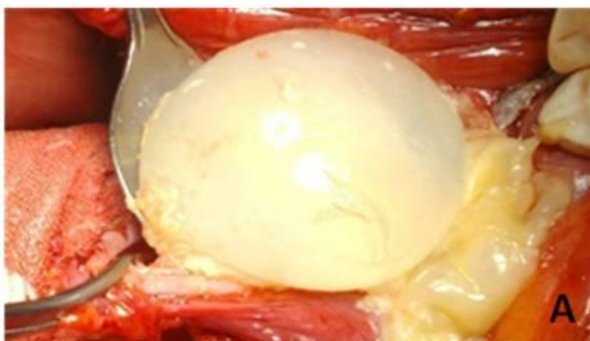
Fig. 2. Intraoperative retroperitoneal Hydatid cyst (Exploration of the cyst); A: Gross appearance of a whitish cyst measuring 11cmx 16 cm, B: cystotomy and partial cystectomy.

Acknowledgments

I would like to thank the anesthetist and medical staff in the pediatric surgical center at Al-Imamain Al-Kadhymain Medical City for their help and support in this case report.

References

1. Tepet K, Christodolidis G, Spryidatis M, et al. Large solitary retroperitoneal echinococcal cyst: A rare case report. *World J Gastroint tract.* 2007; 13: 6101-2.
2. Tekin R, Kara AF, Tekin RC, et al. Cardiac Hydatid cyst case recovered with medical treatment. *Andolu Kardiyol Derg.* 2011; 11: 650-1.
3. Lokhart J, Supinza VC. Primary retroperitoneal localization of Hydatid disease. *J Am Coll Surg.* 1958; 12: 968-70.
4. Sozuer EM, Arsdan M. The perforation problem in Hydatid disease. *Am J Trop Med Hyg.* 2002; 66: 575-7.
5. Kiyak G, Ozer M, Akitimur R, et al. Primary Hydatid disease of the soft tissue. *Internet J Surg.* 2005; 8(2).
6. Uysal S, Tunçbilek I, Gokharma D, et al. Female genitelea hydatidosis herniating to inguinal canal. *Abdomen Imag.* 2005; 30: 623-5.
7. Angulo JC, Escribano J, Diego A, et al. Isolated retroperitoneal and retrovesical hydatidosis: clinical study of 10 cases and literature review. *J Urol.* 1998; 159: 76-82.
8. Turylymaz Z, Zomez K, Karabulut R, et al. Unusal localization of Hydatid cyst. *Turkey Acta Chir Belg.* 2006; 106: 443-4.

E-mail: ahmedzbar@yahoo.com

Mobile: + 964 7905234569

Received 1st Apr. 2014: Accepted 27th May. 2014